



ACTAS Derma-Sifiliográficas

Full English text available at
www.actasdermo.org



ORIGINAL ARTICLE

Notalgia Paresthetica: Treatment Using Intradermal Botulinum Toxin A[☆]



L. Pérez-Pérez,^{a,b,*} J. García-Gavín,^{a,b} F. Allegue,^a J.L. Caeiro,^a
J.M. Fabeiro,^a A. Zulaica^a

^a Servicio de Dermatología, Complejo Hospitalario Universitario de Vigo, Vigo, Spain

^b Clínica Pérez & Gavín dermatólogos, Vigo, Spain

Received 22 April 2013; accepted 17 September 2013

Available online 27 December 2013

KEYWORDS

Notalgia
paresthetica;
Botulinum toxin;
Pruritus;
Treatment

PALABRAS CLAVE

Notalgia parestésica;
Toxina botulínica;
Prurito;
Tratamiento

Abstract

Introduction: Notalgia paresthetica is a sensory mononeuropathy that affects dorsal segments T2 to T6. It can have a significant effect on quality of life. Numerous treatments have been used with variable results.

Material and methods: Five patients diagnosed with notalgia paresthetica were treated with intradermal botulinum toxin A. None had achieved relief of the pruritus with previous treatments.

Results: Variable results were observed after the administration of intradermal botulinum toxin. Complete resolution of the pruritus was not achieved in any of the patients.

Conclusions: Botulinum toxin A appears to be a safe therapeutic option for patients with notalgia paresthetica. However, data currently available come from small patient series, making it difficult to draw definitive conclusions regarding the true efficacy and long-term effects of this treatment.

© 2013 Elsevier España, S.L. and AEDV. All rights reserved.

Tratamiento de la notalgia parestésica con toxina botulínica A intradérmica

Resumen

Introducción: La notalgia parestésica es una mononeuropatía sensitiva que afecta a los segmentos dorsales T2 a T6 y puede alterar significativamente la calidad de vida de los pacientes. Para su tratamiento se han empleado diversas alternativas con resultados muy variables.

Materiales y métodos: Se trataron 5 pacientes diagnosticados de notalgia parestésica con toxina botulínica A intradérmica. Ninguno de los tratamientos que todos ellos habían recibido previamente había logrado controlar su prurito.

[☆] Please cite this article as: Pérez-Pérez L, García-Gavín J, Allegue F, Caeiro J, Fabeiro J, Zulaica A. Tratamiento de la notalgia parestésica con toxina botulínica A intradérmica. Actas Dermosifiliogr. 2014;105:74–77.

* Corresponding author.

E-mail address: lperez@pgdermatologos.com (L. Pérez-Pérez).

Resultados: Los resultados observados tras la administración de toxina botulínica intradérmica fueron variables. En ninguno de los pacientes tratados se consiguió la resolución completa del prurito.

Conclusiones: La toxina botulínica tipo A parece ser una alternativa terapéutica segura para los pacientes con notalgia parestésica. Sin embargo, los datos disponibles hasta la fecha proceden de series de pacientes pequeñas, lo que dificulta la extracción de conclusiones definitivas acerca de la eficacia real y los efectos a largo plazo de este tratamiento.

© 2013 Elsevier España, S.L. y AEDV. Todos los derechos reservados.

Introduction

Notalgia paresthetica (NP) is considered a sensory mononeuropathy of unknown origin that presents with localized pruritus in dorsal segments T2 to T6.^{1,2} Other symptoms include pain, paresthesia, hypo- and/or hyperesthesia, and burning. NP is frequently associated with a brownish patch in the affected area.

Nerve impingement is thought to be the chief cause, although other factors have been suggested as potential causes or triggers.²⁻⁵

Various topical and systemic treatments⁶⁻¹⁴ have been found to achieve partial or complete remission of symptoms for variable periods of time, but long-term results are discouraging in most cases. In 2007, Weinfeld reported a satisfactory response to botulinum toxin (BTX) in 2 patients with NP.¹⁵ Subsequently, Wallengren and Bartosik¹⁶ reported variable improvement of pruritus in 4 patients with NP.

Five patients with NP diagnosed in our department were treated with intradermal BTX. We describe our observations 1, 6, 12, and 18 months after treatment. This is the longest follow-up period reported to date.

Material and Methods

We included 5 consecutive patients (4 women, aged 49–55 years; 1 man, age 52 years) diagnosed with NP and monitored in our department since 2009. All patients had a highly pruriginous hyperpigmented patch on their backs (Fig. 1) and reported significant interference with daily life. Patient 2 also experienced pain in the affected area. All patients had previously received other topical and systemic treatments with no improvement (Table 1).

Patients were treated with intradermal injections of BTX type A (BTX-A), specifically onabotulinumtoxinA (Botox, Allergan S.A.U, Madrid, Spain), according to the method described by Weinfeld.¹⁵ The treatment area was first marked on the basis of clinical appearance, and the injection points were set 2 cm apart (Fig. 1, B and C). Prior to injection, a eutectic mixture of lidocaine and prilocaine (EMLA cream, AstraZeneca Farmacéutica España S.A., Madrid, Spain) was placed on the area and left under occlusion for 1.5 hours. Every vial of BTX-A was reconstituted with 2.5 mL of normal saline (0.9%) and an insulin syringe was then used to inject 4 units (0.1 mL) at each injection point. The size of the affected area determined the total dose received by each patient (Table 1).

Severity of itching was assessed on a visual scale numbered from 0 to 10, at baseline and 1, 6, 12, and 18 months following treatment.

Results

Outcomes varied widely, as shown by the changes in pruritus (Fig. 2). No changes in size or color of the hyperpigmented patch were observed in any of the patients.

No immediate or delayed adverse effects were recorded. Treatment was well tolerated by all patients. Pain experienced during the procedure was scored between 1 and 2 on a visual scale of 0 to 10.

Discussion

BTX-A is a neurotoxin that inhibits the release of substance P, norepinephrine, and glutamate; stimulates the release of calcitonin gene-related peptide; and attenuates histamine-induced pruritus.^{15,16}

Weinfeld¹⁵ proposed BTX-A as an effective treatment for NP after using it successfully on 2 patients. The author reported complete resolution of pruritus in 1 patient for at least 18 months following a single treatment, and complete resolution in the other patient within a week of her second treatment.

We attempted to replicate these results in a larger number of patients, although we restricted treatment to a single course of BTX-A per patient. Our results were markedly different from Weinfeld's. First, pruritus failed to disappear completely in any of our patients. Shortly after treatment, 3 of our 5 patients reported improvement, but this response never lasted longer than 1 month. Interestingly, the other 2 patients even experienced worsening pruritus. Wallengren and Bartosik¹⁷ used BTX to treat 4 patients with NP, 1 patient with meralgia paresthetica, and 1 patient with neuropathic pruritus on the dorsum of the foot. BTX was administered in amounts ranging from 0.8 to 1.5 IU at injection points spaced 1.5 cm apart. The outcomes they observed also varied widely, consistent with our observations, although their patients were only followed for 6 weeks. One of their NP patients reported being completely itch-free 6 weeks after treatment, but the others experienced improvement for 1 to 10 days following treatment and itching worsened again after that period. Despite these variable outcomes and the fact that most treated patients failed to achieve complete remission of itching, the authors of this study judged BTX a useful alternative for treating this condition.

Our study clearly has limitations. We only quantified a single subjective symptom (pruritus) based on the patient's own assessment on a pain scale. We did not evaluate the potential influence of factors other than the drug itself (for instance, mechanical stimulation, tissue distention, or even

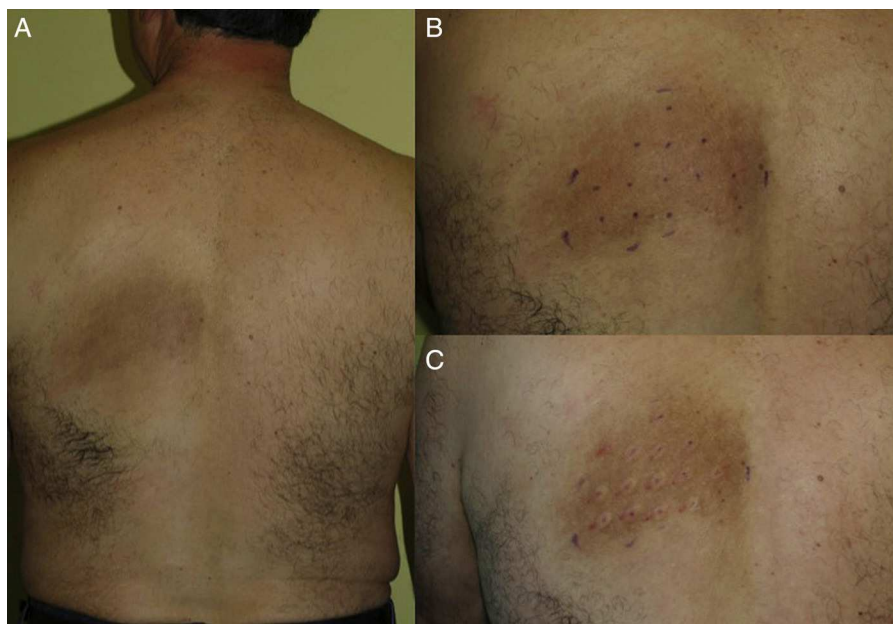

Figure 1 Case 1. A, Prior to treatment. B, Injection point marks. C, Immediately after treatment. Visible edema at injection sites.

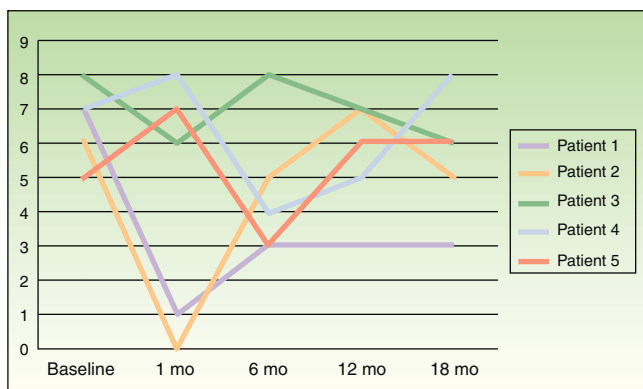


Figure 2 Changes in pruritus, assessed on a scale of 0-10, at baseline and 1 month, 6 months, 12 months, and 18 months after treatment.

a placebo effect), and we had no control group for comparison.

NP is typically a chronic condition with a variable course that may include periods of seemingly spontaneous improvement; mid- to long-term response to treatment is therefore difficult to assess.

Our findings as well as those of Wallengren and Barstik¹⁷ suggest that BTX is of doubtful use in treating NP. Our long follow-up period enabled us to note that response to treatment varies from patient to patient as well as over time. Nevertheless, we view BTX as a potentially useful and safe treatment for patients with NP who have failed to improve with other forms of therapy. A good initial response to BTX could be used to select patients who might potentially benefit from regular treatment.

Currently we have no evidence to suggest that BTX is more effective than other options for treating NP. In order

Table 1 Clinical Features, Prior Treatments, and Amounts of BTX Administered in Each Case.

Case No.	Sex	Age, y	Site	Prior Treatments	Botulinum Toxin, IU
1	M	52	Left scapular area	Topical corticosteroids, oral antihistamines	56
2	F	50	Interscapular area	Topical corticosteroids, pregabalin, oxcarbazepine, TENS	48
3	F	55	Interscapular and right scapular area	Topical corticosteroids, capsaicin, NB-UV-B, oxcarbazepine, physical therapy	50
4	F	49	Left scapular area	Topical corticosteroids	50
5	F	52	Right subscapular area	Topical corticosteroids, oral antihistamines	50

Abbreviations: F, female; M, male; NB-UV-B, narrowband ultraviolet-B phototherapy; TENS, transcutaneous electrical nerve stimulation.

to clearly establish the benefits of this treatment and to define a treatment protocol for this subset of patients, further research is needed, including randomized placebo-controlled trials such as one currently under way,¹⁸ as well as larger-scale trials comparing its effectiveness to that of other treatments.

Ethical Disclosures

Protection of human and animal subjects. The authors declare that no experiments were performed on humans or animals for this investigation.

Confidentiality of data. The authors declare that they have followed their health care centers' protocols on the publication of data concerning patients and that all patients included in the study have received sufficient information and have given their written informed consent to participate in the study.

Right to privacy and informed consent. The authors declare that no private patient data are disclosed in this article.

Conflicts of Interest

The authors declare that they have no conflicts of interest.

References

- Massey EW. Sensory mononeuropathies. *Semin Neurol*. 1998;18:177–83.
- Raison-Peyron N, Meunier L, Acevedo M, Meynadier J. Notalgia paresthetica: Clinical, physiopathological and therapeutic aspects. A study of 12 cases. *J Eur Acad Dermatol Venereol*. 1999;12:215–21.
- Savk O, Savk E. Investigation of spinal pathology in notalgia paresthetica. *J Am Acad Dermatol*. 2005;52:1085–7.
- Alai NN, Skinner HB, Nabili ST, Jeffes E, Shahrokni S, Saemi AM. Notalgia paresthetica associated with cervical spinal stenosis and cervicothoracic disk disease at C4 through C7. *Cutis*. 2010;85:77–81.
- Savk E, Savk O, Bolukbasi O, Culhaci N, Dikiciođlu E, Karaman G, et al. Notalgia paresthetica: A study on pathogenesis. *Int J Dermatol*. 2000;39:754–9.
- Wallengren J, Klinker M. Successful treatment of notalgia paresthetica with topical capsaicin: Vehicle-controlled, double-blind, crossover study. *J Am Acad Dermatol*. 1995;32:287–9.
- Savk E, Bolukbasi O, Akyol A, Karaman G. Open pilot study on oxcarbazepine for the treatment of notalgia paresthetica. *J Am Acad Dermatol*. 2001;45:630–2.
- Loosemore MP, Bordeaux JS, Bernhard JD. Gabapentin treatment for notalgia paresthetica, a common isolated peripheral sensory neuropathy. *J Eur Acad Dermatol Venereol*. 2007;21:1440–1.
- Pérez-Pérez L, Allegue F, Fabeiro JM, Caeiro JL, Zulaica A. Notalgia paresthetica successfully treated with narrow-band UVB: Report of five cases. *J Eur Acad Dermatol Venereol*. 2010;24:730–2.
- Wang CK, Gowda A, Barad M, Mackey SC, Carroll IR. Serratus muscle stimulation effectively treats notalgia paresthetica caused by long thoracic nerve dysfunction: A case series. *J Brachial Plex Peripher Nerve Inj*. 2009;4:17.
- Williams EH, Rosson GD, Elsamanoudi I, Dellon AL. Surgical decompression for notalgia paresthetica: A case report. *Microsurgery*. 2010;30:70–2.
- Richardson BS, Way BV, Speece 3rd AJ. Osteopathic manipulative treatment in the management of notalgia paresthetica. *J Am Osteopath Assoc*. 2009;109:605–8.
- Fleischer AB, Meade TJ, Fleischer AB. Notalgia paresthetica: Successful treatment with exercises. *Acta Derm Venereol*. 2011;91:356–7.
- Pérez-Pérez LC. General features and treatment of notalgia paresthetica. *Skinmed*. 2011;9:353–8.
- Weinfeld PK. Successful treatment of notalgia paresthetica with botulinum toxin type A. *Arch Dermatol*. 2007;143:980–2.
- Gazerani P, Pedersen NS, Drewes AM, Arendt-Nielsen L. Botulinum toxin type A reduces histamine-induced itch and vasomotor responses in human skin. *Br J Dermatol*. 2009;161:737–45.
- Wallengren J, Bartosik J. Botulinum toxin type A for neuropathic itch. *Br J Dermatol*. 2010;163:424–6.
- Treatment of notalgia paresthetica with xeomin. <http://clinicaltrials.gov/ct2/show/record/NCT01098019> (accessed March 29, 2013).