

Full English text available at  
www.actasdermo.org

## PRACTICAL DERMATOLOGY

# Hydroxychloroquine: An Essential Drug in Dermatology and Its Controversial Use in COVID-19<sup>☆</sup>

D. Morgado-Carrasco,<sup>a,\*</sup> J. Ibaceta-Ayala,<sup>b</sup> J. Piquero-Casals<sup>c</sup>

<sup>a</sup> Servicio de Dermatología, Hospital Clínic, Universitat de Barcelona, Barcelona, Spain

<sup>b</sup> Integramédica, Redsalud, Santiago, Chile

<sup>c</sup> Dermik, Clínica Dermatológica Multidisciplinar, Barcelona, Spain

Received 18 April 2021; accepted 15 July 2021

### KEYWORDS

Hydroxychloroquine;  
Dermatology;  
Lupus erythematosus;  
Lichen planus;  
COVID-19;  
Supply shortages

**Abstract** Hydroxychloroquine is an antimalarial drug with immunomodulatory, anti-inflammatory, antibacterial, and antiviral properties. It has a good safety profile, can be used in children and in pregnant and breastfeeding women, and does not suppress the immune system. Regular screening for retinopathy, one of the drug's most feared adverse effects, is necessary. Hydroxychloroquine is a widely used, essential drug in dermatology. Clinical response rates are good in lupus erythematosus, where it is a first-line therapy, as well in numerous autoimmune/inflammatory diseases, including lichen planus, polymorphic light eruption, porphyria cutanea tarda, granuloma annulare, and sarcoidosis. In 2020, it was widely prescribed both to prevent and to treat COVID-19 caused by SARS-CoV-2. Its increased use led to serious supply shortages and in some cases stocks were entirely depleted. Recent meta-analyses have concluded that hydroxychloroquine is ineffective against COVID-19 and have advised against its use.

© 2021 Published by Elsevier España, S.L.U. on behalf of AEDV. This is an open access article under the CC BY-NC-ND license (<http://creativecommons.org/licenses/by-nc-nd/4.0/>).

### PALABRAS CLAVE

Hidroxicloroquina;  
Dermatología;  
Lupus eritematoso;  
Liquen plano;  
COVID-19;  
Desabastecimiento

## La hidroxicloroquina como fármaco fundamental en dermatología y su papel controvertido en la COVID-19

**Resumen** La hidroxicloroquina es un antimalárico con acción inmunomoduladora, antiinflamatoria, antibacteriana y antiviral. Posee un buen perfil de seguridad y puede ser utilizada en niños, en mujeres embarazadas o durante la lactancia, y no produce inmunosupresión. La retinopatía es uno de sus efectos adversos más temidos y requiere controles regulares. La hidroxicloroquina es un fármaco esencial en dermatología, utilizado ampliamente con buenas

<sup>☆</sup> Please cite this article as: Morgado-Carrasco D, Ibaceta-Ayala J, Piquero-Casals J. La hidroxicloroquina como fármaco fundamental en dermatología y su papel controvertido en la COVID-19. Actas Dermosifiliogr. 2021. <https://doi.org/10.1016/j.ad.2021.07.005>

\* Corresponding author.

E-mail address: [morgadodaniel8@gmail.com](mailto:morgadodaniel8@gmail.com) (D. Morgado-Carrasco).

tasas de respuesta clínica tanto como un tratamiento de primera línea en el lupus eritematoso, como en múltiples dermatosis autoinmunes/inflamatorias como liquen plano, erupción polimorfa lumínica, porfiria cutánea tarda, granuloma anular y sarcoidosis, entre otras. Durante el año 2020 fue prescrita a gran escala como profilaxis y tratamiento de la infección producida por el coronavirus SARS-CoV-2 (COVID-19). El aumento de la utilización de hidroxicloroquina produjo serias dificultades para su obtención e incluso desabastecimiento. En metaanálisis recientes se ha concluido que la hidroxicloroquina no es efectiva para el tratamiento de esta patología y se desaconseja su prescripción.

© 2021 Publicado por Elsevier España, S.L.U. en nombre de AEDV. Este es un artículo Open Access bajo la licencia CC BY-NC-ND (<http://creativecommons.org/licenses/by-nc-nd/4.0/>).

## Introduction

Hydroxychloroquine is an antimalarial drug derived from chloroquine. It is inexpensive and has a favorable safety profile<sup>1</sup>. Hydroxychloroquine has immunomodulatory, anti-inflammatory, and photoprotective properties, although it can act as a photosensitizer. In dermatology, it is a first-line agent for the treatment of lupus erythematosus and is widely used off-label in multiple autoimmune and inflammatory skin diseases (Fig. 1)<sup>1-3</sup>. Its antibacterial, antifungal, and antiviral properties led it to be prescribed off-label for the prophylaxis and treatment of SARS-CoV-2 infection (COVID-19)<sup>4,5</sup>. The increased use of hydroxychloroquine in this setting led to difficulties obtaining the drug and even temporary depletion of stocks. The present review examines the use of hydroxychloroquine in dermatology, its mechanism of action and toxicities, and the threat that COVID-19 constituted for the supply of the drug.

## Pharmacokinetics and Mechanisms of Action

Hydroxychloroquine has high oral bioavailability, with 45% eliminated via the kidneys<sup>3</sup>. It is metabolized by cytochrome P450, although its plasma levels are not affected by inducers or inhibitors of this enzyme<sup>2</sup> (Table 1).

The mechanism of action of hydroxychloroquine is complex. Its immunomodulatory effect stems from the inhibition of antigen presentation via the major histocompatibility complex, stabilization of lysosomal membranes, reduced cell-mediated cytotoxicity, and inhibition of multiple intracellular toll-like receptors<sup>3</sup>. Its anti-inflammatory effect is secondary to inhibition of phospholipase A2 and C and of various cytokines (tumor necrosis factor  $\alpha$ , interferon  $\alpha$  and  $\gamma$ , and interleukin [IL] 1, 2, and 6)<sup>2</sup>, and its photoprotective effect is secondary to its antioxidant and DNA-stabilizing properties, as well as to reduced levels of interleukins after UV radiation (Table 2)<sup>3</sup>. Hydroxychloroquine also diminishes survival of viruses, bacteria, and fungi in lysosomes and endosomes<sup>3</sup>.

## Approved Indications in Dermatology

Hydroxychloroquine is approved by the United States Food and Drug Administration and the European Medicines Agency for the treatment of lupus erythematosus.

## Adverse Events and Toxicity

Hydroxychloroquine has a favorable safety profile and is rarely discontinued owing to adverse effects. Retinal toxicity, one of the most feared effects, has been observed in 7.5% of patients, although it is extremely rare during the first 5 years of treatment. Doses greater than 5 mg/kg/d for more than 10 years are associated with an increased rate of retinopathy (Table 3)<sup>6</sup>. Gastrointestinal adverse effects are relatively common and include anorexia, heartburn, diarrhea, and abdominal distension<sup>3</sup>. The most common cutaneous adverse effects are rash, hyperpigmentation, and pruritis, as well as photosensitivity. Other, uncommon adverse effects include cardiac, muscular, and hematologic conditions<sup>7</sup> (Table 4).

## Monitoring in Clinical Practice

An ophthalmological examination should be performed at baseline and annually after 5 years of therapy. A recent review did not report hemolysis during therapy with hydroxychloroquine in patients with a deficiency of the enzyme glucose-6-phosphate dehydrogenase; therefore, its routine assessment is not recommended<sup>7</sup>. Table 5 shows the main recommendations.

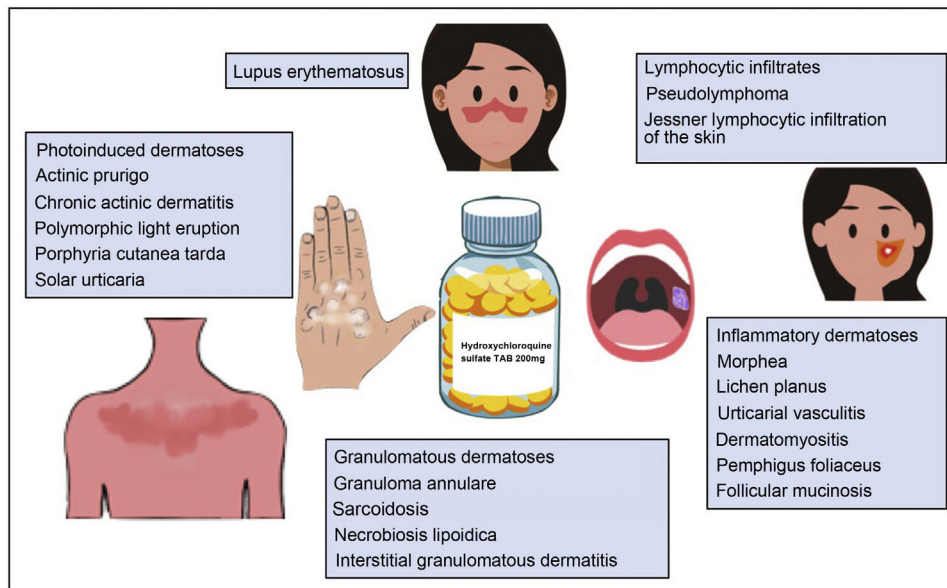
## Hydroxychloroquine in Dermatologic Diseases

### Inflammatory and Autoimmune Skin Diseases

#### Lupus erythematosus

Antimalarial drugs are first-line agents for the treatment of systemic lupus erythematosus (SLE). They reduce joint and skin symptoms, disease activity, target organ damage, and cardiovascular complications and increase survival<sup>8</sup>.

As for cutaneous lupus erythematosus (CLE), a recent systematic review of 10 studies and 852 patients revealed an effectiveness of 50% to 79% (50% in the 2 randomized clinical trials included)<sup>9</sup> (Table 6). The degree of efficacy varied depending on the subtype of CLE and was greater for acute CLE than for subacute CLE and chronic CLE<sup>10</sup>. In the case of tumid lupus erythematosus, a retrospective study (n = 36) revealed satisfactory responses with hydroxychloroquine in 61% of cases<sup>9</sup>. Hydroxychloroquine seems to be effective in lupus panniculitis<sup>2</sup>. The time to clinical response is another



**Figure 1** Hydroxychloroquine in dermatology.

**Table 1** Pharmacokinetics of Hydroxychloroquine.

Rapidly absorbed in the gastrointestinal tract
High oral bioavailability (75%-100%)
Long half-life <sup>a</sup>
Cutaneous levels 100- to 200-fold higher than in plasma
Excreted via the kidneys (45%) and gastrointestinal tract (20%)
Alkalinization of urine increases excretion
Metabolized by cytochrome P450
Plasma levels are not affected by cytochrome P450 inducers or inhibitors

Source: Chew et al.<sup>2</sup>, Sardana et al.<sup>3</sup>, Fernandez<sup>1</sup>.

<sup>a</sup> The long half-life of hydroxychloroquine makes it possible to prescribe different doses on alternate days. For example, to prescribe 300 mg/d, doses of 400 mg/d can be alternated with 200 mg/d.

factor that depends on the subtype of CLE; therefore, the effectiveness of hydroxychloroquine should be evaluated at 4 weeks in acute disease, 5 weeks in subacute disease, and 8 weeks in chronic disease<sup>10</sup>.

Various alternatives can be used for CLE that fails to respond to hydroxychloroquine. These include determining plasma levels of hydroxychloroquine. In SLE, therapeutic levels are between 500 and 1000 ng/mL. The optimal ranges for CLE have not yet been determined. Values lower than 200 ng/mL are associated with poor adherence. In refractory cases, increasing the dose to concentrations higher than 750 ng/mL has been associated with a significant improvement in symptoms<sup>1</sup>. Another option involves switching to chloroquine, which improves the skin condition in a significant percentage of patients, albeit with a poorer safety profile. Hydroxychloroquine can also be combined with quinacrine 100 mg/d<sup>2,3</sup>. This agent is not sold in Spain and must be obtained as a foreign medication.

### Dermatomyositis

Treatment of the cutaneous manifestations of dermatomyositis can prove more difficult than that of the muscular manifestations. A retrospective multicenter study of 115 persons (93 with amyopathic dermatomyositis and 22 with hypomyopathic dermatomyositis) showed that antimalarial agents were the most frequently indicated treatment (76%), with skin involvement controlled in only 11%. Most patients needed immunosuppressants or immunoglobulins<sup>11</sup>. Similar results were recorded in a cohort study of 41 persons with amyopathic dermatomyositis<sup>12</sup>. A recent study revealed a significant increase in interferon  $\beta$ -producing myeloid dendritic cells in the skin of patients with dermatomyositis who had not responded to treatment with hydroxychloroquine. The increase in this cell subtype could account for the diminished response to antimalarial drugs<sup>13</sup>.

Some studies have reported that individuals with dermatomyositis may be more frequently affected by hydroxychloroquine-induced cutaneous adverse effects (around 10%) than patients with SLE<sup>14</sup>, although this has not been confirmed by other authors.

### Morphea

A recent retrospective study (n=84) reported a complete response rate that was greater than 40% and a partial response rate of around 50%. The median time to optimal clinical response was 12 months. Patients with plaque morphea responded better than those with generalized, linear, or deep forms<sup>15</sup>. Another retrospective study of 16 patients with eosinophilic fasciitis showed that 25% of patients who received hydroxychloroquine in monotherapy achieved a complete response and 50% a partial response. Hydroxychloroquine was a good alternative, although it was not superior to oral corticosteroids<sup>16</sup>.

**Table 2** Mechanism of Action of Hydroxychloroquine.

Immunomodulatory action	Inhibits antigen presentation via the major histocompatibility complex Stabilizes lysosomal membranes Diminishes cell-mediated cytotoxicity Inhibits multiple intracellular toll-like receptors
Anti-inflammatory action	Inhibits interleukin 1, 2, and 6, tumor necrosis factor $\alpha$ , and interferon $\alpha$ and $\gamma$
Photoprotective action	Reduces phospholipase A2 and C and synthesis of prostaglandins Presents antioxidant properties and protects from damage by free radicals induced by UV radiation Absorbs UV radiation Binds to DNA, thus stabilizing it Regulates RNA transcription Reduces levels of interleukin after UV irradiation Reduces antigen presentation in irradiated skin
Antibacterial and antiviral action	Alkalinizes intracellular organelles and phagosomes, thus reducing growth and survival of intracellular bacteria and viruses Boosts intracellular action of antibiotics Inhibits posttranslational modification of viral proteins Inhibits production of sialic acid
Antithrombotic action	Inhibits platelet aggregation and adhesion Increases endothelium-mediated vasodilation Inhibits formation of antiphospholipid antibodies
Lipid-lowering action	Increases the amount of LDL receptors
Hypoglycemic action	Increases excretion of lipids Increases secretion of insulin Increases sensitivity to insulin

Source: Chew et al.<sup>2</sup>, Sardana et al.<sup>3</sup>.

**Table 3** Risk Factors For Hydroxychloroquine-Induced Retinopathy.

Dose > 5 mg/kg (real weight)/d <sup>a</sup>
Duration of treatment > 5 y
Cumulative dose > 1000 g <sup>b</sup>
Kidney failure <sup>c</sup>
Previous macular or retinal disease
Concomitant tamoxifen

Source: Fernandez<sup>1</sup>, Chew et al.<sup>2</sup>, Melles and Marmor<sup>6</sup>.

<sup>a</sup> Doses > 5 mg entail a risk of retinopathy of 10% at 10 years and of approximately 40% at 20 years. Doses of 4-5 mg/kg/d involve a risk of < 2% after 10 years of therapy.

<sup>b</sup> Cumulative doses of 1000 g are reached after 7 years of therapy with hydroxychloroquine 400 mg/d.

<sup>c</sup> A 50% reduction in the glomerular filtration rate is associated with double the risk of retinal toxicity.

### Urticarial vasculitis

A retrospective multicenter study of 57 persons with hypocomplementemic urticarial vasculitis revealed that hydroxychloroquine was effective as a first-line treatment, with response rates similar to those of systemic corticosteroids and an overall response rate (complete + partial) of more than 50%, albeit with reduced efficacy in cases of recurrence and cases refractory to other drugs<sup>17</sup>. A recent

systematic review on urticarial vasculitis concluded that hydroxychloroquine (400 mg/d) is potentially effective in this disease and enables corticosteroids to be tapered<sup>18</sup>.

### Lichen planus

A retrospective study (n=61) of patients with cutaneous lichen planus (54%), cutaneous and mucosal lichen planus (25%), or mucosal lichen planus (21%) revealed resolution of symptoms in 61% of patients treated with hydroxychloroquine 400 mg/d in a mean of 80 days<sup>19</sup>. Favorable responses have been reported in isolated cases of actinic lichen planus<sup>20</sup>.

In a series of 21 patients with oral erosive lichen planus treated with hydroxychloroquine 400 mg/d for 2 to 4 months, a complete response was recorded in 24% and at least moderate improvement in 57%<sup>21</sup>. A previous open-label clinical trial (n=10) had found similar results.<sup>22</sup> In a prospective study (n=8), a significant clinical improvement was recorded in all patients with antimalarial drugs (7 with chloroquine 3.5-6 mg/kg/d and 1 with hydroxychloroquine 400 mg/d) after a mean of 2.4 months<sup>23</sup>. A retrospective study of patients with lichen planus of the vulva and vagina (n=15) revealed a clinical response rate of 60% with a dose of hydroxychloroquine 200-800 mg/d (400 mg/d in most patients); median time to response was 5 months<sup>24</sup>.

**Table 4** Potential Adverse Effects of Hydroxychloroquine.

Gastrointestinal	Anorexia, heartburn, diarrhea, and abdominal distension
Ocular	Alteration of ocular accommodation (reversible) Retinopathy (irreversible) <sup>a</sup> Corneal opacities and corneal edema (reversible)
Cutaneous	Skin rash, hyperpigmentation (reversible), and pruritus Other infrequent effects include erythema multiforme, DRESS syndrome, Stevens-Johnson syndrome, TEN, AGEP, <sup>b</sup> photosensitivity
Cardiac	Conduction alterations Ventricular arrhythmia Restrictive and obstructive heart disease Congestive heart failure
Muscular	Proximal myopathy
Hematologic	Agranulocytosis, leukopenia, and anemia
Hepatic	Hepatotoxicity
Neuropsychiatric	Nightmares, irritability, mood alterations

Abbreviations: AGEP, acute generalized exanthematous pustulosis; DRESS, drug reaction with eosinophilia and systemic symptoms; TEN, toxic epidermal necrolysis.

Source: Chew et al.<sup>2</sup>, Sardana et al.<sup>3</sup>.

<sup>a</sup> The initial presentation of retinopathy is frequently asymptomatic or with paracentral, temporal, or pericentral scotoma.

<sup>b</sup> Hydroxychloroquine is one of the main drugs involved in the development of AGEP, although this finding is infrequent.

**Table 5** Hydroxychloroquine in Clinical Practice: Dose, Monitoring, and Precautions.

Dose	Most frequently used dose: 400 mg/d ( $\leq 5$ mg/kg [real weight]/d) In cases where therapy fails, plasma levels can be measured. Target level: $> 750$ ng/mL <sup>a</sup>
Monitoring	<i>Ophthalmology:</i> Baseline assessment during the first year of treatment and annually after the fifth year <sup>b</sup> <i>Laboratory:</i> Complete blood count and biochemical profile including kidney function and liver values before initiation of treatment <sup>c</sup>
Precautions	Recommend stopping smoking (reduces the effect of antimalarial drugs) Strict laboratory testing in patients with kidney failure Cumulative doses (and the risk of retinopathy) can be decreased by discontinuing after 6-12 months in cutaneous lupus erythematosus or during periods of reduced risk (winter)

Source: Fernandez<sup>1</sup>, Chew et al.<sup>2</sup>, Melles and Marmor<sup>6</sup>.

<sup>a</sup> Plasma levels should be measured every 3 months, with 200-mg increases in dose until target values are reached. The dose can then be reduced to 400 mg/d, with good responses maintained in most cases.

<sup>b</sup> Assessment should include campimetry and optical coherence tomography. This can be performed at shorter intervals in high-risk patients (Table 3). Ophthalmological screening does not prevent damage, but only makes it possible to detect retinopathy at early stages and thus prevent progression. Treatment should be discontinued if retinopathy is suspected.

<sup>c</sup> No agreement on the need for regular checkups or on optimal intervals. Measurement of glucose-6-phosphate dehydrogenase levels is not necessary.

### Lichen planopilaris

A retrospective study of 23 patients with lichen planopilaris (n = 40) revealed a complete response with hydroxychloroquine in 61% of patients<sup>25</sup>. Another retrospective study reported diminished disease activity in 83% of cases after 12 months of treatment<sup>26</sup>. However, methotrexate proved superior to hydroxychloroquine for reducing disease activity in a randomized clinical trial (n = 29)<sup>27</sup>.

### Frontal fibrosing alopecia

A recent review of the literature reported stabilization of frontal fibrosing alopecia in 71% of cases (41/58). The authors recommended hydroxychloroquine as second-line therapy after combination therapy with intralesional corticosteroids and topical minoxidil and tacrolimus<sup>28</sup>. A retrospective study of 36 patients with frontal fibrosing

alopecia treated with various drugs (16 with hydroxychloroquine) revealed a response rate of 73% for hydroxychloroquine, although most were partial responses (64%)<sup>29</sup>. Similar results were reported in another retrospective study that included 11 patients with frontal fibrosing alopecia<sup>26</sup>. A large-scale retrospective multicenter study revealed stabilization of disease with hydroxychloroquine in 59% of cases (32/54) and improvement of symptoms in 15% (8/54)<sup>30</sup>.

### Alopecia areata

A retrospective study of 9 children with refractory alopecia areata (7 with severe alopecia areata) revealed regrowth greater than 50% in 5 cases (2 patients reached an almost complete response after 1 year of therapy)<sup>31</sup>. However, no

**Table 6** Main Clinical Studies on the Use of Hydroxychloroquine in Cutaneous Lupus Erythematosus<sup>a</sup>.

Author, year	Type of study	Objective	No. of patients	Main findings
Ruzicka et al., 1992	Randomized clinical trial	Compare HCQ and acitretin	58 patients with CDCL y SACLE (28 treated with HCQ)	Favorable response in 50% of cases. Similar results for both drugs. Better safety profile with HCQ
Chang et al., 2011	Prospective cohort study	Evaluate the effectiveness of antimalarial drugs	128 patients with CLE	Significant improvement in 55% of patients at 2 mo. Addition of quinacrine enabled nonresponders to achieve a good response in 67% of cases
Wahie et al., 2011	Multicenter retrospective study	Evaluate the effectiveness of HCQ and the effect of genetic polymorphisms on clinical response	200 patients with CDCL	Response in 60%
Frances et al., 2012	Prospective multicenter study	Study the relationship between blood concentrations of HCQ and clinical efficacy	300 patients with CCL or SACLE	Medication was suspended in 4% of cases owing to adverse effects No differences in genetic metabolism profiles Complete remission in 38%, partial remission in 29%, no response in 33%
Alniemi et al., 2017	Retrospective study	Evaluate clinical characteristics, associated diseases, and outcomes of therapy	90 patients with SACLE (46 patients treated with HCQ)	Response improved with the increased plasma concentration of HCQ Complete response in 74% of patients treated with HCQ
Yokohama et al., 2017	Randomized clinical trial	Evaluate efficacy and tolerability of HCQ	103 patients with CLE	Higher percentage of improvement or marked improvement with HCQ than with placebo (51.4% vs 8.7%) ( $P = .0002$ )
Ototake et al., 2019	Retrospective study	Study the efficacy of HCQ in various subtypes of CLE	35 patients with CLE	Favorable response in 87% (ACLE > SACLE > CCL). More rapid response in ACLE, slower response in CCL

Abbreviations: ACLE, acute cutaneous lupus erythematosus; CCL, chronic cutaneous lupus; CDCL, chronic discoid cutaneous lupus; CLE, cutaneous lupus erythematosus; HCQ, hydroxychloroquine; SACLE, subacute cutaneous lupus erythematosus.

Source: Shipman et al.<sup>9</sup>, Ototake et al.<sup>10</sup>.

<sup>a</sup> Studies with more than 30 patients were selected.

favorable responses were observed in a series of 8 adult patients<sup>2</sup>.

### Chronic spontaneous urticaria

A randomized clinical trial including 48 patients with H<sub>1</sub> antihistamine–refractory chronic spontaneous urticaria compared the combination of placebo and high doses of H<sub>1</sub> antihistamines (4 tablets per day) with the combination of hydroxychloroquine and high-dose H<sub>1</sub> antihistamines. In the hydroxychloroquine group, 28% achieved full remission compared with 0% in the control group ( $P = .01$ )<sup>32</sup>.

### Granulomatous Skin Diseases

#### Granuloma annulare

A retrospective study of 18 patients, most of whom had generalized granuloma annulare showed that 55% improved with hydroxychloroquine<sup>33</sup>. Similar results were found in a prospective case series ( $n = 9$ )<sup>34</sup>. Favorable results have been reported in annular elastolytic giant-cell granuloma<sup>2</sup>.

#### Necrobiosis lipidica

In a series of 8 patients treated with antimalarial agents (6 with chloroquine and 2 with hydroxychloroquine), an almost complete response was recorded in 4 patients and stabiliza-

**Table 7** Off-Label Use of Hydroxychloroquine in Dermatology and Type of Study Supporting it for Each Disease.

Disease	Study supporting use
Dermatomyositis	Retrospective studies
Morphea	Retrospective studies
Granuloma annulare	Retrospective studies
Necrobiosis lipoidica	Case series
Cutaneous sarcoidosis	Open-label clinical trial
Spontaneous chronic urticaria	Randomized clinical trial
Urticarial vasculitis	Retrospective studies
Lichen planus	Retrospective studies, open-label clinical trial
Alopecia areata	Retrospective studies
Porphyria cutanea tarda	Randomized clinical trials
Polymorphic light eruption	Randomized clinical trials
Rosacea	Randomized clinical trial
Lichen sclerosus	Small case series or isolated cases
Lipodermatosclerosis	Small case series or isolated cases
Chronic actinic dermatitis	Small case series or isolated cases
Actinic pruritus	Small case series or isolated cases
Urticaria solar	Small case series or isolated cases
Schnitzler syndrome	Small case series or isolated cases
Scleromyxedema	Small case series or isolated cases
Eosinophilic annular erythema	Small case series or isolated cases
Antiphospholipid syndrome	Retrospective studies
Kikuchi-Fujimoto disease	Small case series or isolated cases
Pseudolymphoma	Small case series or isolated cases
Chronic erythema nodosum	Small case series or isolated cases

tion of symptoms in <sup>35</sup>. Favorable findings have also been reported in isolated cases of ulcerative forms<sup>36</sup>.

#### Cutaneous sarcoidosis

An open-label clinical trial (n=17) revealed that 71% of patients achieved a complete clinical response and 33% a partial response<sup>37</sup>. In a series of 3 cases, the lesions resolved in all 3 patients<sup>38</sup>. Complete remission with oral prednisone and hydroxychloroquine has also been reported with ulcerative cutaneous sarcoidosis<sup>39</sup>.

#### Photoinduced/Photoaggravated Dermatoses

##### Porphyria cutanea tarda

A randomized clinical trial (n=48) found that low-dose hydroxychloroquine (100 mg twice weekly) was as effective and safe as phlebotomy in patients with porphyria cutanea tarda. The median time to clinical remission was 6.1 months<sup>40</sup>. Similar results were recorded in another trial (n=40) in alcoholic patients with porphyria cutanea tarda<sup>41</sup>.

##### Polymorphic light eruption

A clinical trial including 117 patients with polymorphic light eruption showed that hydroxychloroquine (400 mg/d for 1 month followed by 200 mg/d for a further month) was superior to chloroquine for control of sunburn, pruritus, scaling, and erythema. The clinical response was good or excellent in 69% of patients and complete in 44%<sup>42</sup>. A previous clinical trial (n=13) had shown moderate clinical responses with a significant reduction in erythema when used in summer (400 mg/d for 1 month followed by 200 mg/d for 2 months)<sup>43</sup>.

#### Actinic prurigo

Hydroxychloroquine is a safe and effective option in children with actinic prurigo at doses of 3-5 mg/kg (the dose can be reduced by half after a few months)<sup>44</sup>.

#### Rosacea

A clinical trial analyzing 66 patients with rosacea compared the effectiveness of hydroxychloroquine 400 mg/d with that of doxycycline 100 mg/d for 2 months; similar results were reported for both groups. The authors concluded that hydroxychloroquine could be effective in this disease and, therefore, could be used for the treatment of rosacea in pregnant women, for whom few alternative treatments are available<sup>45</sup>.

#### Other Dermatologic Diseases

Favorable responses to hydroxychloroquine have been reported in the treatment of diseases such as lichen sclerosus, reticular erythematous mucinosis, lipodermatosclerosis, chronic ulcerative stomatitis, chronic actinic dermatitis, solar urticaria<sup>2</sup>, Schnitzler syndrome, scleromyxedema, eosinophilic annular erythema, antiphospholipid syndrome, Kikuchi-Fujimoto disease<sup>1</sup>, pseudolymphoma<sup>3</sup>, Jessner lymphocytic infiltration of the skin, pemphigus foliaceus, interstitial granulomatous dermatitis, follicular mucinosis, and chronic erythema nodosum<sup>46</sup> (Table 7).

As we have seen, hydroxychloroquine is a polyvalent drug. It can be prescribed in many skin conditions, with favorable clinical outcomes. Its immunomodulatory—but not immunosuppressive—action and favorable safety profile make it suitable even for children and pregnant and breast-

feeding women<sup>1</sup>. Given that a satisfactory clinical response generally takes several months, patients should be forewarned in order to avoid discontinuation.

## Hydroxychloroquine and COVID-19

Hydroxychloroquine has potent antifungal, antibacterial, and antiviral properties. An antiviral effect has been reported against a series of viruses, including influenza A and B, hepatitis B and C, herpes simplex, chikungunya, dengue, Zika, and Ebola.

Hydroxychloroquine was considered one of the most promising drugs for the treatment of COVID-19. Its role as an antiviral agent is based on its potential ability to inhibit fusion of the virus with the host cell, block transport of the virus from the endosomes to the endolysosomes, and diminish the cytokine storm in severely ill patients<sup>3</sup>. Antimalarial drugs interfere with glycosylation of the angiotensin-converting enzyme receptor, which is used by SARS-CoV-2 to enter cells, thus reducing viral penetration. They also alkalinize endosomes and endocytic vesicles, thus altering endocytosis of the virus, and diminish release of proinflammatory cytokines by reducing antigen presentation (especially of self-antigens) and activation of CD4<sup>+</sup> T lymphocytes. They also reduce intracellular signaling of toll-like receptors<sup>47,48</sup>.

Despite the absence of consistent evidence that hydroxychloroquine was effective for treatment or prevention of COVID-19 and the fact that the Infectious Diseases Society of America only recommended it within the setting of randomized clinical trials, this antimalarial agent was used in various hospital treatment protocols and even recommended to the general public<sup>4</sup>. The United States Food and Drug Administration warned about potential cardiovascular effects of the drug and then authorized it for use in patients hospitalized with COVID-19 (March 28, 2020). They subsequently withdrew this authorization (June 15, 2020)<sup>49</sup>. The high demand for the drug (which multiplied 80-fold in the USA) led to difficulties with administration and shortages<sup>5</sup>. Furthermore, India, one of the main producers of generic hydroxychloroquine, temporarily banned exportation of the drug, thus affecting the global supply chain<sup>4</sup>. In an international survey sent to members of the Systemic Lupus International Collaborating Clinics (29% European), 55% reported a shortage of supplies of hydroxychloroquine for patients with SLE during the pandemic<sup>50</sup>. Other authors reported anxiety and uncertainty among patients with SLE who could not access the drug<sup>8,51</sup>. Furthermore, a major impact on malaria control programs was observed<sup>5,52</sup>. We were unable to find original articles on the impact of the shortage on patients with dermatologic conditions, although we believe that if this had continued over time, then the impact would have been considerable.

As for the effectiveness of hydroxychloroquine in COVID-19, a recent meta-analysis of 14 studies (n = 12 455) found no significant differences in survival, improvement in symptoms at day 10, or seroconversion rate and reported a greater frequency of cardiovascular and gastrointestinal effects than in the control groups<sup>49</sup>. A recent Cochrane database review revealed no significant differences in the risk of death from COVID-19 (or in the need for mechanical ventilation) when

hydroxychloroquine was prescribed, and the authors recommended not performing further randomized clinical trials with this drug for this disease<sup>53</sup>. Similarly, a recent randomized clinical trial (n = 2314) was unable to find a positive effect for hydroxychloroquine as prophylaxis in COVID-19<sup>54</sup>.

Hydroxychloroquine is a key drug for control of malaria and treatment of patients with specific rheumatologic and/or dermatologic conditions. We feel that it is important to recommend caution when prescribing this drug off-label for other conditions (including COVID-19) in order to ensure supply to those patients who need it.

## Conclusions

Hydroxychloroquine is an essential element of the dermatologist's therapeutic arsenal. It is indicated as first- or second-line therapy in many photoinduced and photoaggravated inflammatory and granulomatous skin diseases. Using hydroxychloroquine for the treatment and prevention of COVID-19 has proven unsatisfactory and led to supply difficulties. Greater caution is required when recommending large-scale, off-label prescription of hydroxychloroquine to ensure that patients who need this drug have access to it.

## Conflicts of Interest

The authors declare that they have no conflicts of interest.

## References

1. Fernandez AP. Updated recommendations on the use of hydroxychloroquine in dermatologic practice. *J Am Acad Dermatol*. 2017;76:1176–82.
2. Chew CY, Mar A, Nikpour M, Saracino AM. Hydroxychloroquine in dermatology: new perspectives on an old drug. *Australas J Dermatol*. 2020;61:e150–7.
3. Sardana K, Sinha S, Sachdeva S. Hydroxychloroquine in dermatology and beyond: recent update. *Indian Dermatol Online J*. 2020;11:453–64.
4. Cox S. To dispense or not to dispense: lessons to be learnt from ethical challenges faced by pharmacists in the COVID-19 pandemic. *Dev World Bioeth*. 2020. <http://dx.doi.org/10.1111/dewb.12284>.
5. Baral S, Rao A, Rwema JOT, Lyons C, Cevik M, Kågesten AE, et al. Competing health risks associated with the COVID-19 pandemic and response: a scoping review. *medRxiv*. 2021. <http://dx.doi.org/10.1101/2021.01.07.21249419>.
6. Melles RB, Marmor MF. The risk of toxic retinopathy in patients on long-term hydroxychloroquine therapy. *JAMA Ophthalmol*. 2014;132:1453–60.
7. Mohammad S, Clowse MEB, Eudy AM, Criscione-Schreiber LG. Examination of hydroxychloroquine use and hemolytic anemia in G6PDH-Deficient patients. *Arthritis Care Res (Hoboken)*. 2018;70:481–5.
8. Peschken CA. Possible consequences of a shortage of hydroxychloroquine for patients with systemic lupus erythematosus amid the COVID-19 pandemic. *J Rheumatol*. 2020;47:787–90.
9. Shipman WD, Vernice NA, Demetres M, Jorizzo JL. An update on the use of hydroxychloroquine in cutaneous lupus erythematosus: a systematic review. *J Am Acad Dermatol*. 2020;82:709–22.
10. Ototake Y, Yamaguchi Y, Kanaoka M, Akita A, Ikeda N, Aihara M. Varied responses to and efficacies of hydroxychloroquine treat-



- ment according to cutaneous lupus erythematosus subtypes in Japanese patients. *J Dermatol.* 2019;46:285–9.
11. Pinard J, Femia AN, Roman M, Alsarheed A, Joyce C, Lin J, et al. Systemic treatment for clinically amyopathic dermatomyositis at 4 tertiary care centers. *JAMA Dermatol.* 2019;155:494–6.
  12. Anyanwu CO, Chansky PB, Feng R, Carr K, Okawa J, Werth VP. The systemic management of cutaneous dermatomyositis: results of a stepwise strategy. *Int J Womens Dermatol.* 2017;3:189–94.
  13. Chen KL, Patel J, Zeidi M, Wysocka M, Bashir MM, Patel B, et al. Myeloid dendritic cells are major producers of interferon- $\beta$  in dermatomyositis and may contribute to hydroxychloroquine refractoriness. *J Invest Dermatol.* 2021;141, 1906–1914.e2.
  14. Akabane AL, Smith GP. Adverse cutaneous reactions secondary to hydroxychloroquine in patients with dermatomyositis, lupus erythematosus, and lichen planopilaris. *J Am Acad Dermatol.* 2021;85:1046–7, <http://dx.doi.org/10.1016/j.jaad.2021.02.034>.
  15. Kumar AB, Blixt EK, Drage LA, El-Azhary RA, Wetter DA. Treatment of morphea with hydroxychloroquine: a retrospective review of 84 patients at Mayo Clinic, 1996–2013. *J Am Acad Dermatol.* 2019;80:1658–63.
  16. Lakhanpal S, Ginsburg WW, Michet CJ, Doyle JA, Moore SB. Eosinophilic fasciitis: clinical spectrum and therapeutic response in 52 cases. *Semin Arthritis Rheum.* 1988;17:221–31.
  17. Jachiet M, Flageul B, Deroux A, le Quellec A, Maurier F, Cordoliani F, et al. The clinical spectrum and therapeutic management of hypocomplementemic urticarial vasculitis: data from a French nationwide study of fifty-seven patients. *Arthritis Rheumatol.* 2015;67:527–34.
  18. Kolkhir P, Grakhova M, Bonnekh H, Krause K, Maurer M. Treatment of urticarial vasculitis: a systematic review. *J Allergy Clin Immunol.* 2019;143:458–66.
  19. Hunt KM, Klager S, Kwak YJ, Sami N. Successful systemic treatment outcomes of lichen planus: a single-center retrospective review. *Dermatol Ther.* 2021:e14903.
  20. Ramírez P, Feito M, Sendagorta E, González-Beato M, Lucas RD. Childhood actinic lichen planus: successful treatment with anti-malarials. *Australas J Dermatol.* 2012;53:e10–3.
  21. Yeshurun A, Bergman R, Bathish N, Khamaysi Z. Hydroxychloroquine sulphate therapy of erosive oral lichen planus. *Australas J Dermatol.* 2019;60:e109–12.
  22. Eisen D. Hydroxychloroquine sulfate (Plaquenil) improves oral lichen planus: an open trial. *J Am Acad Dermatol.* 1993;28:609–12.
  23. Rivas-Tolosa N, Requena C, Llombart B, Alcalá R, Serra-Guillén C, Calomarde L, et al. Antimalarial drugs for the treatment of oral erosive lichen planus. *Dermatology.* 2016;232:86–90.
  24. Vermeer HB, Rashid H, Esajas MD, Oldhoff JM, Horváth B. The use of hydroxychloroquine as a systemic treatment in erosive lichen planus of the vulva and vagina. *Br J Dermatol.* 2021;185:201–3, <http://dx.doi.org/10.1111/bjd.19870>.
  25. Nic Dhonncha E, Foley CC, Markham T. The role of hydroxychloroquine in the treatment of lichen planopilaris: a retrospective case series and review. *Dermatol Ther.* 2017;30, <http://dx.doi.org/10.1111/dth.12463>.
  26. Chiang C, Sah D, Cho BK, Ochoa BE, Price VH. Hydroxychloroquine and lichen planopilaris: efficacy and introduction of Lichen Planopilaris Activity Index scoring system. *J Am Acad Dermatol.* 2010;62:387–92.
  27. Naeini FF, Saber M, Asilian A, Hosseini SM. Clinical efficacy and safety of methotrexate versus hydroxychloroquine in preventing lichen planopilaris progress: a randomized clinical trial. *Int J Prev Med.* 2017;8:37.
  28. Ho A, Shapiro J. Medical therapy for frontal fibrosing alopecia: a review and clinical approach. *J Am Acad Dermatol.* 2019;81:568–80.
  29. Samrao A, Chew A-L, Price V. Frontal fibrosing alopecia: a clinical review of 36 patients. *Br J Dermatol.* 2010;163:1296–300.
  30. Vañó-Galván S, Molina-Ruiz AM, Serrano-Falcón C, Arias-Santiago S, Rodrigues-Barata AR, Garnacho-Saucedo G, et al. Frontal fibrosing alopecia: a multicenter review of 355 patients. *J Am Acad Dermatol.* 2014;70:670–8.
  31. Yun D, Silverberg NB, Stein SL. Alopecia areata treated with hydroxychloroquine: a retrospective study of nine pediatric cases. *Pediatr Dermatol.* 2018;35:361–5.
  32. Boonpiyathad T, Sangasapaviliya A. Hydroxychloroquine in the treatment of anti-histamine refractory chronic spontaneous urticaria, randomized single-blinded placebo-controlled trial and an open label comparison study. *Eur Ann Allergy Clin Immunol.* 2017;49:220–4.
  33. Grewal SK, Rubin C, Rosenbach M. Antimalarial therapy for granuloma annulare: Results of a retrospective analysis. *J Am Acad Dermatol.* 2017;76:765–7.
  34. Cannistraci C, Lesnoni La Parola I, Falchi M, Picardo M. Treatment of generalized granuloma annulare with hydroxychloroquine. *Dermatology.* 2005;211:167–8.
  35. Durupt F, Dalle S, Debarbieux S, Balme B, Ronger S, Thomas L. Successful treatment of necrobiosis lipoidica with antimalarial agents. *Arch Dermatol.* 2008;144:118–9.
  36. Kavala M, Sudogan S, Zindanci I, Kocaturk E, Can B, Turkoglu Z, et al. Significant improvement in ulcerative necrobiosis lipoidica with hydroxychloroquine. *Int J Dermatol.* 2010;49:467–9.
  37. Jones E, Callen JP. Hydroxychloroquine is effective therapy for control of cutaneous sarcoid granulomas. *J Am Acad Dermatol.* 1990;23:487–9.
  38. Modi S, Rosen T. Micropapular cutaneous sarcoidosis: case series successfully managed with hydroxychloroquine sulfate. *Cutis.* 2008;81:351–4.
  39. Powell E, Rosen T. Ulcerative sarcoidosis: a prototypical presentation and review. *Cutis.* 2017;100:312–6.
  40. Singal AK, Kormos-Hallberg C, Lee C, Sadagoparamanujam VM, Grady JJ, Freeman DH, et al. Low-dose hydroxychloroquine is as effective as phlebotomy in treatment of patients with porphyria cutanea tarda. *Clin Gastroenterol Hepatol.* 2012;10:1402–9.
  41. Marchesi L, di Padova C, Cainelli T, Reseghetti A, Di Padova F, Rovagnati P, et al. A comparative trial of desferrioxamine and hydroxychloroquine for treatment of porphyria cutanea tarda in alcoholic patients. *Photodermatology.* 1984;1:286–92.
  42. Pareek A, Khopkar U, Sacchidanand S, Chandurkar N, Naik GS. Comparative study of efficacy and safety of hydroxychloroquine and chloroquine in polymorphic light eruption: a randomized, double-blind, multicentric study. *Indian J Dermatol Venereol Leprol.* 2008;74:18–22.
  43. Murphy GM, Hawk JL, Magnus IA. Hydroxychloroquine in polymorphic light eruption: a controlled trial with drug and visual sensitivity monitoring. *Br J Dermatol.* 1987;116:379–86.
  44. Magaña-García M. Antimalarials for children. *J Am Acad Dermatol.* 1994;30:510.
  45. Wang B, Yuan X, Huang X, Tang Y, Zhao Z, Yang B, et al. Efficacy and safety of hydroxychloroquine for treatment of patients with rosacea: a multicenter, randomized, double-blind, double-dummy, pilot study. *J Am Acad Dermatol.* 2021;84:543–5.
  46. Jarrett P, Goodfield MJ. Hydroxychloroquine and chronic erythema nodosum. *Br J Dermatol.* 1996;134:373.
  47. Ortega-Peña M, González-Cuevas R. Familiar dermatologic drugs as therapies for COVID-19. *Actas Dermosifiliogr.* 2021;112:118–26.
  48. Stojkovic-Filipovic J, Bosic M. Treatment of COVID 19-Repurposing drugs commonly used in dermatology. *Dermatol Ther.* 2020;33:e13829.
  49. Choudhuri AH, Duggal S, Ahuja B, Biswas PS. The efficacy and safety of hydroxychloroquine (HCQ) in treatment of COVID19 – a systematic review and meta-

- analysis. *Indian J Med Microbiol.* 2021;39(2):159–70, <http://dx.doi.org/10.1016/j.ijmmb.2021.03.002>.
50. Mendel A, Bernatsky S, Askanase A, Bae S-C, Clarke AE, Costedoat-Chalumeau N, et al. Hydroxychloroquine shortages among patients with systemic lupus erythematosus during the COVID-19 pandemic: experience of the Systemic Lupus International Collaborating Clinics. *Ann Rheum Dis.* 2021;80:1–2.
  51. Shah M, Sachdeva M, Dodiuk-Gad RP. The impact of hydroxychloroquine shortages on patients with dermatological conditions during COVID-19 pandemic. *Dermatol Ther.* 2020;33:e13524.
  52. Abena PM, Decloedt EH, Bottieau E, Suleman F, Adejumo P, Sam-Agudu NA, et al. Chloroquine and hydroxychloroquine for the prevention or treatment of novel coronavirus disease (COVID-19) in Africa: caution for inappropriate off-label use in healthcare settings. *Am J Trop Med Hyg.* 2020;102:1184–8.
  53. Singh B, Ryan H, Kredo T, Chaplin M, Fletcher T. Chloroquine or hydroxychloroquine for prevention and treatment of COVID-19. *Cochrane Database Syst Rev.* 2021;2:CD013587.
  54. Mitjà O, Corbacho-Monné M, Ubals M, Alemany A, Suñer C, Tebé C, et al. A cluster-randomized trial of hydroxychloroquine for prevention of Covid-19. *N Engl J Med.* 2021;384:417–27.