

12. Li Z, Jiang N, Xu Y. The concurrence of subacute cutaneous lupus erythematosus and hand-foot syndrome in a patient undergoing capecitabine chemotherapy. *Australas J Dermatol.* 2016;57:14–6, <http://dx.doi.org/10.1111/ajd.12224>.
13. Kim WI, Kim JM, Kim GW, Mun JH, Song M, Kim HS, et al. Subacute cutaneous lupus erythematosus induced by capecitabine: 5-FU was innocent. *J Eur Acad Dermatol Venereol.* 2016;30:163–4, <http://dx.doi.org/10.1111/jdv.13468>.

N. Moreiras Arias,<sup>a,\*</sup> M.E. Rosón López,<sup>a</sup>  
J.M. Suárez Peñaranda,<sup>b</sup> H.A. Vázquez Veiga<sup>a</sup>

<sup>a</sup> *Servicio de Dermatología, Complejo Hospitalario Universitario de Santiago de Compostela, Santiago de Compostela, A Coruña, Spain*

<sup>b</sup> *Servicio de Anatomía Patológica, Complejo Hospitalario Universitario de Santiago de Compostela, Santiago de Compostela, A Coruña, Spain*

\* Corresponding author.

E-mail address: [noelia.moreiras.arias@sergas.es](mailto:noelia.moreiras.arias@sergas.es)  
(N. Moreiras Arias).

<https://doi.org/10.1016/j.adengl.2021.07.022>  
1578-2190/ © 2021 Published by Elsevier España, S.L.U. on behalf of AEDV. This is an open access article under the CC BY-NC-ND license (<http://creativecommons.org/licenses/by-nc-nd/4.0/>).

## Secondary Amyloid Deposition in Pigmented Poroma<sup>☆</sup>



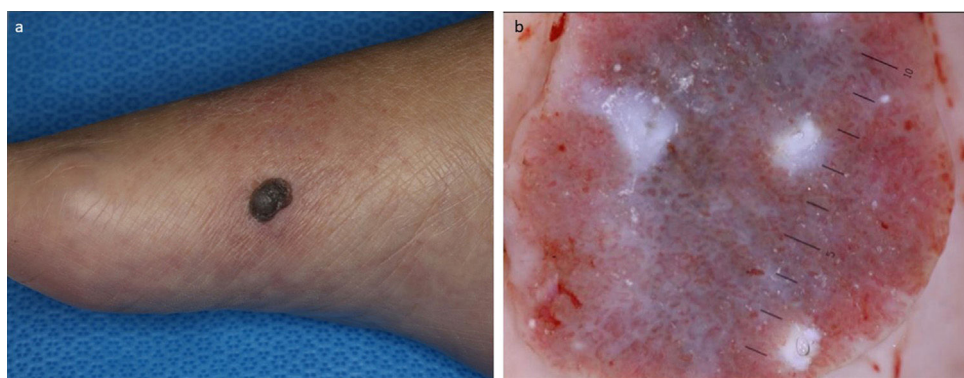
### Depósito de amiloides secundario en poroma pigmentado

Dear Editor,

Secondary amyloid deposition is occasionally observed in both benign and malignant skin tumors; however, amyloid deposition in association with sweat gland neoplasms is rare.<sup>1,2</sup> We herein describe a case of secondary amyloid deposition in pigmented poroma.

A 78-year-old Japanese female visited our department, complaining of a nodule on the foot which appeared one year previously. A physical examination revealed a 13-mm diameter, well-circumscribed brownish nodule on the inner side of

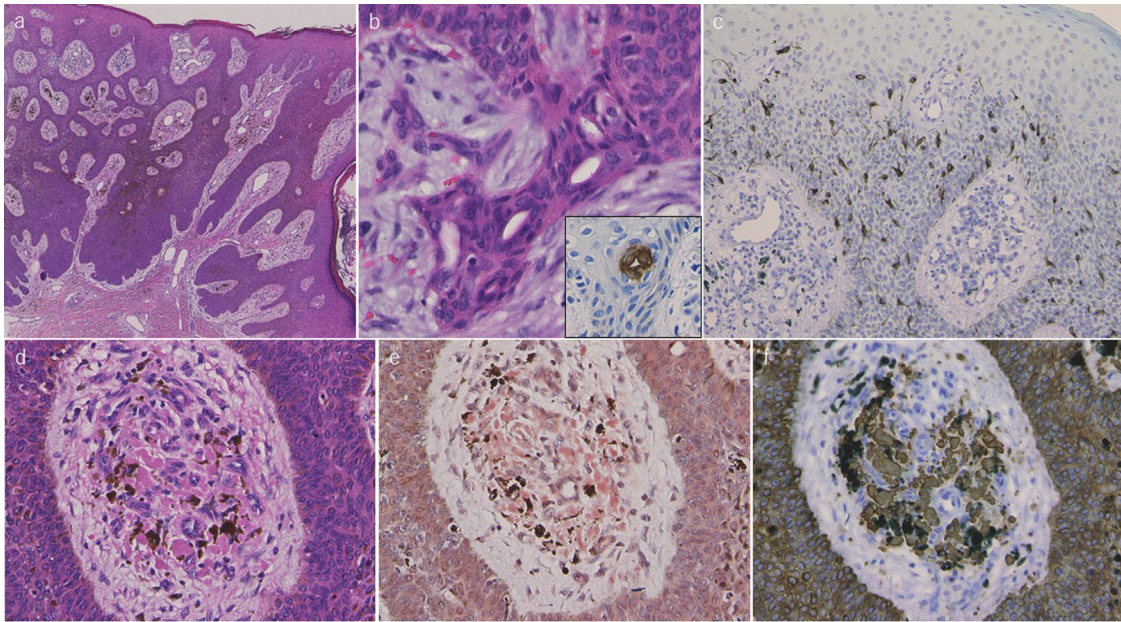
dark-brown, globe-like structures with polymorphous and hairpin vessels (Fig. 1b). After making a diagnosis by punch biopsy, the nodule was surgically removed under local anesthesia. Histological features showed cords of tumor cells extending from the epidermis to the mid-dermis (Fig. 2a). The tumor cells had basophilic cells with small round nuclei and cuticular cells with ductal differentiation showing positive CEA staining (Fig. 2b). Increased number of melanocytes was observed within the nests, which were confirmed by Fontana-Masson and MART-1 (Fig. 2c). The tumor nests contained abundant melanin deposition, and melanophages were also observed in the stroma (Fig. 2d). Of note, a number of circumscribed massive eosinophilic materials were detected within the stroma (Fig. 2d), which were positive for Congo-red and Dylon stain (Fig. 2e), as well as anti-cytokeratin CK5 antibody (Fig. 2f). Systemic amyloidosis was denied.



**Figure 1** A well-circumscribed brownish nodule on the inner side of the right foot (a). Dermoscopy revealed globe-like structures with polymorphous vessels (b).

the right foot (Fig. 1a). Dermoscopic examination showed

<sup>☆</sup> Please cite this article as: Igari S, Ito T, Ishikawa M, Hiraiwa T, Yamamoto T. Depósito de amiloides secundario en poroma pigmentado. *Actas Dermosifiliogr.* 2021;112:862–864.



**Figure 2** Histological features showing basophilic tumor nests extending from the epidermis to the mid-dermis (haematoxylin and eosin) (a). Higher magnification shows ductal structures within the nests (b), which were positively stained for CEA (insert). MART-1 stain revealed an increased number of melanocytes within the tumor nests (c). A number of melanin deposition within the tumor nests, as well as melanophages and amorphous materials in the stroma (d). Amorphous materials in the stroma were positively stained with Congo-red (e) and CK5 (f) (original magnification a:  $\times 40$ , b:  $\times 200$ , c:  $\times 100$ , d-f:  $\times 400$ ).

To date, only a few cases of sweat gland neoplasms with secondary amyloid deposition have been reported.<sup>1,2</sup> Poroma with amyloid deposition was reported by Ueo et al.<sup>2</sup> Their case developed porocarcinoma in the pigmented hidroacanthoma simplex on the buttock. Interestingly, numerous amyloid globules were detected in the upper dermis in consistent with the pigmented hidroacanthoma simplex nests. They speculated that amyloid was synthesized from abnormal keratin derived from tumor cells, based on positive 34 $\beta$ E12 expression. On the other hand, the present case developed secondary amyloidosis associated with Pinkus type pigmented poroma. Detailed physical examination did not show skin manifestation on either back or extremities, and thus the possibility of primary localized cutaneous amyloidosis was excluded.

Pigmented poroma is a rare variant of poroma involving the non-acral sites in patients of ethnicity other than black.<sup>3</sup> Histopathologically, pigmented poroma is characterized by the presence of melanin within the tumor nests and also melanophages in the adjacent stroma, as was observed in the present case. It has been suggested several melanocyte-stimulating factors such as endothelin, stem cell factor, or nerve growth factor, may be associated with melanocyte colonization in pigmented poroma on the non-palmoplantar areas.<sup>4</sup>

Dermoscopy has been occasionally performed for pigmented poromas, and recent studies demonstrated that vascular structures including arborizing vessels, hairpin vessels, and polymorphous vessels, globule-like structures, and comedo-like openings were the main findings of pigmented

poroma.<sup>5</sup> Additionally, various dermoscopic structures were also observed. In the present case, dark-brown, globe-like structures with polymorphous and hairpin vessels were observed. Based on the clinical and dermoscopic features, we suspected poroma and carried out biopsy. Histopathology revealed the nests of poroma cells, and furthermore, showed amorphous materials in the stroma. Results of immunohistochemical examination using anti-CK5 antibody were positive in the amyloid deposition areas, suggesting an epidermal origin of secondary cutaneous amyloid deposition in association with pigmented poroma. Further studies are needed to clarify the mechanisms of secondary amyloid deposition in skin tumors.

## References

1. Ueo T, Kashima K, Daa T, Kondoh Y, Yanagi T, Yokoyama S. Porocarcinoma arising in pigmented hidroacanthoma simplex. *Am J Dermatopathol.* 2005;27:500–3.
2. Saggini A, Mully T. Reactive eccrine syringofibroadenomatosis secondary to primary cutaneous amyloidosis: a novel association. *J Cutan Pathol.* 2014;41:380–5.
3. Phelps A, Murphy MJ. Pigmented classic poromas: a tumor with a predilection for nonacral sites? *J Cutan Pathol.* 2010;37:1121–2.
4. Hu S, Chen G, Wu C, Chai CY, Chen WT, Lan CC. Pigmented eccrine poromas: expression of melanocyte-stimulating cytokines by tumor cells does not always result in melanocyte colonization. *J Eur Acad Dermatol Venereol.* 2008;22:303–10.
5. Minagawa A, Koga H. Dermoscopy of pigmented poromas. *Dermatology.* 2010;221:78–83.



S. Igari, T. Ito, M. Ishikawa, T. Hiraiwa, T. Yamamoto\*

Department of Dermatology, Fukushima Medical University, Fukushima, Japan

\* Corresponding author.

E-mail address: [toyamade@fmu.ac.jp](mailto:toyamade@fmu.ac.jp) (T. Yamamoto).

<https://doi.org/10.1016/j.adengl.2021.06.004>

1578-2190/ © 2021 Published by Elsevier España, S.L.U. on behalf of AEDV. This is an open access article under the CC BY-NC-ND license (<http://creativecommons.org/licenses/by-nc-nd/4.0/>).

## Pityriasis Rosea in a Confirmed COVID-19 Pediatric Patient<sup>☆</sup>



### Pitiriasis rosada en un paciente pediátrico con diagnóstico confirmado de COVID-19

Dear Editor:

On December 31, 2019, the World Health Organization identified a novel coronavirus (SARS-CoV-2) in the city of Wuhan in China that spread very quickly and has to date resulted in the deaths of thousands of people by causing COVID-19 disease. Various Coronavirus disease-19 (COVID-19) associated dermatological manifestations have been reported. Among these, Pityriasis rosea (PR) and PR-like rash have been published previously. During the COVID-19 pandemic, the diagnosis of PR has become more common<sup>1-5</sup>.

PR is a self-limited inflammatory skin disease that can be induced viral agents especially HHV-6 (Human herpes virus 6), HHV-7 (Human herpes virus 7), autoimmunity, psychogenic factors, vaccines and drugs<sup>1,2</sup>.

We present here a case of PR in a confirmed COVID-19 pediatric patient.

A 10-year-old boy presented with a 20-day history of skin rash. It was learned that he had Covid-19 infection about 1 month ago and he did not use any medication. In dermatological examination, there were small plaques with erythema and collary scaly located parallel to the ribs on the body (Fig. 1). Complete blood count, liver and kidney function tests, hepatitis markers, sedimentation and CRP values were in normal ranges. Histopathology of one lesion's biopsy showed focal parakeratotic peaks, spongiosis, focal spongiotic vesiculation, lymphocyte exocytosis, mildly irregular acanthosis with mild homogenization of collagen in the dermis, mild to moderate perivascular erythrocyte infiltration in the superficial vascular plexus, scattered lymphocyte infiltration, sparse lymphocytes was seen (Fig. 2). The diagnosis of PR after Covid -19 infection was established with clinical and histopathologic findings. The patient was treated with betamethasone valerate ointment, 10% urea and cetirizine. Lesions regressed one month later.

The association between PR and COVID-19 infection is not clearly known. In the literature, patients with confirmed COVID-19 developed PR and PR-like rash, some of them while asymptomatic or symptomatic disease, others after COVID-19 infection<sup>2-5</sup>. Therefore, in a patient presenting

with PR and PR-like rash, it is necessary to keep in mind Covid-19 infection and suggest SARS-CoV-2 testing for necessary patients. PR could be directly dependent to COVID-19 infection, or to viral reactivation (HHV-6, HHV-7, EBV)<sup>1-5</sup>. In addition, the increased psychological stress caused by the pandemic period may have contributed to the trigger<sup>1</sup>. Due to the limited number of data, it is very difficult to prove a causal relation in these cases.

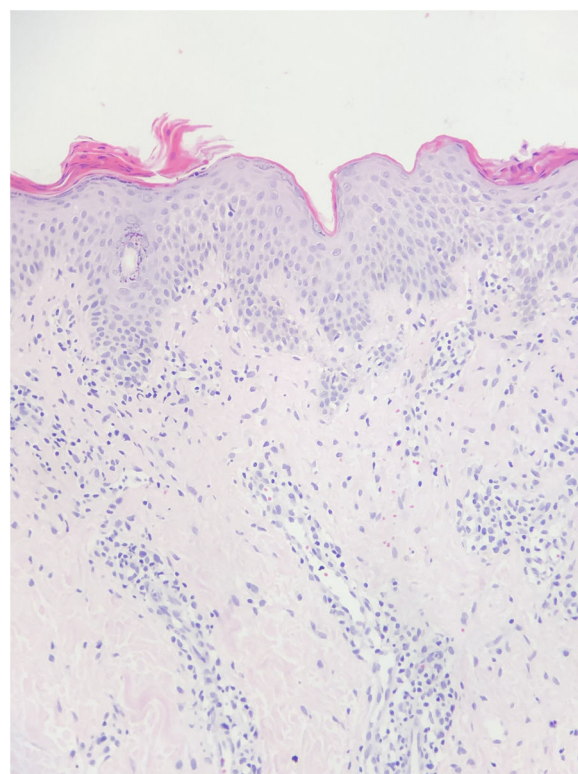
In conclusion, dermatologists should be aware that cutaneous symptoms may be linked to COVID-19 infection.

### Acknowledgment

The patient and his family in this manuscript have given written informed consent to publication of his case details.

### References

1. Dursun R, Temiz SA. The clinics of HHV-6 infection in COVID-19 pandemic: Pityriasis rosea and Kawasaki disease. *Dermatol Ther.* 2020;33:e13730.



**Figure 1** Diffuse erythematous lesions on the trunk and many of lesions had peripheral scales.

<sup>☆</sup> Please cite this article as: Öncü İNS, Güler D, Gürel G, Yalçın GŞ. Pitiriasis rosada en un paciente pediátrico con diagnóstico confirmado de COVID-19. *Actas Dermosifiliogr.* 2021;112:864–865.