

## CASE AND RESEARCH LETTERS

### Acute Postinfection Pityriasis Rubra Pilaris: Excellent Response to Emollients and Topical Corticosteroids<sup>☆</sup>



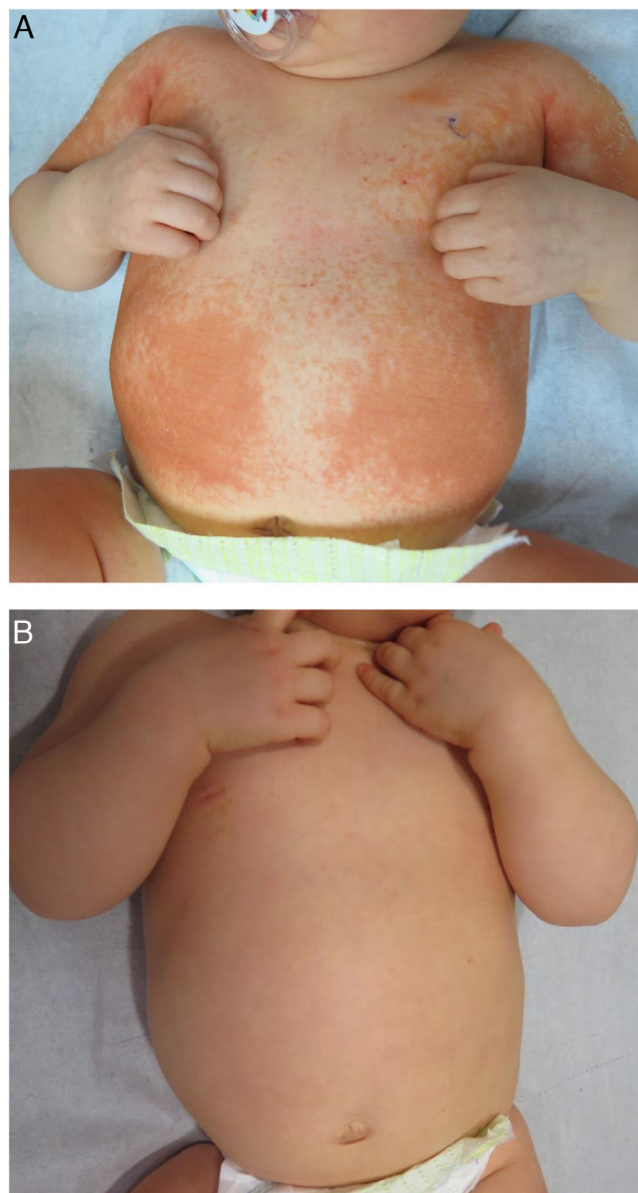
#### Pitiriasis rubra pilaris aguda postinfecciosa: gran respuesta a emolientes y a corticosteroides tópicos

To the Editor:

A 9-month-old boy was seen for a localized skin rash on the abdomen and extremities that had spread rapidly over the preceding 2 months. The patient had no other associated symptoms. His clinical history included multiple episodes of pyelectasis that had been treated with prophylactic antibiotics (cefadroxil) up to 5 months of age. Before the skin lesions appeared, the patient had undergone antibiotic and corticosteroid treatment for multiple viral and bacterial infections of the upper respiratory tract. Physical examination revealed confluent salmon-pink papules and plaques on the trunk and extremities (Fig. 1A), with islands of healthy skin on both legs. Biopsies of the lesions showed acanthosis, hypergranulosis, orthokeratosis, parakeratosis, and mild superficial infiltrate, findings consistent with pityriasis rubra pilaris (PRP) (Fig. 2). The patient was treated for 1 month with topical 0.05% triamcinolone acetonide cream, which resulted in complete resolution of the lesions (Fig. 1B). Due to the patient's clinical history of recent respiratory infections, the early resolution of the skin lesions, and the histological findings, a diagnosis of acute postinfectious PRP was proposed.

PRP is a skin disease that rarely affects children. In 1980, Griffiths proposed a classification system that divided PRP into 5 categories according to clinical and epidemiological features and clinical course. Variants that occur in children include classical juvenile (type III), circumscribed juvenile (type IV), and atypical juvenile (type V) PRP.<sup>1</sup> In 1983, Larregue described a new variant called postinfectious PRP, based on a case series of children aged over 1 year with a history of one or more recent respiratory infections. These patients presented skin lesions that resembled those of juvenile classic PRP, but with acute onset, a good prognosis, and a low tendency to recur.<sup>2</sup> While skin lesions in postinfectious PRP may resemble other superantigen-mediated dermatoses, their histology and treatment are distinct.

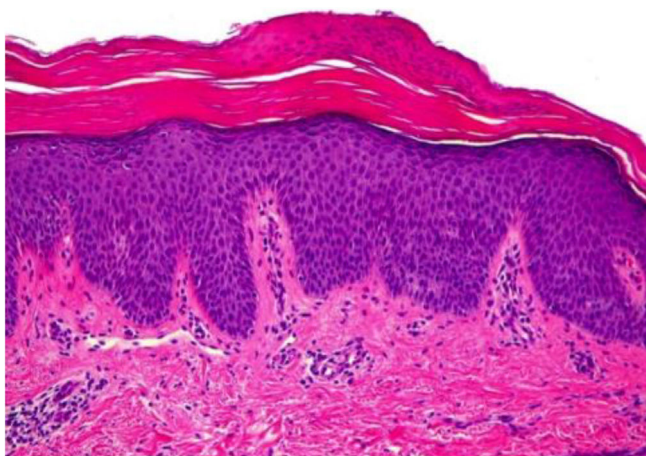
Few studies have investigated treatment efficacy in children with PRP. In patients with types III and IV, the best results have been achieved with systemic retinoids.<sup>3,4</sup> The use of oral vitamin A is controversial, as a good response has been observed only in a few patients.<sup>5</sup> Ferrándiz-Pulido et al pub-



**Figure 1** A, Initial clinical picture: multiple salmon-pink plaques on the trunk and both arms. B, Complete response after 4 weeks of topical corticosteroid treatment.

lished a series of 4 children diagnosed with postinfectious PRP, 3 of whom were treated with topical corticosteroids. Only one patient responded favorably to the 5-week treatment. The others required acitretin treatment to achieve a clinical response. The fourth patient underwent a 3-week course of topical emollients and salicylic acid, with a complete response.<sup>2</sup>

<sup>☆</sup> Please cite this article as: Zegpi-Trueba MS, Navajas-Galimany L, González S, Ramírez-Cornejo C. Pitiriasis rubra pilaris aguda postinfecciosa: gran respuesta a emolientes y a corticosteroides tópicos. *Actas Dermosifiliográficas*. 2021;112:667–668.



**Figure 2** Orthokeratosis alternating with foci of parakeratosis (hematoxylin eosin, original magnification  $\times 40$ ). The epidermis shows regular acanthosis and psoriasiform hyperplasia, and scarce inflammatory infiltrate is evident in the dermis.

In our patient, treatment with topical emollients and triamcinolone acetonide proved effective, although we cannot rule out the possibility of spontaneous resolution given the potential postinfectious etiology of the condition.

### Conflicts of Interest

The authors declare that they have no conflicts of interest.

## Reddish Papules in the Center of the Face<sup>☆</sup>



### Pápulas rojizas centofaciales

To the Editor:

A 60-year-old woman with no past history of interest visited our dermatology clinic with multiple reddish lesions on both cheeks that had appeared a year earlier. Physical examination revealed disperse telangiectases and several erythematous-pink papules in the malar regions; one of the telangiectases was larger ( $6 \times 5$  mm) and it was decided to biopsy it (Fig. 1). Histopathology revealed a dense lymphocytic infiltrate located in the papillary and reticular dermis with a mixed nodular-diffuse growth pattern and cells with the appearance of centrocytes, together with other, slightly larger cells with the appearance of centroblasts (Fig. 2). Immune staining was positive for CD10, CD20, CD79a, Bcl-2, and Bcl-6, but negative for CD3 and cyclin D1 (Fig. 2).

Furthermore, monoclonal rearrangement of the gene *IgH* was detected using PCR (polymerase chain reaction) and rearrangement of the gene *Bcl-2* was detected using FISH (fluorescence in situ hybridization). Flow cytometry was normal. An initial staging was performed using computed tomography of the chest and abdomen, and blood tests were carried out, including lactate dehydrogenase, but no evidence of systemic disease was found. The findings were thus compatible with primary cutaneous follicle center B-cell lymphoma (PCFCL), which

### References

1. Klein A, Landthaler M, Karrer S. Pityriasis rubra pilaris: a review of diagnosis and treatment. *Am J Clin Dermatol*. 2010;11:157–70.
2. Ferrándiz-Pulido C, Bartralot R, Bassas P, Bodet D, Repiso T, Aparicio G, et al. Acute postinfectious pityriasis rubra pilaris: a superantigen-mediated dermatosis. *Actas Dermosifiliogr*. 2009;100:706–9.
3. Allison DS, El-Azhary RA, Calobrisi SD, Dicken CH. Pityriasis rubra pilaris in children. *J Am Acad Dermatol*. 2002;47:386–9.
4. Yang CC, Shih IH, Lin WL, Yu YS, Chiu HC, Huang PH, et al. Juvenile pityriasis rubra pilaris: report of 28 cases in Taiwan. *J Am Acad Dermatol*. 2008;59:943–8.
5. Kan Y, Sumikawa Y, Yamashita T. Successful treatment of pityriasis rubra pilaris with oral Vitamin A in oil (Chocola A<sup>®</sup>) for an 18-month-old child. *J Dermatol*. 2015;42:1210–1.

M.S. Zegpi-Trueba,<sup>a</sup> L. Navajas-Galimany,<sup>a</sup> S. González,<sup>b</sup> C. Ramírez-Cornejo<sup>a,\*</sup>

<sup>a</sup> *Departamento de Dermatología, Facultad de Medicina, Pontificia Universidad Católica de Chile, Santiago, Chile*  
<sup>b</sup> *Dermatopatología SG, Santiago, Chile*

\*Corresponding author.

E-mail address: [caramir3@uc.cl](mailto:caramir3@uc.cl) (C. Ramírez-Cornejo).

<https://doi.org/10.1016/j.adengl.2021.05.005>  
 1578-2190/ © 2020 AEDV. Published by Elsevier España, S.L.U. This is an open access article under the CC BY-NC-ND license (<http://creativecommons.org/licenses/by-nc-nd/4.0/>).

was confirmed following absence of systemic disease after 6 months. A bone-marrow biopsy was not performed due to the painless course of this disease and to the results of the additional tests.

Treatment consisted of intralesional rituximab (anti-CD20 monoclonal antibody) on 6 occasions, with a good response (Figs. 3A and 3B). The patient subsequently developed a new erythematous papule on the side of the nose (Figs. 3C and 3D), which, together with the tendency of the patient's skin toward redness and the presence of disperse telangiectases, produced a rosaceiform appearance. Topical treatments such as metronidazole and ivermectin were therefore used. Given the lack of response, a new biopsy was taken, which revealed histopathologic findings compatible with PCFCL. The lesions were again treated with intralesional rituximab, a malar lesion and a lesion on the internal ocular surface were surgically excised, and complete remission was observed. A watch-and-wait approach was subsequently adopted despite the appearance of new lesions. The patient is currently in joint follow-up with the dermatology and hematology departments, with persistent multiple facial lesions and no extracutaneous involvement.

Primary cutaneous B-cell lymphoma (PCBL) is a B-cell lymphoma that affects the skin with no signs of extracutaneous disease on diagnosis or in the following 6 months.<sup>1</sup> According to records, the follicle center subtype (PCFCL) is the most common form of PCBL, together with primary cutaneous marginal zone B-cell lymphoma.<sup>2</sup> Both lymphomas present a painless chronic course, which leads to an approximate 5-year survival rate of  $\geq 95\%$ .<sup>1–4</sup>

Clinically, PCFCL presents firm, asymptomatic papules, plaques, or tumors, in isolation or in erythematous groups, predominantly on the head, neck, and torso.<sup>1,5–7</sup> According to the bibliography described, B-cell lymphoproliferative disorder may mimic a rosacea, although these are extremely rare cases.<sup>1,5–7</sup> In 2012, Barzilai et al<sup>5</sup> recorded 4 cases and in 2004, Seward et al<sup>7</sup> contributed 1 further case, all of which were

<sup>☆</sup> Please cite this article as: Sarriugarte Aldecoa-Otalora J, Mitxelena Eceiza J, Córdoba Iturriagagoitia A, Viguria Alegría MC. Pápulas rojizas centofaciales. *Actas Dermosifiliogr*. 2021;112:668–670.