



## IMAGES IN DERMATOLOGY

### Basal Cell Carcinoma in the Perianal Region: A Challenging Location for Diagnosis<sup>☆</sup>

#### Carcinoma basocelular perianal. Una localización de difícil diagnóstico.

A. Imbernón-Moya,<sup>\*</sup> M. Dorado-Fernández, E. Vargas-Laguna

*Servicio de Dermatología, Hospital Universitario Severo Ochoa, Leganés (Madrid), Spain*

Received 19 December 2018; accepted 22 January 2019

A 68-year-old woman with no remarkable personal or family history presented with a pruritic cutaneous lesion of 3 months' duration in the perianal region (Fig. 1). The tentative diagnosis was a boil and the patient was started on 100 mg oral doxycycline every 12 hours and topical mupirocin for 2 weeks, but showed no improvement. A pinkish-whitish plaque with a scar-like appearance was observed during skin examination. Dermoscopy showed a pink background, milia-like cysts, shiny white lines, and polymorphous vessels, including arborizing, dotted, and corkscrew vessels. Histology confirmed the presence of invasive basal cell carcinoma (BCC). Given the high-risk location, it was decided to excise the lesion using Mohs micrographic surgery. Clear margins were achieved in the first stage of surgery and the defect was closed by direct suture. During 6 months of follow-up, the patient has shown no signs of local recurrence or developed any other suspicious lesions.

Perianal BCC accounts for less than 0.08% of all cases of BCC. Tumors located in this region may display more aggressive behavior as they tend to be diagnosed late for several reasons (they are confused with inflammatory lesions, do not typically display symptoms and therefore do not prompt the patient to seek medical care, and are located in a region that is generally not examined during routine examination). Early diagnosis is essential for adequate excision with good prognosis and few complications. The main entities that should be considered in the differential diagnosis are inflammation, Bowen disease, and extramammary Paget disease. In our case, the dermoscopic findings were suggestive of but not diagnostic for BCC and helped rule out other possibilities.

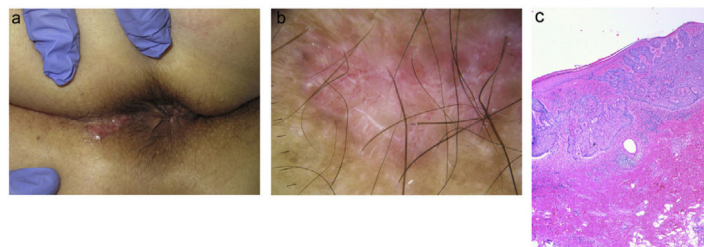


Figure 1

<sup>☆</sup> Please cite this article as: Imbernón-Moya A, Dorado-Fernández M, Vargas-Laguna E. Carcinoma basocelular perianal. Una localización de difícil diagnóstico. *Actas Dermosifiliogr.* 2021;112:268–268.

<sup>\*</sup> Corresponding author.

E-mail address: [dradrianimbernon@gmail.com](mailto:dradrianimbernon@gmail.com) (A. Imbernón-Moya).