

Infectious diseases, hormone abnormalities or fluctuations, some drugs and foods, and even neoplasias have been linked to EAC lesions. Annually recurring EAC may also involve seasonal environmental factors such as increased temperature or insect bites. A clear causal agent, however, cannot be identified in most cases (idiopathic EAC).

With regard to treatment, topical and systemic corticosteroids may alleviate the pruritus, but they cannot halt the progress of the lesions, which may involve the entire chest, back or neck. Characteristic of EPSR and annually recurring EAC is the gradual and spontaneous regression of the lesions with the arrival of cooler seasons. Long-term follow-up has recorded recurrences in the first 2-5 years, with subsequent definitive resolution.<sup>1</sup> Other publications, however, suggest a longer duration of the disease.<sup>5</sup>

Although EPSR has been described and subsequently reported in high-impact scientific journals, some authors question that it has sufficient clinical pathologic entity to be considered as an independent disease and they prefer to consider it as a peculiar variant of recurring figurate erythemas such as annually recurring EAC.

### Conflicts of Interest

The authors declare that they have no conflicts of interest.

### References

1. Song Z, Chen W, Zhong H, Ye Q, Hao F. Erythema papulosa semicircularis recidivans. *Dermatitis*. 2012;23:44–7.
2. Ríos-Martín JJ, Ferrándiz-Pulido L, Moreno-Ramírez D. Aproximación al diagnóstico dermatopatológico de las lesiones figuradas. *Actas Dermosifiliogr* [Internet]. 2011;102:316–24.
3. García Muret MP, Pujol RM, Gimenez-Arnau AM, Barranco C, Gallardo F, Alomar A. Annually recurring erythema annulare centrifugum: a distinct entity? *J Am Acad Dermatol*. 2006;54:1091–5.
4. Inoue A, Sawada Y, Ohmori S, Omoto D, Haruyama S, Yoshioka M, et al. Erythema papulosa semicircularis recidivans associated with primary pancreas B cell lymphoma. *Eur J Dermatology* [Internet]. 2016;26:306–7.
5. Rodríguez-Lomba E, Molina-López I, Baniandrés-Rodríguez O. An atypical figurate erythema with seasonal recurrences. *JAMA Dermatology* [Internet]. 2018;154:1340–1.

E. Bernia\*, C. Requena, B. Llombart

*Servicio de Dermatología, Instituto Valenciano de Oncología (IVO), Valencia, Spain*

\* Corresponding author.

E-mail address: [eduardobernia@gmail.com](mailto:eduardobernia@gmail.com) (E. Bernia).

<https://doi.org/10.1016/j.adengl.2020.10.012>  
1578-2190/ © 2020 AEDV. Published by Elsevier España, S.L.U. This is an open access article under the CC BY-NC-ND license (<http://creativecommons.org/licenses/by-nc-nd/4.0/>).

## Abdominal Pseudohernia Due to Herpes Zoster<sup>☆</sup>

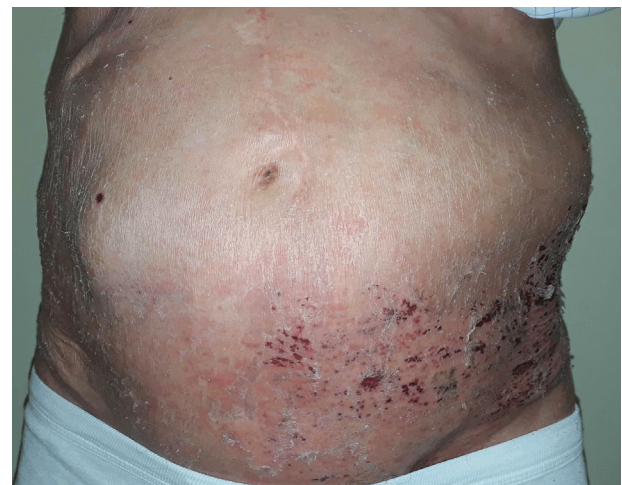

### Pseudohernia abdominal por herpes zóster

To the Editor:

After attending the emergency department of another hospital, an 84-year-old man was diagnosed with left abdominal herpes zoster (HZ). Because clinical signs had developed more than 72 hours earlier, no antiviral treatments were administered. One week later, the patient came to our outpatients due to the sudden appearance of an asymptomatic mass in the area affected by HZ. Five years earlier he had developed a rectal neoplasm that was treated with surgery and radiation therapy. Physical examination revealed hyperesthesia and lesions in the crusting phase on dermatomes T10 to T12. Painless, reducible bulging of the abdominal wall that increased with Valsalva maneuvers was evident in the area affected by HZ (Fig. 1). A midline laparotomy scar showed no signs of complication. An abdominal computed tomography scan was requested to rule out abdominal mass or hernia. The results revealed thinning of the abdominal

wall without evidence of hernia. An electroneuromyographic study revealed no alterations. Given the temporal relationship between the appearance of the rash and the protrusion, the case was oriented as abdominal pseudohernia due to HZ. After 8 months, the patient showed a complete clinical recovery (Fig. 2).



**Figure 1** Pseudohernia on the left flank coinciding with herpes zoster in the crusting phase.

<sup>☆</sup> Please cite this article as: Setó-Torrent N, Iglesias-Sancho M, Arandes-Marcocci J, Salleras Redonnet M. Pseudohernia abdominal por herpes zóster. *Actas Dermosifiliogr*. 2020;111:791–793.

While sensory alterations are one of the main neurological complications of HZ, motor nerves can also be affected, resulting in paralysis of the facial muscles, extremities, diaphragm, or abdominal muscles, in some cases with visceral involvement.<sup>1</sup>

Abdominal pseudohernia is a protrusion limited to the abdominal wall without an actual underlying defect. The first case of paralysis of the abdominal musculature caused by HZ was described in 1886 by Broadbent.<sup>2</sup> Despite the high incidence of HZ, this entity is only observed in between 0% and 2% of cases.<sup>3</sup> It manifests as abdominal distention with unilateral bulging on the affected side. The T11 dermatome is the most affected, followed by T12 and T10.<sup>4</sup> Symptoms can appear 2 to 6 weeks before the rash, but usually develop about 2 weeks after.<sup>3</sup> It has been predominantly described in elderly patients and those with hematologic neoplasms, as well as immunocompromised individuals.<sup>5</sup>

The exact underlying mechanism is not entirely clear, but it is thought to involve viral infection at the level of the anterior horn of the spinal cord as a consequence of neural spread of the varicella-zoster virus from the dorsal root ganglia.<sup>6</sup> Pathological studies<sup>3,7</sup> have demonstrated ganglion lesions combined with degeneration of the sensory and motor roots together with severe neuritis, which may explain the electrophysiological findings characteristic of the disease.

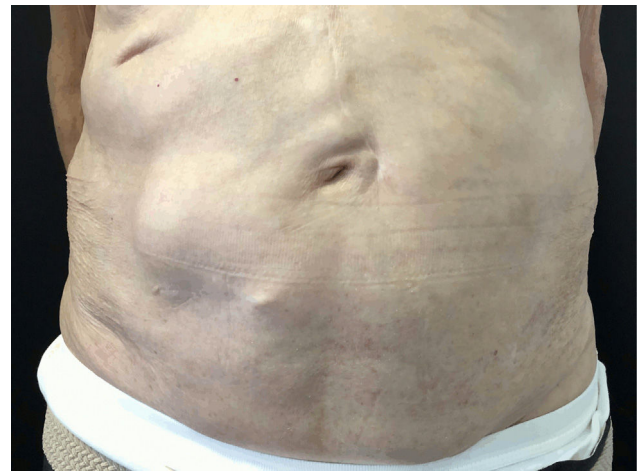Diagnosis is primarily clinical, based on temporal correlation of HZ with the appearance of abdominal distension. Physical examination may reveal decreased or absent segmental reflexes.<sup>5</sup> An electroneuromyographic study can be useful to confirm diagnosis, although alterations are observed in only 35%<sup>3,8</sup> of cases. Abdominal computed tomography shows a thinned abdominal wall and rules out the presence of an abdominal mass or hernia. Gadolinium-diethylenetriamine penta-acetic acid (DTPA) nuclear magnetic resonance imaging can help define the extent of inflammation and exclude compression of the spinal nerve roots.<sup>9</sup>

The differential diagnosis should include diseases that present with alterations in the innervation of the abdominal wall musculature and can cause pseudohernia, such as lumbar hernia, polyradiculoneuropathy, diabetic neuropathy, and syringomyelia.

Treatment is the same as for HZ, with antiviral drugs and analgesia if required. Short courses of corticosteroids<sup>8</sup> have also been used for their anti-inflammatory effects, as well as multiple vitamin preparations,<sup>3,7</sup> which can help restore damaged nerve fibers, although there is little evidence to support the use of these treatments.

The prognosis for motor weakness is usually good, with complete or near complete recovery in 55% to 75%<sup>10</sup> of cases within a period of 2 to 18 months.<sup>3</sup> The most common complication of pseudohernia is constipation,<sup>4</sup> although other complications, including paralytic ileus and voiding disorders,<sup>1</sup> have been described in 19.4%<sup>4</sup> of patients.

In conclusion, abdominal pseudohernia is a rare complication of HZ that usually has a good prognosis. Although the suspected diagnosis is clinical, it is advisable to perform a noninvasive imaging test to rule out a true hernia.



**Figure 2** Complete resolution of pseudohernia after 8 months of follow-up.

## Conflicts of interest

The authors declare no conflict of interest.

## References

1. Broadbent WH. Case of herpetic eruption in the course of branches of the brachial plexus, followed by partial paralysis in corresponding motor nerves. *BMJ*. 1866;2:460.
2. McLoughlin R, Waldron R, Brady MP. Post-herpetic abdominal wall herniation. *Postgrad Med J*. 1988;64:832–3.
3. Dobrev H, Atanassova P, Sirakov V. Postherpetic abdominal-wall pseudohernia. *Clin Exp Dermatol*. 2008;33:677–8.
4. Chernev I, Dado D. Segmental zoster abdominal paresis (zoster pseudohernia): A review of the literature. *PM&R*. 2013;5:786–90.
5. Healy C, McGreal G, Lenehan B, McDermott EW, Murphy JJ. Self-limiting abdominal wall herniation and constipation following herpes zoster infection. *QJM Mon J Assoc Physicians*. 1998;91:788–9.
6. Bashir U, Anwar MI, Tahir M. Postherpetic pseudohernia of abdominal wall: A case report. *J Pak Assoc Dermatol*. 2014;24:355–7.
7. Mancuso M, Virgili MP, Pizzanelli C, Chiari A, Geri G, Michelassi MC, et al. Abdominal pseudohernia caused by herpes zoster truncal D12 radiculoneuropathy. *Arch Neurol*. 2006;63:1327.
8. Kawajiri S, Tani M, Noda K, Fujishima K, Hattori N, Okuma Y. Segmental zoster paresis of limbs: Report of three cases and review of literature. *The Neurologist*. 2007;13:313–7.
9. Hanakawa T, Hashimoto S, Kawamura J, Nakawara M, Suenaga T, Matsuo M. Magnetic resonance imaging in a patient with segmental zoster paresis. *Neurology*. 1997;49:631–2.
10. Oliveira PD, dos Santos Filho PV, de Menezes Ettinger JEMT, Oliveira ICD. Abdominal-wall postherpetic pseudohernia. *Hernia J Hernias Abdom Wall Surg*. 2006;10:364–6, discussion 293.

N. Setó-Torrent\*, M. Iglesias-Sancho, J. Arandes-Marcocci, M. Salleras Redonnet

*Servicio de Dermatología, Hospital Universitari Sagrat Cor, Barcelona, Spain*

\*Corresponding author.

E-mail address: [nurisetorrent@gmail.com](mailto:nurisetorrent@gmail.com) (N. Setó-Torrent).

3 December 2018 28 January 2019

<https://doi.org/10.1016/j.adengl.2020.10.005>

1578-2190/ © 2020 AEDV. Published by Elsevier España, S.L.U. This is an open access article under the CC BY-NC-ND license (<http://creativecommons.org/licenses/by-nc-nd/4.0/>).

## Mucous membrane pemphigoid: When the mouth can give a clue to the diagnosis of an esophageal stenosis of unknown origin<sup>☆</sup>



### Penfigoide de mucosas: cuando la mucosa oral puede ser la clave para el diagnóstico de una estenosis esofágica de origen desconocido

Dear Editor:

Mucous membrane pemphigoid (MMP) is an uncommon heterogeneous group of autoimmune subepidermal blistering disorders which predominantly involves mucosal membranes. Diagnosis and treatment are challenging and delay may cause severe scarring and complications such as esophageal and urethral stenosis, conjunctival synechia and blindness.

An 88-year-old woman with a 9-year history of dysphagia secondary to an indeterminate esophageal stenosis, requiring several endoscopic dilatations (Fig. 1), was referred to our clinic for evaluation of oral erosions. Examination revealed erosive gingivitis, and extensive oral and genital erosions (Fig. 2). Biopsies of vulvar lesions were non-specific and direct immunofluorescence (IFD) of non-affected genital and labial mucosa were negative. Indirect immunofluorescence on salt-split skin (IIF) revealed IgG antibodies binding to the epidermal side of the blister. IIF showed IgG deposition at the basement membrane. ELISA tests were negative for anti Dg1, Dg3 and BP180 antibodies. Immunoblotting of non-affected epidermal extracts was negative for IgG: BP230, BP180, 210 kDa envoplakin, 190 kDa periplakin, Dg1 and Dg3. Immunoblotting of recombinant protein of C-terminal domain of BP180 (BP180oct) detected IgG reactivity of patient serum. A diagnosis of MMP was established and treatment with prednisone (30 mg/day) in a tapering regimen, dapsone 50 mg/day and tacrolimus in a 2 mg/liter mouth rinse formulation was initiated. Dysphagia, oral and genital erosions remitted, but the patient has developed a scarring fibrosis of the vulva with fusion of labia and urethral meatus.

Erosive esophagitis (EE) is a common finding in esophagogastroduodenoscopy (EGD) of patients with gastroesophageal reflux disease (GERD), drug-induced mucosal damage, infections, malignancies and autoimmune

disorders.<sup>1</sup> Among autoimmune disorders, a possible under-diagnosed pathology is MMP. The frequency of esophageal involvement in MMP is between 2% and 30%, and this may be an underestimation as EGD is only performed on symptomatic patients.<sup>2</sup>

In patients with MMP and esophageal lesions, a mean of another 3 mucosal areas are involved, and the oral cavity is affected in 86 % of the cases.<sup>3</sup> Dysphagia can signal esophageal involvement, although clinically it can be difficult to distinguish it from odynophagia. For all the above-mentioned reasons, performing an EGD on every newly diagnosed patient with MMP has been suggested.<sup>2,4</sup> Although, EGD is not free of complications and not always available, we agreed with other authors<sup>2-4</sup> that it should be especially indicated in symptomatic patients or patients with involvement of several mucous membranes.

The mouth is the beginning and the most accessible portion of the digestive tract, and as EGD is performed with a transnasal videogastroscope in these patients, oral exploration may be omitted. In any patient with esophageal erosions, scarring or stenosis, the oral cavity must be clinically explored. The presence of gingivitis or erosions makes examining the anogenital area, nose, throat, eyes and skin necessary in order to rule out MMP, and to evaluate the severity of the disease.

Diagnosis and treatment of MMP can be challenging. In our patient, IIF revealed an epidermal side positivity, which is compatible with bullous pemphigoid, lichen planus pemphigoides and MMP. This finding excludes the diagnosis of acquired bullous epidermolysis, P200 pemphigoid and MMP anti-laminin 332.<sup>5</sup> Finally, immunoblotting was positive for BP180oct, a very specific finding of MMP.<sup>6</sup> On the basis of clini-

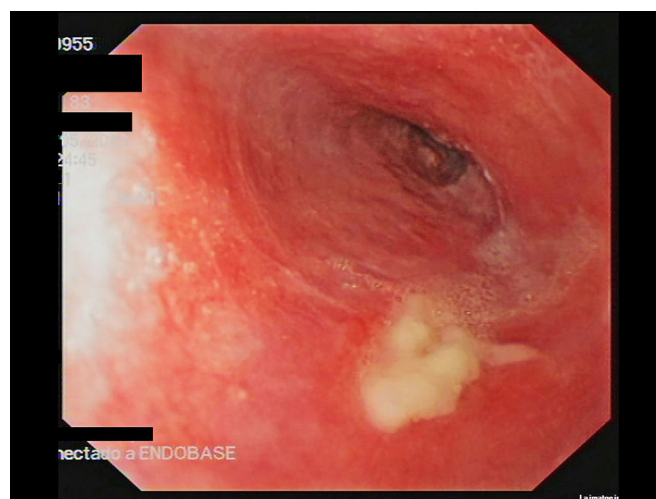


Figure 1 Esophagogastroduodenoscopy. Friable esophageal mucosa with erosions and strictures.

<sup>☆</sup> Please cite this article as: Corral-Magaña O, Morgado-Carrasco D, Fustà-Novell X, Iranzo P. Penfigoide de mucosas: cuando la mucosa oral puede ser la clave para el diagnóstico de una estenosis esofágica de origen desconocido. *Actas Dermosifiliogr.* 2020;111:793–795.