

- plastic therapy-induced flagellate dermatoses. *Dermatol Ther.* 2015;5:253–64.
5. Lee JY, Yang CC, Hsu MM. Histopathology of persistent papules and plaques in adult-onset Still's disease. *J Am Acad Dermatol.* 2005;52:1003–8.
  6. Affleck AG, Littlewood SM. Adult-onset Still's disease with atypical cutaneous features. *J Eur Acad Dermatol Venereol.* 2005;19:360–3.
  7. Narváez García FJ, Pascual M, López de Recalde M, Juárez P, Morales-Ivorra I, Notario J, et al. Adult-onset Still's disease with atypical cutaneous manifestations. *Medicine (Baltimore).* 2017;96:e6318.
  8. Nasserredine H, Fite C, Kottler D, Descamps V, Couvelard A, Marot L, et al. An atypical persistent eruption of adult-onset Still's disease with neutrophilic urticarial dermatosis-like dermal features: a case report and review of the literature. *J Cutan Pathol.* 2018;45:793–9.
  9. Brance ML, Neffen EL. Oral mucosa lesions as atypical manifestation of adult-onset Still's disease. *An Bras Dermatol.* 2018;93:271–3.
  10. Omigawa C, Hashimoto T, Hanafusa T, Namiki T, Igawa K, Yokozeki H. Generalized purpura as an atypical skin manifestation of adult-onset Still's disease in a patient with Behçet's disease. *Acta Derm Venereol.* 2018;98:452–3.

M. Pawar\*, V. Zawar, S. Kumavat

*Departamento de Dermatología, Dr. V. P. Facultad de Medicina, Hospital y Centro de Investigación, Nashik, India*

\* Corresponding author.

*E-mail address:* [manojpawar624@yahoo.com](mailto:manojpawar624@yahoo.com) (M. Pawar).

<https://doi.org/10.1016/j.adengl.2020.09.013>

1578-2190/ © 2020 Published by Elsevier España, S.L.U. on behalf of AEDV. This is an open access article under the CC BY-NC-ND license (<http://creativecommons.org/licenses/by-nc-nd/4.0/>).

## Cutaneous Polyarteritis Nodosa in a Patient with Ulcerative Colitis<sup>☆</sup>



### Poliarteritis nudosa cutánea en un paciente con colitis ulcerosa

*Dear Editor:*

Several cutaneous manifestations are occasionally observed in patients with inflammatory bowel disease (IBD); however, isolated cutaneous vasculitis is rare among those skin lesions. Both cutaneous small-vessel vasculitis and cutaneous polyarteritis nodosa (cPAN) are uncommon skin manifestations of IBD.<sup>1</sup> We present herein a case of cPAN in a patient with ulcerative colitis (UC).

A 33-year-old woman visited the dermatology clinic complaining of erythemas with tenderness on the bilateral lower extremities with numbness, which had appeared three months previously. She had been suffering from UC (pancolitis type) for 2.5 years, and had been treated with mesalazine (5-aminosalicylic acid). Intestinal conditions were well-controlled. Physical examination showed livedo racemosa with tender nodules involving the anterior and posterior aspects of both legs, abdomen, and forearms (Fig. 1). Laboratory data showed normal liver and renal function, and urinalysis was normal. Serum levels of C-reactive protein, complements, IgG, and rheumatoid factor were all within normal ranges, and antinuclear

antibody, antineutrophil cytoplasmic autoantibodies (MPO-ANCA, PR3-ANCA), anticardiolipin, and anti-β2-glycoprotein 1 IgG antibody were all negative. Cryoglobulin was not detected. A biopsy specimen showed necrotizing vasculitis in the lower dermis without affecting neighboring tissues (Fig. 2a). Higher magnification revealed a crescent fibrinoid deposition in the vessel lumen infiltrated by neutrophils and lymphocytes (Fig. 2b). Perivascular inflammation was localized at the dermal-subcutis junction. Elastica van Gieson stain revealed partially disrupted internal elastic lamina (Fig. 2c). The patient was treated with low-dose prednisolone (up to 30 mg/day (0.6 mg/kg)), sarpogrelate hydrochloride (300 mg/day), and tocopherol nicotinate (300 mg/day); however, the numbness was resistant to therapy. Mini-pulse therapy (methylprednisolone 500 mg/day for 3 consecutive days) was effective for her numbness, which, however, relapsed after the discontinuation of medication because of pregnancy. Antiplatelet agents and vitamin E were re-started after delivery; however, she refused oral steroid therapy. Her numbness still remains.

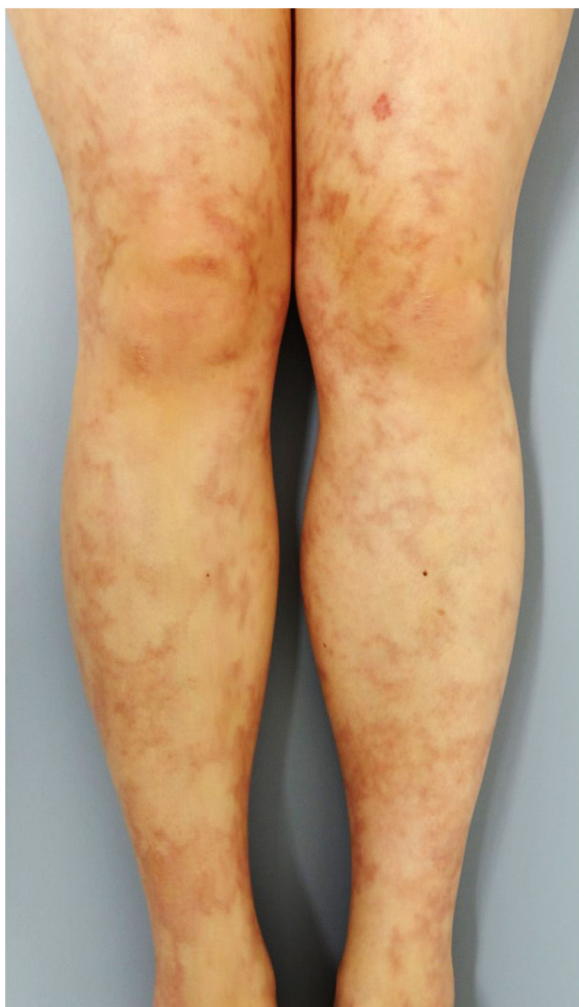The presented case developed small-sized arteritis (150 μm in diameter) at the dermo-subcutaneous junction. Elastica van Gieson stain revealed the arteritis, and vasculitis did not involve venous vessels. ANCA was negative, and detailed examination of the nose, respiratory tract, kidney and lung denied granulomatosis with polyangiitis and microscopic polyangiitis. Several triggers such as viral infection and drugs, or systemic diseases are occasionally associated with cPAN. Leukocytoclastic vasculitis associated with IBD is suggested to be caused by circulating immune complex.<sup>2,3</sup> Only several cases of cPAN associated with IBD have been reported to date; however, as compared with Crohn's disease, cases of UC are rarely reported. The rea-

<sup>☆</sup> Please cite this article as: Hiraiwa T, Yamamoto T. Poliarteritis nudosa cutánea en un paciente con colitis ulcerosa. *Actas Dermosifiliogr.* 2020;111:797–799.

**Table 1** Cases of coexistence with cPAN and UC.

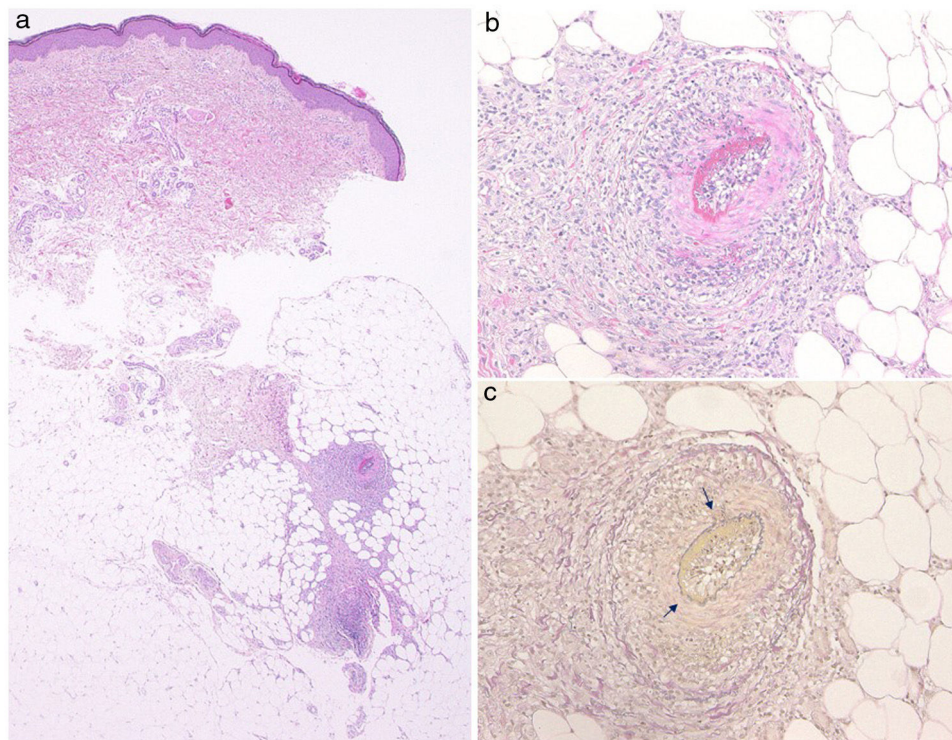
Case	Age/sex	Duration between cPAN and UC	Arthralgia/Arthritis	Myalgia	Peripheral neuropathy	Treatment	Reference
1	48/M	19 years	+	+	-	PSL, CPA	4
2	69/F	6 years	+	+	-	PSL, CPA	5
3	9/F	10 months	+	-	-	PSL	6
4	26/F	9 years	-	-	-	PSL, MTX, AZA, MMF	1
5	33/F	2.5 years	-	-	+	PSL, vasodilators	present case

PSL: prednisolone, CPA; cyclophosphamide, MTX; methotrexate, AZA azathioprine, MMF; mycophenolate mofetil.



**Figure 1** Infiltrative brownish erythema and livedo racemosa on the bilateral lower legs.

son why cases of UC are significantly fewer as compared with those of Crohn's disease is currently unknown. To our knowledge, only five cases of UC have been reported to coexist with cPAN including the present case<sup>1,4-6</sup> (Table 1). The patients consisted of one male and four females. All of the patients except one were diagnosed with UC prior to the onset of cPAN, and the interval between the diagnoses of UC and cPAN varied between 10 months and 19 years. Cutaneous manifestations presented with macular rash, erythematous nodules, and livedo racemosa. Other systemic symptoms were arthritis/arthralgia (n=3), myalgia (n=2), and peripheral neuropathy (n=1). By contrast, cPAN did not develop in parallel with worsening of intestinal conditions. The patients were treated with methylprednisolone pulse therapy, oral prednisolone, immunosuppressant (cyclophosphamide, methotrexate, azathioprine, mycophenolate mofetil), vasodilators, and antiplatelet agents. During the follow-up period, one case relapsed.<sup>4</sup> In the present case, we could follow our patient for over four years, and her numbness did not perfectly disappear. The shared pathogenesis of both disorders has been speculated such as abnormal immune response to some specific pathogen, an immune complex etiology, or hypercoagulable states; however, the precise mechanism remains uncertain because the number of reported cases of the association of cPAN and UC is limited. Nevertheless, it should be kept in mind that IBD is a rare systemic disease in patients with cPAN. Moreover, clinicians should become aware of cutaneous vasculitis in patients with IBD, in addition to pyoderma gangrenosum or erythema nodosum.



**Figure 2** (a) Histological features showing necrotizing vasculitis in the subcutis. (b) Higher magnification revealed subintimal fibrinoid necrosis. (c) Partially disrupted internal elastic lamina (arrow) (Elastica van Gieson stain).

## References

1. Sy A, Khalidi N, Dehghan N, Barra L, Carette S, Cuthbertson D, et al. Vasculitis in patients with inflammatory bowel diseases: a study of 32 patients and systematic review of the literature. *Semin Arthritis Rheum.* 2016;45:475–82.
2. Huang BL, Chandra S, Shih DQ. Skin manifestations of inflammatory bowel disease. *Front Physiol.* 2012;3:13.
3. Díaz-Pérez J, De Lagrán ZM, Díaz-Ramón JL, Winkelmann RK. Cutaneous polyarteritis nodosa. *Semin Cutan Med Surg.* 2007;26:77–86.
4. Chiu G, Rajapakse CN. Cutaneous polyarteritis nodosa and ulcerative colitis. *J Rheumatol.* 1991;18:769–70.
5. Matsumura Y, Mizuno K, Okamoto H, Imamura S. A case of cutaneous polyarteritis nodosa associated with ulcerative colitis. *Br J Dermatol.* 2000;142:561–2.
6. Volk DM, Owen LG. Cutaneous polyarteritis nodosa in a patient with ulcerative colitis. *J Pediatr Gastroenterol Nutr.* 1986;5:970–2.

T. Hiraiwa, T. Yamamoto\*

*Departamento de Dermatología, Universidad de Medicina de Fukushima, Fukushima, Japan*

\* Corresponding author.

*E-mail address:* toyamade@fmu.ac.jp (T. Yamamoto).

<https://doi.org/10.1016/j.adengl.2020.09.012>

1578-2190/ © 2020 AEDV. Published by Elsevier España, S.L.U. This is an open access article under the CC BY-NC-ND license (<http://creativecommons.org/licenses/by-nc-nd/4.0/>).