

IMAGES IN DERMATOLOGY

Diagnosis of Scabies Confirmed With Confocal Microscopy[☆]



Confirmación diagnóstica de escabiosis mediante microscopia confocal

X. Fustà-Novell, D. Morgado-Carrasco, S. Puig*

Servicio de Dermatología, Hospital Clínic de Barcelona, Universitat de Barcelona, Barcelona, Spain

A 23-year-old woman with a history of systemic erythematous lupus, who was undergoing antimalarial treatment visited our department with generalized pruritis that had appeared 2 weeks earlier; the pruritis was initially attributed to the underlying disease. As well as the lupus skin

lesions, the physical examination revealed multiple excoriations and mild interdigital lesions compatible with mite furrows. Confocal microscopy (VivaScope® 3000) of one of the interdigital lesions was performed (Fig. 1) and revealed oval eggs in a parallel formation, following the path of

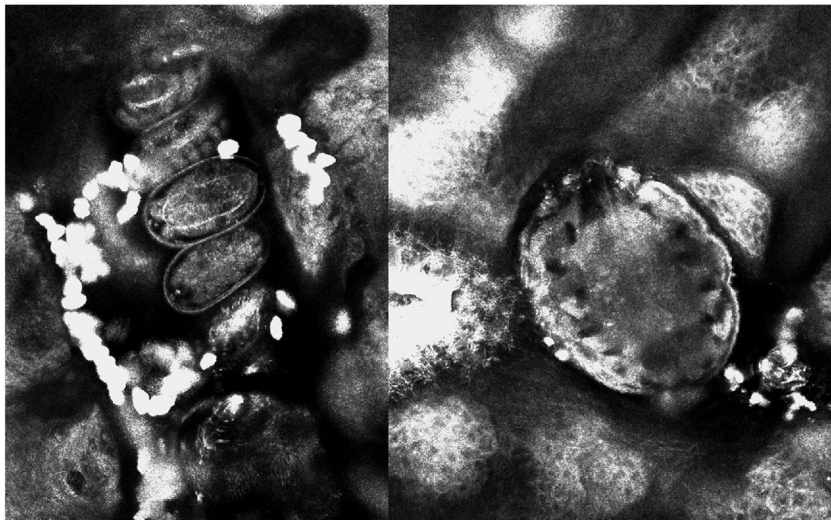


Figure 1

[☆] Please cite this article as: Fustà-Novell X, Morgado-Carrasco D, Puig S. Confirmación diagnóstica de escabiosis mediante microscopia confocal. Actas Dermosifiliogr. 2020;111:263–264.

* Corresponding author.

E-mail address: spuig@clinic.ub.es (S. Puig).

the furrow, and numerous hyper-refractile round structures, corresponding to feces. A *Sarcoptes scabiei* mite was also seen at the end of the furrow. The patient was cured of scabies after 2 applications of 5% topical permethrin.

Confocal microscopy has been shown to be useful in many infectious skin diseases, as it allows for rapid, noninvasive confirmation of diagnosis. In scabies, it makes it possible

to observe the mite, the eggs, and the feces in real time, without the need to perform a Müller test. This technique also makes it possible to monitor treatment response, as active infection indicators, such as eggs in the furrows and peristaltic movement in the digestive tract of the mite can be observed.