



ACTAS Derma-Sifiliográficas

Full English text available at
www.actasdermo.org



REVIEW

Systematic Review of Light-Based Treatments for Hidradenitis Suppurativa[☆]



T. Gracia Cazaña,^{a,*} L.V. Berdel Díaz,^{b,*} J.I. Martín Sánchez,^c
I. Querol Nasarre,^b Y. Gilaberte^d

^a Unidad de Dermatología, Hospital de Barbastro, Barbastro, Huesca, Spain

^b Departamento de Medicina, Psiquiatría y Dermatología, Facultad de Medicina, Universidad de Zaragoza, Zaragoza, Spain

^c Decisiones Basadas en la Evidencia, Instituto Aragonés de Ciencias de la Salud, Zaragoza, Spain

^d Servicio de Dermatología, Hospital Universitario Miguel Servet, IIS Aragón, Zaragoza, Spain

Received 17 March 2019; accepted 22 April 2019

Available online 14 February 2020

KEYWORDS

Hidradenitis suppurativa;
Photodynamic therapy;
Laser;
Intense pulsed light

Abstract Treatment options for hidradenitis suppurativa include light-based therapy. This systematic review aimed to update our understanding of the efficacy, effectiveness and safety of these treatments for hidradenitis suppurativa by evaluating the literature published since the 2015 Cochrane review on this topic. We conducted an electronic search of the following databases: MEDLINE, EMBASE, University of York Centre for Reviews and Dissemination database, Cochrane Database of Systematic Reviews, Cochrane Skin Group Specialised Skin Register, University of Nottingham's Centre of Evidence Based Dermatology database, and TESEO. The systematic review included 6 case series, 3 systematic reviews, and 2 clinical trials on the use of conventional and intralesional photodynamic therapy, intense pulsed light therapy, and Nd:YAG, carbon dioxide, and diode laser therapy for hidradenitis suppurativa in 248 patients. © 2019 AEDV. Published by Elsevier España, S.L.U. This is an open access article under the CC BY-NC-ND license (<http://creativecommons.org/licenses/by-nc-nd/4.0/>).

PALABRAS CLAVE

Hidradenitis suppurativa;
Terapia fotodinámica;
Láser;
Luz intensa pulsada

Revisión sistemática de las terapias con luz en el tratamiento de la hidradenitis suppurativa

Resumen La terapia con luz es una alternativa en el tratamiento de la hidradenitis suppurativa (HS). El objetivo fue evaluar la eficacia, efectividad y seguridad de las distintas modalidades de terapia con luz en la HS, mediante una revisión sistemática actualizando la realizada en 2015 procedente de Cochrane Library. Se identificaron los estudios mediante una búsqueda electrónica en las bases de datos: MEDLINE, EMBASE, Universidad de York, Cochrane Database of Systematic Reviews, Cochrane Skin Group, Centre of Evidence based dermatology de la

[☆] Please cite this article as: Gracia Cazaña T, et al. Revisión sistemática de las terapias con luz en el tratamiento de la hidrosadenitis suppurativa. Actas Dermosifiliogr. 2020;111:89–106.

* Corresponding author.

E-mail address: tamgracaz@gmail.com (T. Gracia Cazaña).

Universidad de Nottingham, TESEO finalmente se incluyeron 6 series de casos y 3 revisiones sistemáticas y 2 ensayos clínicos de pacientes tratados con terapia fotodinámica convencional o intralesional, láser Nd:YAG, CO₂ o diodo y luz intensa pulsada, con un total de 248 pacientes tratados.

© 2019 AEDV. Publicado por Elsevier España, S.L.U. Este es un artículo Open Access bajo la licencia CC BY-NC-ND (<http://creativecommons.org/licenses/by-nc-nd/4.0/>).

Introduction

Hidradenitis suppurativa (HS) is a chronic, debilitating inflammatory disease of hair follicles and their associated sebaceous glands. HS usually appears after puberty. Underlying the condition is immune dysregulation in a genetically predisposed individual.¹ The general population prevalence, which ranges from 0.1% to 1%, is higher in the second and third decades of life and in women.² Smoking, obesity, hormonal imbalance, and stress from friction or shaving can trigger or aggravate HS.³

Nodules, abscesses, suppurative fistulous tracts, and scarring in skin folds (mainly the armpits, groin, and anogenital regions) are the most common presentations.⁴ The main symptoms are pain, burning or a local sensation of heat; pruritus; and hyperhidrosis. These manifestations have a negative impact on quality of life.⁵

The management of HS is complex and requires a multi-disciplinary approach.⁶ Light-based treatments have been used experimentally in recent years. Photodynamic therapy (PDT) involves applying a photosensitizer that produces reactive oxygen species in a process that leads to cellular destruction. The hypothesized benefit of PDT in HS is based on a direct cytotoxic effect on biofilm bacteria and sebaceous glands as well as on immunomodulation.¹ When a photosensitizer is applied topically to HS lesions, accumulation occurs more easily than in normal skin because openings and fistulas facilitate penetration.⁷ Lesions improve with light activation. Light at a wavelength of 630 nm is sufficient for activating 5-aminolevulinic acid (ALA) and methylene blue (MB), which are 2 of the photosensitizers used.⁸ Topical PDT has advantages that make it an attractive alternative therapy for treating multiple lesions simultaneously; it is minimally invasive, has few adverse effects, and is well tolerated.⁹

Intense pulsed light (IPL) therapy uses a broad spectrum, high energy, noncoherent light. The underlying principle is photon absorption by endogen or exogen chromophores. The transfer of energy to target cells (in HA, the occluded hair follicle unit) generates heat, destroying the lesion in a process termed selective photothermolysis.¹⁰ IPL also has an antimicrobial effect due to the activation of bacterial porphyrins, which generates reactive oxygen species and leads to cell death.¹¹

Nd:YAG, carbon dioxide (CO₂), alexandrite, and diode laser therapies have also been used to treat HS. The aim of these treatments is to reduce the number of hair follicles in areas where HS lesions tend to develop.¹²

This systematic review aimed to update our understanding of the efficacy and safety of the various modalities

of light-based therapy applied in HS. We considered both conventional PDT and intralesional and laser treatments. However, we did not compare them, given that their mechanisms of action differ and publications are few.

Material and Methods

Literature Search Strategy

We searched for articles on light-based therapies used alone or with a photosensitizer (PDT) to treat HS. Articles had to be published between August 2015 and March 1, 2019. Additional limiters were set to select studies in humans that were published in either Spanish or English. We started the search with August 2015 because a systematic review in the Cochrane Library was updated at that time. Our intention was to update that review with the results of more recent studies.

We also searched backwards from the reference lists to identify any cited articles meeting our inclusion criteria.

The following databases were used: MEDLINE (through PubMed), EMBASE, the Centre of Reviews and Dissemination (University of York), the Cochrane Library (in the Cochrane Database of Systematic Reviews), the Cochrane Skin Group, the Centre of Evidence Based Dermatology (University of Nottingham), and TESEO (the Andalusian database of PhD theses). The following trial registries were also consulted: ClinicalTrials.gov, reec.aemps.es, and Clinicaltrialsregister.eu.

Finally, the PROSPERO register was searched for systematic reviews on HS. We specified reviews that included light-based therapies.

Search terms were chosen from the list of Medical Subject Headings (English) and its equivalent in Spanish (Descriptores en Ciencias de la Salud), as follows: photochemotherapy, photodynamic therapy, hidradenitis suppurativa, suppurative hidradenitis, light, lasers, laser therapy, intense pulsed light therapy.

Article inclusion criteria were as follows:

- Type of study: randomized controlled clinical trials (RCTs), systematic reviews, observational studies with a control group, and observational studies without a control group (case series)
- Population: adults with HS regardless of sex, ethnicity, comorbidity, or prior treatment
- Limiter: inclusion of patients whose HS was treated with PDT (using any type of laser or other light source)
- Limiter: publication in Spanish or English

Article exclusion criteria were as follows:

- Publication outside the time frame
- Studies not using accepted, validated HS evaluation tools (eg, the Hidradenitis Suppurativa Clinical Response criterion, the modified Sartorius score, and/or the Physician Global Assessment [PGA] of HS)
- Case series with fewer than 5 patients
- Editorials and narrative reviews

Data Management, Extraction and Synthesis, and Analysis of Research Design Quality

Search results were downloaded with Mendeley reference management software, with titles and abstracts in separate fields. All duplicate, discarded, and selected references were recorded (Fig. 1). The literature searchers were not blinded to authors' names or institution or the publishing journal.

The scale of Jadad et al¹³ was used to evaluate RCTs. Critical analysis was based on the CONSORT guidelines (Consolidated Standards for Reporting Clinical Trials).¹⁴ The tool of the Basque Office for Health Technology Assessment (OSTEBA, its Spanish acronym)¹⁵ was used to assess the quality of evidence afforded by several types of studies and build a table synthesizing the results.

Results

Included and Excluded Studies

Of the 199 studies found, we excluded 164 after removing duplicates and assessing the titles and abstracts. We evaluated 35 full texts, excluding 24 that did not meet the inclusion criteria. Some did not have 5 patients.^{9,12,16–37} (See Appendix B, supplementary material.) Because few clinical trials and systematic reviews were found, we included case series even though their evaluation of efficacy and effectiveness is limited.

Thus, we evaluated 6 case series (5 prospective and 1 retrospective). The evidence level was low in 4 of the series and moderate in 2 of them.

Most studies were carried out in Europe (Spain, the United Kingdom, France, and Italy), the United States, and Egypt. The remaining inclusions were 2 moderate-quality RCTs and 3 high-quality systematic reviews. The reviews included 4 trials and 5 case series on light-based treatments and are analyzed in depth in the present systematic review: Fadel and Tawfik,³⁸ Highton et al,¹¹ Tierney et al,³⁹ Calzavara-Pinton et al,⁴⁰ Schweiger et al,⁴¹ Sotiriou et al,⁴² Mahmoud et al,⁴³ Madan et al,⁴⁴ and Xu et al.⁴⁵

Tables 1–3 summarize the studies' periods of follow-up, numbers of patients and losses, population characteristics and interventions. One relevant study² was found in a backward citation search of references.

Sample Size

The number of participants in the included studies ranged widely. The maximum was 38⁴⁶ and the minimum was 5,^{2,42} for a total of 248 patients (mean, 15.5 patients).

Participants

All the studies included men and women older than 18 years with a clinical diagnosis of HS.

One study included only Hurley stage 1 patients (Zerbinati et al⁴⁷) and 1 included only Hurley stage 2 patients (Mahmoud et al⁴³). Two studies included both Hurley 1 and 2 stages (Abdel Azim et al⁴⁸ and Fabbrocini et al⁴⁹). Six studies required moderately severe HS (Hurley stages 2 or 3) at baseline (Andino Navarrete et al,² Agut-Busquet et al,¹ Highton et al,¹¹ Tierney et al,³⁹ Xu et al,⁴⁵ and Sotiriou et al⁴²). One study included any stage of severity (stages 1, 2, or 3) (Suárez Valladares et al⁵⁰). Finally, 5 studies did not specify stage (Valladares-Narganes et al,⁵¹ Fadel and Tawfik,³⁸ Calzavara-Pinton et al,⁴⁰ Madan et al,⁴⁴ and Schweiger et al⁴¹).

Study Designs

We included 3 systematic reviews for this systematic update (Ingram et al,³ John et al,⁵² and Robert et al⁵³) and 2 clinical trials (Fadel and Tawfik³⁸ and Abdel Azim et al⁴⁸). The remaining studies were case series.

The systematic review of Ingram et al³ included 3 RCTs comparing topical PDT, IPL and Nd:YAG laser therapy.^{11,38,39} Fadel and Tawfik³⁸ used an active comparator in the control group. Controls were untreated in Highton et al,¹¹ whereas Tierney et al³⁹ applied 1% clindamycin cream in the control group. The systematic review of John et al⁵² included 22 studies. Three provided high-quality evidence (and were also included by Ingram et al). The only additional inclusion that met our criteria was that of Xu et al,⁴⁵ which assessed Nd:YAG laser treatment. The most up-to-date systematic review was by Robert et al,⁵³ who included 64 articles about the nonsurgical treatment of HS (with medications or light therapies). Studies of light-based treatments that were not included in the aforementioned reviews were those of Calzavara-Pinton et al⁴⁰ (PDT with methyl aminolevulinic acid [MAL]) and Schweiger et al⁴¹ and Sotiriou et al⁴² (PDT with ALA). This third systematic review also included two case series of patients treated with Nd:YAG laser (Mahmoud et al⁴³) and CO₂ laser (Madan et al⁴⁴).

Only 2 RCTs were retrieved. One was by Fadel and Tawfik,³⁸ which was found by backwards searching of citations as described above. The other was by Abdel Azim et al,⁴⁸ which evaluated a combined treatment with CO₂ laser followed by Nd:YAG laser.

One of the case series we included studied the use of PDT with 20% ALA as the photosensitizer and 635-nm laser (Andino Navarrete et al²). Three studies analyzed intraleisional PDT. Two used ALA at concentrations of 5% and 1% and a 630-nm laser light source.^{50,51} The third used MB and a 635-nm light-emitting diode (LED) lamp (Aktelite).¹

Table 1 Summary of Studies Included in Systematic Reviews That Used PDT Alone or in Combination With Surgery to Treat HS^{a,b}

Reference, y	Study Design, Aim and Period	Study Population	Intervention and Follow-up	Results	Conclusions	Comments	Quality of Evidence
Andino Navarrete et al, ² 2014	<i>Design:</i> prospective case series <i>Objective:</i> To assess the efficacy (Sartorius, DLQI) and safety of PDT + ALA and 635-nm light treatment of moderate to severe HS	<i>No. of patients:</i> 5 <i>Characteristics:</i> HS type 2 or Hurley stage 3; 4 armpit lesions, bilateral + 1 pubic; 1 man, 4 women; Mean age, 26 (5) y; Mean time since onset, 4 (1) y	20% ALA solution for 1.5 h; light (635 nm, 37 J/cm ² , 70 mW/cm ²) per session Minimum 4 sessions spaced 1–2 wk <i>Follow-up:</i> 4 and 8 wk <i>Losses:</i> 0	Significantly improved severity, DLQI, and VAS scores at 8 wk Mean Sartorius decrease of 35 (5) to 18 (8) points DLQI decrease, 21 points after 4 sessions, sustained at 8 wk VAS pretreatment, 3; decrease (0–1) at 4 and 8 wk, all patients Only adverse effect, burning on irradiation (2 patients)	Treatment with topical 20% ALA and 635-nm light could be effective for refractory HS, decreasing severity and improving QoL.	Small series, limiting external validity and extrapolation	Low
Fadel and Tawfik, ³⁸ 2015	<i>Design:</i> single-blind RCT <i>Objectives:</i> To assess the efficacy and safety of MB niosome gel as photosensitizer in IPL treatment of HS <i>Study period:</i> 6 mo (month and year not specified)	<i>No. of patients:</i> 17, intraindividual (contralateral control); 6 exclusions; 11 cases analyzed. <i>Characteristics:</i> 7 women, 4 men; mean age 27.1 y (range, 17–35 y). Lesions: both armpits (4); multiple gluteal (3); groin (2); under breasts (1). No topical or systemic treatment 2 weeks before enrollment.	<i>Intervention side:</i> PDT with topical 0.01% MB gel + IPL (630 nm, 20 ms, 25 J) every 2 wk 2 sessions/mo up to 6 mo <i>Control side:</i> PDT with placebo topical MB-free gel + IPL (630 nm, 20 ms, 25 J/cm ²) every 2 wk <i>Follow-up:</i> 1, 3, and 6 mo after treatments <i>Losses after randomization:</i> 0	PDT with topical 0.01% MB gel + IPL was superior to placebo gel; reduction of Sartorius score by 77.3% and 44.1%, respectively. Mean HS-LASI improvement was significant in both groups: active treatment, 77.3% (18.86%); vs placebo gel, 44.1% (28.19%) Similar adverse effects (pain, erythema, hyperpigmentation); no effect of treatment site or disease stage <i>Adverse effects:</i> 0	IPL (630 nm) with this photosensitizer (MB) is effective. MB in niosome formulation enhances dermal penetration. Hair follicle destruction was also attributed to 630-nm λ ray.	Limited by small sample size and short follow-up period. Intraindividual RCTs with more patients and longer follow-up are needed. RCTs with comparators (medical and surgical treatments) are also needed.	Moderate

Table 1 (Continued)

Reference, y	Study Design, Aim and Period	Study Population	Intervention and Follow-up	Results	Conclusions	Comments	Quality of Evidence
Ingram et al, ³ 2015	<i>Design:</i> systematic review of RCTs <i>Objective:</i> To evaluate the effects of interventions for HS in persons of any age <i>Period searched:</i> 1983–2015	Any person (any sex, age, or ethnicity) with a clinical diagnosis of HS made by a physician and based on a standard definition of the disease	<i>Interventions:</i> More than 40 interventions for HS were included, though evidence was lacking for many. Interventions grouped as pharmacologic, surgical, and other. 3 trials: <i>Fadel and Tawfik,³⁸ 2015</i> Intervention 1: PDT with topical 0.01% MG gel + IPL (630 nm, 20 ms, 25 J/cm ²) every 2 wk Intervention 2: PDT with placebo gel + IPL (630 nm, 20 ms, 25 J/cm ²) every 2 wk, 2 sessions/mo up to 6 mo <i>Highton et al,¹¹ 2011</i> randomized sides, 1 untreated control side and 1 treated with IPL, twice weekly for 4 wk (420 nm, 7–10 J/cm ² a 50 ms) <i>Tierney et al,³⁹ 2009</i> Left and right sides of the same anatomical structure received 1 of the following treatments: - 10% benzoyl peroxide wash and 1% clindamycin in gel or lotion (frequency not indicated). - 4 Nd:YAG laser treatments monthly and topical 10% benzoyl peroxide and 1% clindamycin	<i>No. of studies and patients:</i> 12 trials with 615 patients Median, 27 participants; mean duration of treatment, 16 wk. Included studies were done between 1983 and 2015. <i>Effect size:</i> The 3 trials of laser or other light-based treatments were judged to offer a low level of evidence because of lack of precision and adequate blinding. <i>Fadel and Tawfik,³⁸ 2015</i> PDT with topical 0.01% MB gel + IPL was superior to placebo MB gel + IPL; Sartorius score fell by 77.3% and 44.1%, respectively <i>Highton et al,¹¹ 2011</i> Significant benefit from IPL in 18 patients: mean Sartorius score reduction of 12% immediately after therapy, 10% at 3 months, 10% at 6 months, and 3% at 12 months. No comparator. Patients assessed satisfaction on an unvalidated Likert scale. <i>Tierney et al,³⁹ 2009</i> 17 patients, 4 Nd: YAG laser treatments at monthly intervals on 1 side of the body in 25 regions with lesions. Significantly improved Sartorius scores in treated armpits. A 65.3% reduction in HS severity at 3 mo overall. By locations: 73.4% groin, 62% armpits, 53.1% under breasts.	Studies of Nd:YAG laser, IPL, and topical PDT treatments were of poor quality because of lack of blinding and absence of placebo comparison.		High

Table 1 (Continued)

Reference, y	Study Design, Aim and Period	Study Population	Intervention and Follow-up	Results	Conclusions	Comments	Quality of Evidence
John et al, ⁵² 2016	<p><i>Design:</i> systematic review of RCTs and nonrandomized trials, other systematic reviews, case-control cohort studies, case series, and expert opinion</p> <p><i>Objective:</i> To evaluate the effects of laser treatment of HS in persons of all ages</p> <p><i>Period searched:</i> 1987–April 2016</p>	Any individual regardless of sex, age, or ethnicity with a diagnosis of HS treated by any type of laser	<p><i>Interventions:</i> 47 studies found; 22 analyzed after applying inclusion and exclusion criteria</p> <p>Two studies provided grade A evidence (Jadad scale) and 1 provided grade B evidence. Laser therapy was assessed in 3 studies:</p> <p>Higher quality evidence (grade A, Jadad) from Highton et al,¹¹ and Tierney et al,³⁹ both included in the systematic review of Ingram et al³ (above).</p> <p>Xu et al⁴⁵ provided grade B evidence (Jadad).</p> <p>19 patients with Hurley stage 2 HS treated with long-wave Nd:YAG laser (1064 nm) twice monthly</p>	<p><i>No. of studies and patients:</i> 22 studies, 2 with grade A evidence, 1 with grade B, and the rest with grade C (very low)</p> <p>In total, 59 patients were treated in grade A or B studies. The included studies were done between 1987 and 2016.</p> <p><i>Effect size:</i> grade A evidence assigned to the trials of Highton et al¹¹ and Tierney et al,³⁹ as explained in the entry for the inclusions of the systematic review of Ingram et al.³</p> <p>Xu et al,⁴⁵ 2011, grade B. The percent change in Sartorius score after 2 mo of treatment was 31.6% ($P = .001$) on average for all lesion sites; 24.4% ($P = .008$) for armpits and 36.8% for groin ($P = .001$). But on histology 3 patients still had inflammation, and the percent changes were not clinically significant.</p>	The conclusion was that there was moderate support for the efficacy long-pulse Nd:YAG laser and IPL in HS and for reducing recurrence by means of hair follicle destruction; and limited evidence for CO ₂ laser.	Large RCTs, preferably multicenter ones, are needed to standardize assessment techniques and assess efficacy.	High

Table 1 (Continued)

Reference, y	Study Design, Aim and Period	Study Population	Intervention and Follow-up	Results	Conclusions	Comments	Quality of Evidence
Robert et al, ⁵³ 2017	<i>Design:</i> systematic review of RCTs and nonrandomized trials, other systematic reviews, case-control cohort studies, case series, and expert opinion <i>Objective:</i> To summarize and analyze research on current nonsurgical techniques for treating HS <i>Period searched:</i> January 2005–September 2015	<i>Included:</i> all original research articles on nonsurgical HS treatments (RCTs, prospective or retrospective observational studies, and case series of at least 4 patients) <i>Excluded:</i> single case studies, narrative reviews, discussions, opinion articles, research letters, and editorials	<i>Interventions:</i> 64 included articles. Evidence level generally low; most were retrospective observational studies. Biological treatments (44%), PDT or other phototherapies (16%), antibiotic therapy (11%), laser (8%), retinoids (6%), and other immunosuppressant therapies. 10 articles on PDT: 4 have already been mentioned elsewhere in our review (Fadel and Tawfik, ³⁸ Valladares-Narganes et al, ⁵¹ Andino Navarrete et al, ² and Highton et al ¹¹). After applying our inclusion and exclusion criteria, we evaluated the following: <i>Calzavara-Pinton et al,</i> ⁴⁰ 2013, treated 6 patients (no Hurley stage reported) with MAL-PTD (red light, 635 nm) every 2 wk for 4 wk <i>Schweiger et al,</i> ⁴¹ 2011, treated 12 patients with ALA-PTD (IPL or blue light), weekly for 4 wk <i>Sotiriou et al,</i> ⁴² 2009, treated 5 patients (Hurley stage 2 or higher with 20% ALA and red light (570–670 nm) 3 h later; 4 sessions at 15-d intervals; assessment with VAS, Sartorius score and DLQI Laser was used in 5 studies. We excluded 2 reports of <5 patients or with nonvalidated assessment tools and Mikkelsen et al,³⁵ a retrospective series that was not relevant (only evaluating long-term recurrence after CO₂ laser). <i>Mahmoud et al,</i> ⁴³ 2010, treated 22 patients (Hurley stage 2) with 4 sessions of long-pulse Nd:YAG laser monthly for 4 mo; follow-up, 6 mo. <i>Madan et al,</i> ⁴⁴ 2008, treated 9 medically and surgically refractory cases of HS with CO ₂ (1 session, follow-up at 12 mo).	<i>No. of studies, patients and effect sizes:</i> <i>Calzavara-Pinton et al,</i> ⁴⁰ 2013, assessed response by PGA. Response was >75% in 33% of patients, moderate in half, and <50% in 1. <i>Schweiger et al,</i> ⁴¹ 2011, saw a Sartorius score reduction of 50.8% at 4 wk and 29.9% at 8 wk. Mean DLQI scores were 17.3 at baseline and 13.1 at 4 wk. Tolerance was better with blue light than IPL. <i>Sotiriou et al,</i> ⁴² 2009, reported that mean Sartorius scores went from 18.8 at baseline to 17.2 on treated sides at the first follow-up visit. Mean VAS evaluations of disease activity/pain went from 2.4 to 2.1. DLQI scores fell by 6.4%. <i>Mahmoud et al,</i> ⁴³ 2010, measured the effect of Nd:YAG laser in 22 patients with the Sartorius score, reporting a 72% reduction. <i>Madan et al,</i> ⁴⁴ 2008, reported the PGA of the effect; 7 out of 9 patients had complete remission and expressed high satisfaction.	No nonsurgical treatment leads to long-term remission. The authors emphasized the need for surgery in refractory and debilitating cases.	Low quality of evidence. Heterogeneous methods of assessment, scarcely comparable. Few RCTs; most studies are of retrospective cohorts	High

Abbreviations: ALA, 5-aminolevulinic acid; CO₂, carbon dioxide; DLQI, Dermatology Life Quality Index; HS, hidradenitis suppurativa; HS-LASI, HS lesion, area and severity index; IPL, intense pulsed light; MAL, methyl aminolevulinate; MB, methylene blue; Nd:YAG, neodymium and neodymium:yttrium aluminum garnet; PDT, photodynamic therapy; QoL, quality of life; RCT, randomized clinical trial; VAS, visual analog scale.

^a Means are shown with the SD in parentheses.

^b Bold face indicates articles obtained from systematic reviews in which light-based therapies other than PDT were used.

Table 2 Summary of Articles on Intralesional PDT for HS

Reference, y	Study Design, Aim and Period	Study Population	Intervention and Follow-up	Results	Conclusions	Comments	Quality of evidence																									
Valladares-Narganes et al, ⁵¹ 2015	<p><i>Design:</i> prospective case series</p> <p><i>Objective:</i> To apply PDT with intralesional light probes that can reach different depths with light at the lowest energy level possible</p> <p><i>Study period:</i> March–November 2013</p>	<p><i>No. of patients:</i> 27 (single group)</p> <p><i>Characteristics:</i></p> <table border="1"> <thead> <tr> <th></th> <th>Armpit n=22</th> <th>Breast n=26</th> <th>Buttocks n=9</th> <th>Other n=7</th> </tr> </thead> <tbody> <tr> <td>HSS Baseline</td> <td>20.5</td> <td>11</td> <td>12</td> <td>13</td> </tr> <tr> <td>HSS Final</td> <td>1</td> <td>0</td> <td>0</td> <td>0</td> </tr> <tr> <td>Outcome</td> <td>Complete: 15 Good: 4 Partial: 3</td> <td>Complete: 23 Good: 2 Partial: 1</td> <td>Complete: 8 Good: 1</td> <td>Complete: 7</td> </tr> <tr> <td>Energy</td> <td>1860 J IR (783-4354)</td> <td>1080 J IR (594-3961)</td> <td>1080 J IR (1044-2925)</td> <td>1296 J</td> </tr> </tbody> </table>		Armpit n=22	Breast n=26	Buttocks n=9	Other n=7	HSS Baseline	20.5	11	12	13	HSS Final	1	0	0	0	Outcome	Complete: 15 Good: 4 Partial: 3	Complete: 23 Good: 2 Partial: 1	Complete: 8 Good: 1	Complete: 7	Energy	1860 J IR (783-4354)	1080 J IR (594-3961)	1080 J IR (1044-2925)	1296 J	<p>Intralesional 1% ALA solution (dose, 0.2 mL/cm³). By cannula inserted into fistulous tracts, or needle injection into the diseased area if cannulation was impossible. The entrance to and exit from the fistula was covered for an incubation period of 3 h. Next, the fistula was irradiated intralesionally with a continuous diode laser (630 nm, fiberoptic probe 1 mm in diameter; 1 W/cm³; 180 J)/cm²). Light was transmitted through a 1-mm needle. If response was suboptimal or new lesions appeared nearby, an additional session was given.</p> <p><i>Follow-up:</i> 1, 3, and 6 mo</p> <p><i>Losses:</i> 1</p>	<p>Results on the modified Sartorius scale: 10 (37%) complete, 11 (41%) good, and 5 (19%) partial. Best results in the armpits (complete response in 6 of 8), including patients requiring treatment of both armpits. Moderate pain in 4 patients (VAS, 6–9) Most patients (22 of 27) tolerated the procedure well (VAS scores under 6). Adverse effects included postprocedural pain, erythema and slight swelling.</p>	<p>Intralesional PDT may be an effective and long-lasting treatment for HS. The best results are in isolated lesions in the armpits or sacral and breast regions, where most lesions are found. Multiple, interconnected fistulas require more sessions.</p>	<p>RCTs would be a good step toward adequate assessment of therapies alone or in combination. Trials should include dose detection and patient-relevant outcome measures.</p>	Moderate
	Armpit n=22	Breast n=26	Buttocks n=9	Other n=7																												
HSS Baseline	20.5	11	12	13																												
HSS Final	1	0	0	0																												
Outcome	Complete: 15 Good: 4 Partial: 3	Complete: 23 Good: 2 Partial: 1	Complete: 8 Good: 1	Complete: 7																												
Energy	1860 J IR (783-4354)	1080 J IR (594-3961)	1080 J IR (1044-2925)	1296 J																												

Table 2 (Continued)

Reference, y	Study Design, Aim and Period	Study Population	Intervention and Follow-up	Results	Conclusions	Comments	Quality of evidence
Agut-Busquet et al, ¹ 2016	<i>Design:</i> respective case series <i>Objective:</i> To describe the experience with 7 patients with HS treated with PDT using intralesional MB and light (635 nm) <i>Study period:</i> 8 mo	<i>No. of patients:</i> 7 <i>Characteristics:</i> HS clinical type 2, Hurley stage 3, at least 1 active zone	Intralesional 1% MB solution injected with or without ultrasound guidance. After incubation (15 min), irradiation with a 635-nm LED light (37 J/cm ²) 1–2 sessions, intervals of 15 d. <i>Follow-up:</i> 1, 2, 4, and 6 mo <i>Losses:</i> 1	Hurley stage-2 patients responded better than stage-3 patients (99% vs 87% improvement); best results in the groin. DQLI improvement in 6 patients: 78% (1), 80% (1), 90% (2), and 99% (2). Evaluation, Sartorius score and PGA: 78% (1 patient), 80% (1), 90% (2), 99% (2). Good response (86% improvement) to antibiotic in only 1 patient. <i>Adverse effects:</i> mild in 6 cases (86%); serious in 1 patient (cellulitis at treatment site, attributed to patient's manipulation of the area after therapy)	Intralesional PDT with MB gives good results in HS but is more effective in Hurley stage 2 than stage 3. RCTs are necessary to improve the quality of evidence.	Few patients, making extrapolation to the general population (external validation) difficult.	Low

Table 2 (Continued)

Reference, y	Study Design, Aim and Period	Study Population	Intervention and Follow-up	Results	Conclusions	Comments	Quality of evidence
Suárez Valladares et al, ⁵⁰ 2017	<i>Design:</i> prospective case series <i>Objective:</i> To evaluate the efficacy of intralesional PDT for the local management of HS in the short and medium term in different sites <i>Study period:</i> March 2011–November 2015	<i>No. of patients:</i> 38 <i>Characteristics:</i> Sex: 20 women, 18 men Age: 30–44 y Weight: 67.25–90 kg Mean (SD) BMI: 26.87 (4.89) BMI >27: 20 Smokers: 34 Prior treatments: 2, none; 1, topical; 23, oral antibiotics; 2, oral retinoids; 1, biologic; 9, surgery. Hurley stages: 1, 4 patients; 2, 21 patients; 3, 13 patients. Direct measures of severity: Hurley, baseline/total HSS, and DLQI indicated high disease activity.	After local anesthesia, 5% ALA gel was injected through a cannula to fill the fistulous tracts. Thus, all walls of fistulous tracts were treated regardless of depth. A lyophilized 1% solution was injected into nodules. Incubation under occlusion for 2 h before irradiation. Irradiation (1.2 W; fluence, 180 J/cm ²) with an intralesional 630-nm laser through a 400-mm fiberoptic probe inserted through a needle. Follow-up visits every 5–7 wk <i>Follow-up:</i> 26.1 (21.7–68.57) mo <i>Losses:</i> 0	Single session regardless of site, but the median energy used was greater in the armpits. Complete remission in 76.3%, mean disease-free period of 168 wk. New lesions at untreated sites were observed in 9 patients (23.7%); 6 of them had complete remission. Recurrence or no remission after treatment in 9 patients, in whom the percentages of obesity (33.% vs 58.6%) and smoking (66.7 vs 96.6%) were lower but disease severity was greater (44.4% vs 31%), modified Sartorius score was higher (36 vs 22) and DLQI poorer (16 vs 10) than in those with a good response to PDT.	Intralesional PDT might offer a new alternative treatment for HS lesions, alone or in combination; a high rate of complete remission was achieved and was long-lasting. No complications observed. Rapid recovery after treatment, with the possibility of repeating sessions.		Moderate

Abbreviations: BMI, body mass index; DLQI, Dermatology Life Quality Index; E, energy ; HS, hidradenitis suppurativa; HSS, hidradenitis severity score; IR, irradiation; MB, methylene blue; PDT, photodynamic therapy; PGA, Physician's Global Assessment; RCT, randomized clinical trial; VAS, visual analog scale.

Table 3 Summary of Articles Included in This Systematic Review According to Light Sources Used To Treat HS^a

Reference, y	Study Design, Aim and Period	Study Population	Intervention and Follow-up	Results	Conclusions	Comments	Quality of evidence
Nd:YAG Zerbinati et al, ⁴⁷ 2017	<i>Design:</i> prospective case series <i>Objective:</i> To evaluate the clinical and histologic effects of Nd:YAG laser treatment of HS <i>Study period:</i> not specified	<i>No. of patients:</i> 12 <i>Characteristics:</i> Hurley stage 1 HS Mean age 39.5 y (range, 24–50 y), bilateral disease	Nd:YAG laser (1064 nm) in 300–600- μ m polycarbonate-coated glass optical fiber; fluence, 300 J/cm ² . Different fiber diameters were used according to lesion size and site. Pulse energy, 150–350 mJ, 3 laser sessions (1 every 2 mo). <i>Follow-up:</i> 12 mo <i>Losses:</i> 0	Mean percent Sartorius score improvement, 85.3%. Decrease in inflammatory infiltrate confirmed histologically; fibrosis 4 mo posttreatment.	Nd:YAG laser is a well-tolerated, noninvasive alternative treatment for this chronic, debilitating disease.	More patients should be followed for longer periods to provide stronger evidence for conclusions.	Low

Table 3 (Continued)

Reference, y	Study Design, Aim and Period	Study Population	Intervention and Follow-up	Results	Conclusions	Comments	Quality of evidence
Nd:YAG and CO ₂ Abdel Azim et al, ⁴⁸ 2018	<i>Design:</i> RCT, intraindividual, blinded <i>Objectives:</i> To study the safety and efficacy of combined treatment with fractional CO ₂ and long-pulse (1064 nm) Nd:YAG laser for treating HS. <i>Study period:</i> January–December 2017	<i>No. of patients:</i> 20 (30 enrolled, 10 excluded) <i>Characteristics:</i> patients >18 y with bilateral Hurley stage 1 or 2 lesions	<i>Intervention:</i> 4 laser sessions at 2-wk intervals. Intervention-side treatment was combined fractional CO ₂ followed by long-pulse (1064 nm) Nd:YAG laser in the same session. <i>Control:</i> contralateral side, long-pulse (1064 nm) Nd:YAG laser only <i>Follow-up:</i> 3 mo after last session <i>Losses after randomization:</i> 5 during follow-up to assess sustained response	Significant improvement and greater patient satisfaction for the combined treatment over the control treatment ($P = .011$ and $.048$, respectively). PGA evaluation of response to treatment showed absence of recurrence in 55% of the intervention sides (combined treatment) vs 35% on the control sides. Histology of the skin 2 wk after the last session revealed a scant perifollicular lymphohistiocytic infiltrate on the combined-treatment side. Less decrease in the infiltrate and in dermal edema on the Nd:YAG-only side. No adverse effects other than erythema, which resolved spontaneously by 48 h. <i>Adverse effects:</i> 1 patient	Combined fractional CO ₂ and long-pulse (1064 nm) Nd:YAG laser therapy achieves greater improvement and patient satisfaction and lower recurrence rates in comparison with Nd:YAG therapy alone for HS in Hurley stages 1 and 2. Combined therapy could achieve better results in patients with low PGA scores who are not obese and have not undergone prior surgery at the site of a lesion.	Limitations, a small sample size and short follow-up. RCTs are needed to analyze intraindividual responses in more patients and for longer periods and to compare combined laser therapies to medical and surgical treatments of HS.	Moderate

Table 3 (Continued)

Reference, y	Study Design, Aim and Period	Study Population	Intervention and Follow-up	Results	Conclusions	Comments	Quality of evidence
Intralesional diode laser Fabbrocini et al, ⁴⁹ 2018	<i>Design:</i> prospective case series <i>Objective:</i> To evaluate the efficacy of intralesional 1064-nm diode laser treatments in mild-moderate HS. <i>Study period:</i> May 2016–January 2017	<i>No. of patients:</i> 20 <i>Characteristics:</i> patients with Hurley stage 1 or 2 HS, mild-moderate according to PGA	Diode laser (1064 nm) in 300–600 nm polycarbonate-coated glass optical fiber. Fluence, 250 J/cm ² , fiber diameters varied according to type of lesion and site. Pulse energy, 150–350 ms; selected potency, 6–8–10 W. A 30-gauge needle was used to inject an anesthetic solution (1 mL/cm ²) until tumescence. On the day of treatments, all patients started azithromycin (500 mg/d for 3 d). 4 treatment sessions, 2-wk intervals.	Each patient underwent 4 laser sessions at 2-wk intervals. Significant reduction (31%) in the Sartorius score from 28.55 (13.04) to 19.75 (12.29) after 4 sessions ($P < .05$). No patient worsened. Quality of life improved notably along with clinical improvement (reduction in DLQI scores ($P = .0307$)).	Intralesional 1064-nm diode laser treatment may be a good alternative for patients with moderate, localized HS, given it is minimally invasive and does not have significant complications. Recovery is rapid.	Few patients, low quality of evidence	Low

Abbreviations: CO₂, carbon dioxide; DLQI, Dermatology Life Quality Index; HS, hidradenitis suppurativa; Nd:YAG, neodymium-doped yttrium aluminum garnet; PGA, Physician's Global Assessment; RCT, randomized clinical trial.

^a Means are shown with the SD in parentheses.

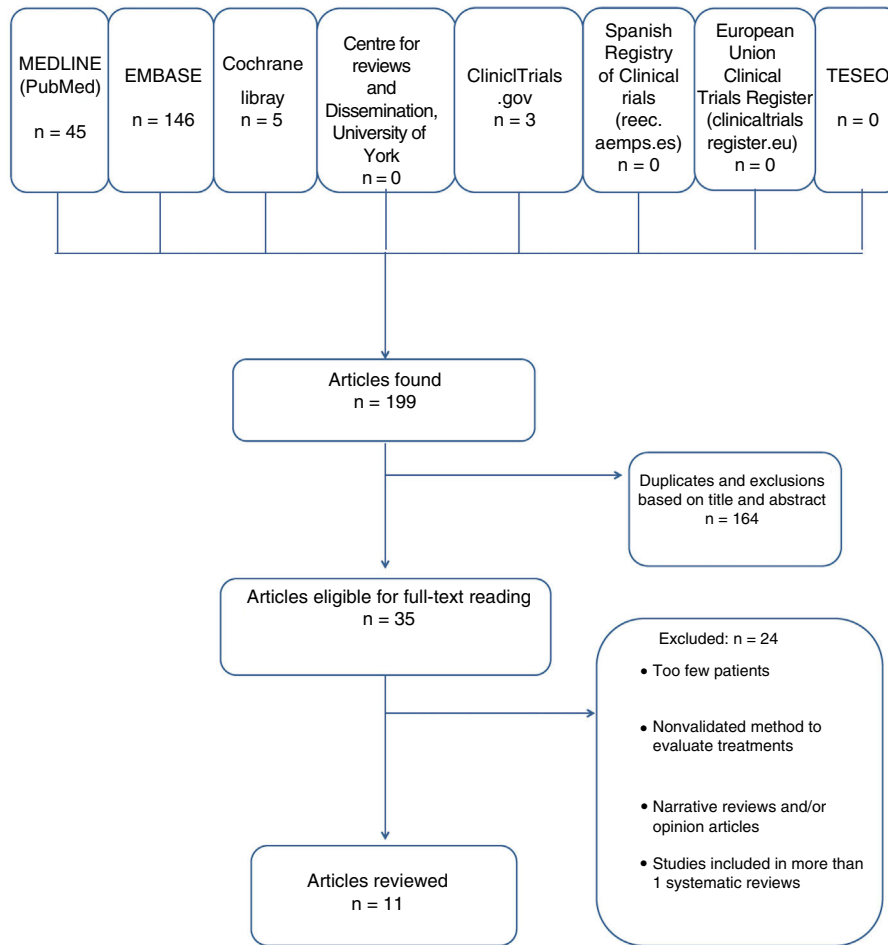


Figure 1 Flow chart of the literature search for this systematic review. TESEO is the database of doctoral theses in Andalusia, Spain.

Zerbinati et al⁴⁷ analyzed case series in which Nd:YAG laser was used, and Fabbrocini et al⁴⁹ evaluated the efficacy of diode laser irradiation in mild to moderate HS.

Outcome Measures

The included studies assessed outcomes in somewhat different ways. Most used the Sartorius score of 2003,^{1,2,11,38,39,41-43,45,47,49} but 2 studies used the modified version of this score.^{50,51} Five (Agut-Busquet et al,¹ Abdel Azim et al,⁴⁸ Calzavara-Pinton et al,⁴⁰ Fabbrocini et al,⁴⁹ and Madan et al⁴⁴) used the PGA.

Six evaluated changes in quality of life with the Dermatology Life Quality Index (DLQI) published by Finlay in 1994).^{1,2,41,42,49,50} General satisfaction was evaluated by Highton et al¹¹ with an unvalidated Likert scale and by Madan et al⁴⁴ with a score of 0 (very unsatisfied) to 10 (very satisfied).

Two studies assessed pain during and after treatment using a visual analog scale (VAS).^{2,51}

Four studies provided information about adverse effects,^{1,2,51} although Highton et al¹¹ only reported such effects if treatment had to be interrupted.

Finally, 5 studies reported recurrence rates. Agut-Busquet et al¹ emphasized recurrence, explaining each case. Suárez Valladares et al⁵⁰ reported recurrence in 9 patients. Highton et al¹¹ found that HS tended to recur 12 months after treatment. Recurrence 3 and 12 months after treatment was assessed by Abdel Azim et al⁴⁸ and Madan et al,⁴⁴ respectively.

Outcomes Obtained With Light-Based Therapies

Tables 1–3 summarize the research designs used and quality of evidence obtained by researchers studying the use of conventional PDT, intralesional PDT, and laser treatments. As explained above, the 3 systematic reviews we consulted included patients treated with both PDT and laser therapy. Therefore, to avoid repetition, one table (Table 1) presents the studies that applied laser treatments and IPL in bold face type.

PDT

Andino Navarrete et al² treated 5 patients with a 20% ALA solution for 1.5 h and then irradiated the area with a 635-nm LED lamp at a fluence of 37 J/cm² and intensity of

70 mW/cm² per session. The patients experienced improvements (Sartorius score, DLQI, and VAS) that was maintained at 8 weeks, although the differences were not statistically significant.

Fadel and Tawfik³⁸ used PDT with a 0.01% MB gel (formulation in liposomes with surfactants to increase penetration) and compared it to placebo (MB-free) gel. The area was irradiated with IPL (630 nm) for 20 ms at a fluence of 25 J/cm². The participants were authorized to receive treatment at every affected area of the body (armpits, buttocks, groin, and under the breasts). Results showed a Sartorius score reduction of 77.3% (liposome MB gel formulation) and 44.1% (MB-free placebo) ($P < .01$). The authors concluded that PDT with MB in this formulation is superior to irradiation after MB-free gel.³⁸

Calzavara-Pinton et al⁴⁰ studied patients with various diseases treated with MAL-PDT; 6 patients with HS were among them. The authors irradiated with red light (635 nm) every 2 weeks for 4 weeks and reported a PGA assessment of more than 75% in 33% of the cases, moderate improvement in half, and a poor response in 1 patient.

Schweiger et al⁴¹ described 12 patients treated with ALA-PDT with blue light and IPL weekly for 4 weeks. Four weeks after treatment they observed a reduction in the Sartorius score of 50.8%. At 8 weeks the reduction was 29.9%. The DLQI score fell from 17.3 to 13.1. Blue light was tolerated better than IPL.

Finally, Sotiriou et al⁴² applied a 20% ALA formulation in 5 sessions in 5 patients with Hurley stage 2 or higher HS. The mean Sartorius score decreased from 18.8% to 17.2%, and DLQI impact fell 6.4% on average. These results are summarized in Table 1.

Intralesional PDT

Valladares-Narganes et al⁵¹ administered 1% ALA (0.2 mL/cm³) into lesions followed by light exposure, as noted above, in a series of 27 patients with 1 to 3 lesions each. After 26.21 months (range, 21.07–68.57 months), responses were complete in 10 patients (37%), moderate in 11 (41%), and partial in 5 (19%). The authors saw the best results in armpit lesions (Table 2).

Agut-Busquet et al¹ injected a 1% MB solution into lesions under ultrasound guidance in 7 patients. After incubation (15 minutes), the lesions were irradiated with an LED lamp (Aktelite, 635 nm, 37 J/cm²). After 6 months the global assessment of response was 78% in 1 patient, 80% in 1, 90% in 2, and 99% in 2. Patients with Hurley stage 2 HS responded better (99%) than those with Hurley stage 3 (87%), and the best results were observed in groin lesions. DLQI improved significantly for 6 patients, coinciding with excellent response to treatment. Mild adverse effects (swelling or erythema) were observed in 6 patients (86%), but they resolved within a week (Table 2).

Suárez Valladares et al⁵⁰ injected a 5% ALA gel into lesions through a cannula placed along the sinus tract in 38 patients. After incubation under opaque occlusion for 2 hours, intralesional laser irradiation (630 nm, 1.2 W; fluence, 180 J/cm²) was applied with a fiberoptic probe (400 mm). All regions treated improved according to modified Sartorius scale results. There were 53 com-

plete responses, 7 good responses, and 4 partial responses. However, the differences were not statistically significant (Table 2).

Nd:YAG Laser Treatment

Tierney et al³⁹ compared Nd:YAG treatments with 10% benzoyl peroxide and daily application of 1% clindamycin versus application of the topical antibiotic alone. Seventeen patients were enrolled and 4 laser sessions were given at intervals of 1 month (Table 1). The reduction in severity according to modified Sartorius assessment was 65.3% at 3 months on average over all regions (73.4% in the groin, 62% in the armpits, and 53.1% under the breasts). Improvement was significant in laser-treated patients, but not in the control group (topical clindamycin only) ($P < .02$).

Xu et al⁴⁵ published a prospective, controlled histopathologic study in 19 patients with Hurley stage 2 HS. The patients were treated in 2 monthly sessions of Nd:YAG laser therapy (1064 nm). The percent response to treatment on the Sartorius score after 2 months was 31.6% ($P = .001$). Greater improvement was recorded in groin lesions (Table 1).

Zerbinati et al⁴⁷ observed a mean improvement of 85.3% in the Sartorius score with Nd:YAG treatment of very early Hurley stage 1 HS in 12 patients (Table 3). In a similar study, but with 22 patients with more severe HS (Hurley stage 2), Mahmoud et al⁴³ evaluated the response at 6 months to 4 sessions of a series of 1 long-pulse Nd:YAG treatment per month for 4 months. They also observed a decrease in the Sartorius score (–72%) (Table 1).

Other Types of Laser Treatment

An RCT of CO₂ laser treatment was carried out by Abdel Azim et al⁴⁸ in 20 patients over the age of 18 years who had Hurley stage 1 or 2 HS. The aim was to assess the safety and efficacy of combining fractional CO₂ irradiation with long-pulse Nd:YAG laser irradiation (1064 nm) in 4 sessions separated by 2 weeks. On the intervention side the patients received fractional CO₂ laser treatment followed by long-pulse Nd:YAG laser (1064 nm) in the same session. On the control side, only the Nd:YAG treatment was used. The authors concluded that improvement and satisfaction were greater with the combined treatment of early (Hurley stage 1 and 2) disease and that the recurrence rate was lower (Table 3).

Of 9 patients with medically and surgically refractory HS who received CO₂ laser treatments from Madan et al,⁴⁴ 7 had achieved complete remission at 12 months. Satisfaction was high (Table 1).

Finally, Fabbrocini et al⁴⁹ used laser diode light in a group with Hurley stage 1 or 2 HS and mild to moderate disease according to PGA. The patients received 4 sessions spaced every 2 weeks. A significant reduction of 31% was seen in the Sartorius scores, which changed from 28.55 (SD, 13.04) to 19.75 (SD, 12.29) ($P < .05$). The authors also reported a direct association between improvement and better quality of life (Table 3).

IPL

Highton et al¹¹ enrolled 18 patients in an RCT comparing active and control treatments on contralateral sides. The active treatment was IPL (50 ms, 420 nm, fluence of 7–10 J/cm²). They observed a mean reduction in the Sartorius score of 12% immediately after therapy, 10% at 3 to 6 months, and 3% at 12 months. The difference between the treated and control sides was significant ($P < .01$). Patient satisfaction was high. Response was complete in 1 case, excellent in 2 cases, good in 10, and moderately good in 4. Fifteen did not experience significant changes on the control side: 1 patient reported slight improvement and another experienced slight worsening. The treatment was applied once a week for 4 weeks. Follow-up was 12 months (Table 1).

Discussion

Considering the limited evidence available for light-based treatments for HS, it is difficult to draw conclusions about the efficacy of either intralesional versus topical approaches, or IPL or Nd:YAG laser. Variation in study designs makes comparison difficult.

We identified 3 photosensitizers being used in PDT: ALA, MAL, and MB. All of them were applied at different concentrations from 1% to 20% for ALA, 16% for MAL, and 0.01% to 1% for MB. Which concentration leads to a better response rate is difficult to establish because evaluation methods differ. Moreover, the type of light used to irradiate lesions also varies, as some groups use LED lamps,^{1,40,42} while others apply external² or intralesional laser^{50,51} and still others use IPL.^{38,41} The possibility of treating deep HS lesions is an important factor in efficacy, yet these light sources have frank differences in penetration. The light doses also differ, although the wavelength applied is similar at 630 or 635 nm.

The studies also treated lesions at different sites, for different durations and numbers of sessions (from 1⁵⁰ to 12³⁸). The main difference in technique, however, was between the use of topical versus intralesional application of both the photosensitizer (ALA, MAL, or MB) and the light source (LED, laser, or IPL).

We found that intralesional treatment approaches also differed between authors. Suárez Valladares et al⁵⁰ and Valladares-Narganes et al⁵¹ used 630-nm diode lasers and ALA at different concentrations. They assessed response with the modified Sartorius score, finding that response was better with a 5% ALA gel and a 400-nm diode laser (1.2 W and 180 J/cm²). Agut-Busquet et al,¹ on the other hand, used a 1% MB formulation and a 635-nm LED with a fluence of 37 J/cm². They assessed efficacy with the DQLI and the Sartorius score, reporting responses that varied from 99% for cases involving Hurley stage 1 to 87% in Hurley stage 3.

The single study of IPL we found reported that statistically significant improvement was maintained for 12 months and that the risk of complications was low.¹¹

The RCT of Nd:YAG laser treatment by Tierney et al³⁹ demonstrated efficacy. Later case series describing this treatment have reported reduction in the number of exacerbations and in severity.^{43,47} Efficacy has been reported to be greater in the groin.⁴⁵

Very few studies have been published on other types of lasers, but all of them report promising results. The combination of CO₂ and Nd:YAG lasers obtained better results than Nd:YAG irradiation alone and patient satisfaction was higher.⁴⁸ Madan et al⁴⁴ showed that CO₂ laser therapy and marsupialization also led to high rates of complete remission in spite of adverse effects, such as hypertrophic scarring.

We found a single study of diode laser therapy for HS that was considered mild to moderate according to the PGA.⁴⁸ The authors reported clinical and quality-of-life improvement after therapy.

In summary, the evidence supporting the use of light-based therapies for HS is limited. There are 2 major groupings of these therapies according to whether a photosensitizer is used or not. In 1 group, for which only a low-moderate level of evidence is available, the authors applied Nd:YAG laser, CO₂ laser, or IPL. In the other, for which the quality of evidence is also low-moderate, PDT (with photosensitizer) was used. Thus, all the treatments reviewed used light but they are not comparable: different techniques have different mechanisms of action. However, results for individual treatments do seem to suggest that approaches that offer greater penetration — whether by means of intralesional application or lasers — lead to better results.

RCTs are necessary to confirm the efficacy of these treatments. We also need to see standardized research protocols applying the design that is most appropriate for providing stronger evidence for the efficacy and safety of each technique.

Authorship

T. Gracia Cazaña and L.V. Berdel García contributed equally to this article.

Conflicts of interest

The authors declare that they have no conflicts of interest.

Acknowledgments

We thank Ms Visitación Ortega Riba and Ms Montserrat Salas Valera for their help with the systematic literature review and downloading of articles.

We are also grateful to the Government of the Spanish Autonomous Community of Aragon for their recognition of our research group (reference number B18.17D).

Appendix A. Supplementary data

Supplementary material related to this article can be found, in the online version, at doi:<https://doi.org/10.1016/j.adengl.2019.04.019>.

References

1. Agut-Busquet E, Romani J, Gilaberte Y, García-Malinis A, Ribera-Pibernat M, Luelmo J. Photodynamic therapy with intralesional methylene blue and a 635 nm light-emitting diode lamp in

- hidradenitis suppurativa: A retrospective follow-up study in 7 patients and a review of the literature. *Photochem Photobiol Sci.* 2016;15:1020–8.
2. Andino Navarrete R, Hasson Nisis A, Parra Cares J. Efectividad de la terapia fotodinámica con ácido 5-aminolevulínico en el tratamiento de la hidrosadenitis suppurativa. Serie de 5 casos. *Actas Dermosifiliogr.* 2014;105:614–7.
 3. Ingram JR, Woo PN, Chua SL, Ormerod AD, Desai N, Kai AC, et al. Interventions for hidradenitis suppurativa (Review). *Cochrane Database Syst Rev.* 2015.
 4. Herane MI, Alarcón R. Hidrosadenitis suppurativa y procesos afines. *Más dermatología.* 2012;4–12.
 5. García-Martínez FJ, Pascual JC, López-Martín I, Pereyra-Rodríguez JJ, Martorell Calatayud A, Salgado-Boquete L, et al. Actualización en hidrosadenitis suppurativa en Atención Primaria. *Semer - Med Fam.* 2016;43:34–42.
 6. Martorell A, García-Martínez FJ, Jiménez-gallo D, Pascual JC. Actualización en hidradenitis suppurativa (I): epidemiología, aspectos clínicos y definición de severidad de la enfermedad. *Actas Dermosifiliogr.* 2015;106:703–15.
 7. Buggiani G, Troiano M, Rossi R, Lotti T. Photodynamic therapy: Off-label and alternative use in dermatological practice. *Photodiagnosis Photodyn Ther.* 2008;5:134–8.
 8. MacCormack MA. Photodynamic therapy in dermatology: An update on applications and outcomes, 2008 applications and outcomes. *Semin Cutan Med Surg.* 2008;27:52–62.
 9. Dunn J, Koo J. *Dermatology Online Journal UC Davis. Dermatol Online J.* 2013;19:1–19.
 10. Piccolo D, Di Marcantonio D, Crisman G, Cannarozzo G, Sannino M, Chiricozzi A, et al. Unconventional Use of Intense Pulsed Light. *Biomed Res Int.* 2014;2014:1–10.
 11. Highton L, Chan W-Y, Khwaja N, Laitung JKG. Treatment of hidradenitis suppurativa with intense pulsed light: a prospective study. *Plast Reconstr Surg.* 2011;128:459–65.
 12. Saunte DM, Lapins J. Lasers and intense pulsed light hidradenitis suppurativa. *Dermatol Clin.* 2016;34:111–9.
 13. Jadad AR, Moore RA, Carroll D, Jenkinson C, Reynolds DJ, Gavaghan DJ, et al. Assessing the quality of reports of randomized clinical trials: Is blinding necessary? *Control Clin Trials.* 1996;17:1–12.
 14. Schulz KF, Altman DG, Moher D, CONSORT Group. CONSORT 2010 statement: Updated guidelines for reporting parallel group randomised trials. *Int J Surg.* 2011;9:672–7.
 15. López de Argumedo M, Reviriego E, Andrio E, Rico R, Sobradillo N, Hurtado de Saracho I, Madrid: Plan Nacional para el SNS del MSC. Servicio de Evaluación de Tecnologías Sanitarias del País Vasco, 2006 Vasco (Osteba) Revisión externa y validación de instrumentos metodológicos para la Lectura Crítica y la síntesis de la evidencia científica; 2006.
 16. Silva-Feistner M, Salomone C, Silva S, Vial-Letelier V. [Prepubertal Hidradenitis suppurativa: Report of 2 clinical cases]. *Rev Chil Pediatr.* 2016;87:193–8.
 17. Ingram JR. Hidradenitis suppurativa: An update. *Clin Med (Northfield Il).* 2016;16:70–3.
 18. Grimstad Ø, Ingvarsson G. Carbon dioxide laser treatment using methylene blue–assisted sinus tract identification in hidradenitis suppurativa. *Dermatologic Surg.* 2016;42:1303–4.
 19. Suárez-Valladares MJ, Rodríguez-Prieto MÁ, Serra-Llusà R. Penetration of 630nm laser and 5-aminolevulinic acid in tissue with intralesional photodynamic therapy. *Photodiagnosis Photodyn Ther.* 2016;16:166–8.
 20. Nicholson CL, Hamzavi I, Ozog DM. Rapid healing of chronic ulcerations and improvement in range of motion after fractional carbon dioxide (CO2) treatment after CO2 excision of hidradenitis suppurativa axillary lesions: A case report. *JAAD case reports.* 2016;2:4–6.
 21. Chen W, Plewig G. Should hidradenitis suppurativa/acne inversa best be renamed as dissecting terminal hair folliculitis? *Exp Dermatol.* 2017;26:544–7.
 22. Gulliver W, Zouboulis CC, Prens E, Jemec GBE, Tzellos T. Evidence-based approach to the treatment of hidradenitis suppurativa/acne inversa, based on the European guidelines for hidradenitis suppurativa. *Rev Endocr Metab Disord.* 2016;17:343–51.
 23. Ingram JR, Woo PN, Chua SL, Ormerod AD, Desai N, Kai AC, et al. Interventions for hidradenitis suppurativa: A Cochrane systematic review incorporating GRADE assessment of evidence quality. *Br J Dermatol.* 2016;174:970–8.
 24. van Rappard DC, Mekkes JR, Tzellos T. Randomized controlled trials for the treatment of hidradenitis suppurativa. *Dermatol Clin.* 2016;34:69–80.
 25. Mordon S. Treating hidradenitis suppurativa with photodynamic therapy. *J Cosmet Laser Ther.* 2018;20:223–8.
 26. Zhang Y, Yang Y, Zou X. Photodynamic therapy for hidradenitis suppurativa/acne inversa: Case report. *Photodiagnosis Photodyn Ther.* 2018;22:251–2.
 27. Jourabchi N, Anzaldi L, Erdag G, Cohen B. Pulsed-dye laser treatment of a nonhealing chronic wound that developed after incision and drainage of a hidradenitis suppurativa abscess. *Dermatol Surg.* 2018;44:447–9.
 28. Scuderi N, Monfrecola A, Dessy LA, Fabbrocini G, Megna M, Monfrecola G. Medical and surgical treatment of hidradenitis suppurativa: A review. *Ski Appendage Disord.* 2017;3:95–110.
 29. Emtestam L, Lapins J, Sartorius K. Carbon dioxide laser treatment using methylene blue–assisted sinus tract identification in hidradenitis suppurativa. *Dermatologic Surg.* 2017;43:604–5.
 30. Ingram JR. Interventions for hidradenitis suppurativa. *JAMA Dermatology.* 2017;153:458.
 31. Levoska MA, Nicholson CL, Hamzavi IH. A retrospective review of light- and laser-based management of hidradenitis suppurativa. *Semin Cutan Med Surg.* 2017;36:67–74.
 32. Hamzavi IH, Griffith JL, Riyaz F, Hesses S, Bechara FG. Laser and light-based treatment options for hidradenitis suppurativa. *J Am Acad Dermatol.* 2015;73:578–81.
 33. Marasca C, Annunziata MC, Napolitano M, Fabbrocini G. Unconventional therapies for hidradenitis suppurativa. *Expert Rev Clin Pharmacol.* 2018;11:879–87.
 34. Zhang L, Wang P, Shi L, Zhang G, Zhang Y, Zhou Z, et al. Topical 5-aminolevulinic acid photodynamic therapy improved refractory acne conglobata and perifolliculitis capitis abscedens et suffodiens rather than hidradenitis suppurativa. *J Innov Opt Health Sci.* 2016;09:1640002.
 35. Mikkelsen PR, Dufour DN, Zarchi K, Jemec GBE. Recurrence rate and patient satisfaction of CO2 laser evaporation of lesions in patients with hidradenitis suppurativa: A retrospective study. *Dermatol Surg.* 2015;41:255–60.
 36. Vossen ARJV, van der Zee HH, Terian M, van Doorn MBA, Prens EP. Laser hair removal alters the disease course in mild hidradenitis suppurativa. *JDDG J der Dtsch Dermatologischen Gesellschaft.* 2018;16:901–3.
 37. Theut Riis P, Saunte DM, Sigsgaard V, Wilken C, Jemec GBE. Intense pulsed light treatment for patients with hidradenitis suppurativa: Beware treatment with resorcinol. *J Dermatolog Treat.* 2018;29:385–7.
 38. Fadel MA, Tawfik AA. New topical photodynamic therapy for treatment of hidradenitis suppurativa using methylene blue niosomal gel: A single-blind, randomized, comparative study. *Clin Exp Dermatol.* 2015;40:116–22.
 39. Tierney E, Mahmoud BH, Hexsel C, Ozog D, Hamzavi I. Randomized control trial for the treatment of hidradenitis suppurativa with a neodymium-doped yttrium aluminium garnet laser. *Dermatol Surg.* 2009;35:1188–98.
 40. Calzavara-Pinton PG, Rossi MT, Aronson E, Sala R, Italian Group For Photodynamic Therapy. A retrospective analysis

- of real-life practice of off-label photodynamic therapy using methyl aminolevulinate (MAL-PDT) in 20 Italian dermatology departments. Part 1: Inflammatory and aesthetic indications. *Photochem Photobiol Sci*. 2013;12:148–57.
41. Schweiger ES, Riddle CC, Aires DJ. Treatment of hidradenitis suppurativa by photodynamic therapy with aminolevulinic acid: Preliminary results. *J Drugs Dermatol*. 2011;10:381–6.
 42. Sotiriou E, Apalla Z, Maliamani F, Ioannides D. Treatment of recalcitrant hidradenitis suppurativa with photodynamic therapy: Report of five cases. *Clin Exp Dermatol*. 2009;34:e235–6.
 43. Mahmoud BH, Tierney E, Hexsel CL, Pui J, Ozog DM, Hamzavi IH. Prospective controlled clinical and histopathologic study of hidradenitis suppurativa treated with the long-pulsed neodymium:yttrium-aluminium-garnet laser. *J Am Acad Dermatol*. 2010;62:637–45.
 44. Madan V, Hindle E, Hussain W, August PJ. Outcomes of treatment of nine cases of recalcitrant severe hidradenitis suppurativa with carbon dioxide laser. *Br J Dermatol*. 2008;159:1309–14.
 45. Xu LY, Wright DR, Mahmoud BH, Ozog DM, Mehregan DA, Hamzavi IH. Histopathologic study of hidradenitis suppurativa following long-pulsed 1064-nm Nd:YAG laser treatment. *Arch Dermatol*. 2011;147:21–8.
 46. Suárez Valladares MJ, Eiris Salvado N, Rodríguez Prieto MA. Treatment of hidradenitis suppurativa with intralesional photodynamic therapy with 5-aminolevulinic acid and 630nm laser beam. *J Dermatol Sci*. 2017;85:241–6.
 47. Zerbinati N, D'Este E, Ini L, Baruffato A, Premoli V, Calligaro A, et al. Clinical and histological changes in hidradenitis suppurativa following 1064 nm Nd:YAG intralesional laser treatment. *J Biol Regul Homeost Agents*. 2017;31:131–40.
 48. Abdel Azim AA, Salem RT, Abdelghani R. Combined fractional carbon dioxide laser and long-pulsed neodymium: yttrium-aluminium-garnet (1064 nm) laser in treatment of hidradenitis suppurativa; a prospective randomized intra-individual controlled study. *Int J Dermatol*. 2018;57:1135–44.
 49. Fabbrocini G, França K, Lotti T, Marasca C, Annunziata MC, Cacciapuoti S, et al. Intralesional diode laser 1064 nm for the treatment of hidradenitis suppurativa: A report of twenty patients. *Open Access Maced J Med Sci*. 2018;6:31–4.
 50. Suárez Valladares MJ, Salvado NE, Rodríguez Prieto MÁ. Treatment of hidradenitis suppurativa with intralesional photodynamic therapy with 5-aminolevulinic acid and 630 nm laser beam. 2017;85:241–6.
 51. Valladares-Narganes LM, Rodríguez-Prieto MA, Blanco-Suárez MD, Rodríguez-Lage C, García-Doval I. Treatment of hidradenitis suppurativa with intralesional photodynamic therapy using a laser diode attached to an optical cable: A promising new approach. *Br J Dermatol*. 2015;172:1136–9.
 52. John H, Manoloudakis N, Stephen Sinclair J. A systematic review of the use of lasers for the treatment of hidradenitis suppurativa. *J Plast Reconstr Aesthet Surg*. 2016;69:1374–81.
 53. Robert E, Bodin F, Paul C, Konstantinou M-P, Gall Y, Grolleau J-L, et al. Non-surgical treatments for hidradenitis suppurativa: A systematic review. *Ann Chir Plast Esthet*. 2017;62:274–94.