

## IMAGES IN DERMATOLOGY

### Lupus Miliaris Disseminatus Faciei<sup>☆</sup>

### Lupus miliar disseminado de la cara

V. Zawar, S. Kumavat,\* M. Pawar

MVP'S DVP Medical College and Hospital, Nashik, Maharashtra, India

Received 28 December 2017; accepted 31 March 2018

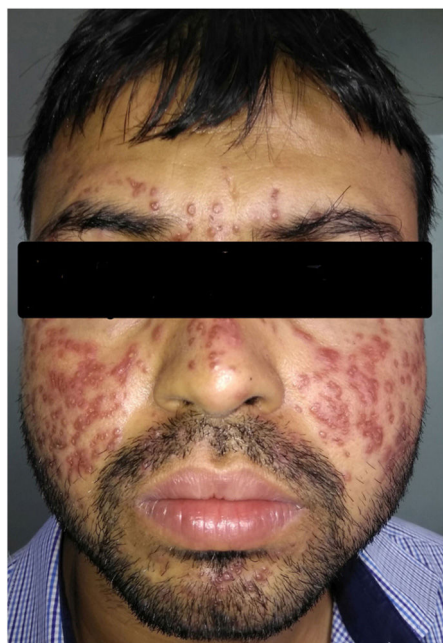


Figure 1

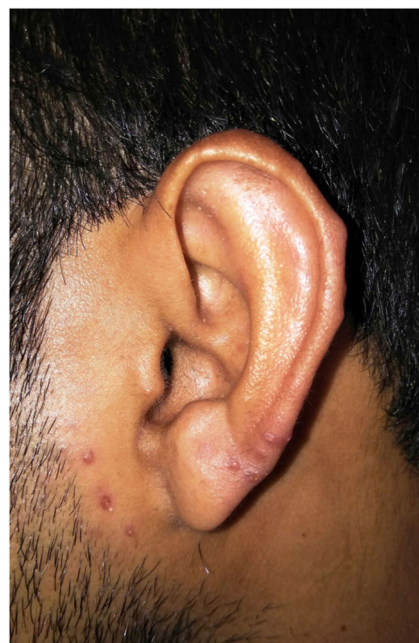

Figure 2

A 23-year-old male presented with asymptomatic recurrent, multiple, erythematous papulo-pustular eruption since six months over centro-facial areas. He previously received systemic isotretinoin, azithromycin and topical mupirocin, fusidic acid and ketoconazole. On examination there

were symmetric profuse erythematous papulo-pustules over malar areas, nose and ears with pitted scars of previously healed lesions (Figs. 1 and 2). We kept differential diagnosis as lupus miliaris disseminatus faciei (LMD), acne vulgaris, sarcoidosis and granulomatous rosacea. Skin biopsy revealed granulomas with caseating central necrosis surrounded by epithelioid histiocytes in dermis confirming the diagnosis of LMD. It is a chronic, granulomatous inflammatory disorder with erythematous papules and pustules over central areas of face. Our patient improved with oral dapsone 100 mg daily for four weeks. He remained clear for 6 months and later he was lost to follow up.

<sup>☆</sup> Please cite this article as: Zawar V, Kumavat S, Pawar M. Lupus Miliaris Disseminatus Faciei. *Actas Derma-Sifiliográficas*. 2020;111:70.

\* Corresponding author.

E-mail address: [shri.kumavat@gmail.com](mailto:shri.kumavat@gmail.com) (S. Kumavat).