

Green Nail Caused by Onychomycosis Coinfected With *Pseudomonas aeruginosa*[☆]



Uña verde causada por onicomicosis coinfectada por *Pseudomonas aeruginosa*

To the Editor:

Pseudomonas aeruginosa causes multiple cutaneous infections, which are typically mild in immunocompetent individuals but can be potentially serious in immunocompromised patients. These include interdigital intertrigo, green foot syndrome, folliculitis (swimming pool or hot-tub folliculitis), pyodermitis vegetans, balanitis, otitis externa (swimmer's otitis), malignant otitis externa, omphalitis of newborn, ecthyma gangrenosum, cellulitis, abscesses, nodules, necrotizing fasciitis, and superinfection of burn wounds, surgical wounds, and diabetic, decubitus, or venous foot ulcers.¹

Green nail, also known as chloronychia or green nail syndrome, is usually caused by infection with *P aeruginosa*. The clinical presentation consists of a classic triad of green discoloration (yellowish green, brownish-green, bluish-green, or black-green) of the ungual lamina, proximal chronic paronychia, and distolateral onycholysis. Most strains of this bacterium produce pigments, including the yellowish-green fluorescein pyoverdine and blackish green pyocyanin (1-hydroxy-5-methyl-phenazine), which give rise to the typical green color of infected nails. The differential diagnosis includes subungual hematoma, malignant melanoma, jaundice, blistering disease, yellow nail syndrome, infections caused by other agents such as *Trichosporon inkin* and *Aspergillus*, *Candida*, and *Proteus* species, drug-induced nail discoloration, and exogenous pigmentation caused by chemical substances.^{2,3}

Factors that predispose individuals to green nail due to *P aeruginosa* infection include immunocompromise, diabetes mellitus, nail trauma, damp environments, and prolonged exposure to water, soap, or detergents. Nails previously affected by onycholysis, paronychia, onychotillomania, or nail psoriasis are more vulnerable.² A strong relationship between fungal and *P aeruginosa* nail infections has also been reported.^{4,5}

We present the clinical and dermoscopic findings of an immunocompetent male patient with green nail caused by onychomycosis (OM) coinfecting with *P aeruginosa*.

The patient was a 39-year-old man with no personal history of interest who was seen for discoloration of a toe-

nail on his right foot that had begun 2 years earlier. He reported no previous trauma. He had been treated with a 5% amorolfine solution twice per week for 3 months, without improvement.

Physical examination revealed subungual hyperkeratosis and yellow-green discoloration of the nail plate of the fifth toe of the right foot (Fig. 1A and B). Dermoscopy revealed alterations of the nail, subungual hyperkeratosis, an irregular distal border, and a multicolored pattern on the nail plate consisting of areas of homogeneous greenish and blackish-blue coloration and other longitudinally distributed yellow-colored areas (Fig. 1C). The interdigital spaces of both feet were macerated and fissured.

The suspected diagnosis was tinea pedis associated with OM or *P aeruginosa* nail infection. Several samples of the affected nail were collected for fungal and bacterial culture. Culture revealed growth of *P aeruginosa* and a filamentous fungus that could not be identified due to bacterial overgrowth. Initial treatment, selected based on the results of an antibiogram, consisted of oral ciprofloxacin (500 mg/12 h) for 10 days, and was followed by oral terbinafine (250 mg/d) for 3 months. Follow-up evaluation after 6 months revealed complete resolution of the infectious process.

Tinea pedis (athlete's foot) is considered the most prevalent dermatophytic infection and most often affects the interdigital spaces. The simple form is asymptomatic or mildly pruritic and is characterized by erythema, scaling, and cracking. The third and fourth interdigital spaces are most commonly affected. Some nondermatophyte fungi and bacteria (*Corynebacterium minutissimum*) cause similar clinical manifestations. The complex form of tinea pedis interdigitalis is characterized by secondary bacterial superinfection and a more severe presentation. It usually causes itching or pain with inflammation, maceration, erosions, and foul odor.^{6,7}

OM is an infection of the nails caused by dermatophyte fungi (tinea unguium), nondermatophyte filamentous fungi, or yeast. The presumptive diagnosis is established based on clinical features and should be confirmed by mycological analyses (direct examination and culture) or histology. Dermoscopy (onychoscopy) can be diagnostically useful. Depending on the clinical presentation, OM is classified as distal and lateral subungual, superficial (black and white), proximal subungual, endonyx, mixed pattern, total dystrophic, or secondary.⁵

P aeruginosa coinfection has been described in patients with OM,^{4,5} as well as those with tinea pedis.⁷ In these cases there is subungual hyperkeratosis and yellow-green discoloration of the affected nails.⁴ The presence of fungi favors colonization and promotes the growth of *P aeruginosa*. In cases of coinfection with *P aeruginosa* isolation of the causative fungus may be impossible due to bacterial overgrowth in culture or the bacteria's fungistatic and/or fungicidal properties.^{4,7} In fact, this bacterium produces substances that inhibit in vitro growth of yeasts (*Candida albicans*), nondermatophyte filamentous fungi (*Aspergillus fumigatus* and *Fusarium solani*), and

[☆] Please cite this article as: Monteagudo B, Figueroa O, Suárez-Magdalena O, Méndez-Lage S. Uña verde causada por onicomicosis coinfectada por *Pseudomonas aeruginosa* Eczema y urticaria en Portugal. 2019;110:783–785.

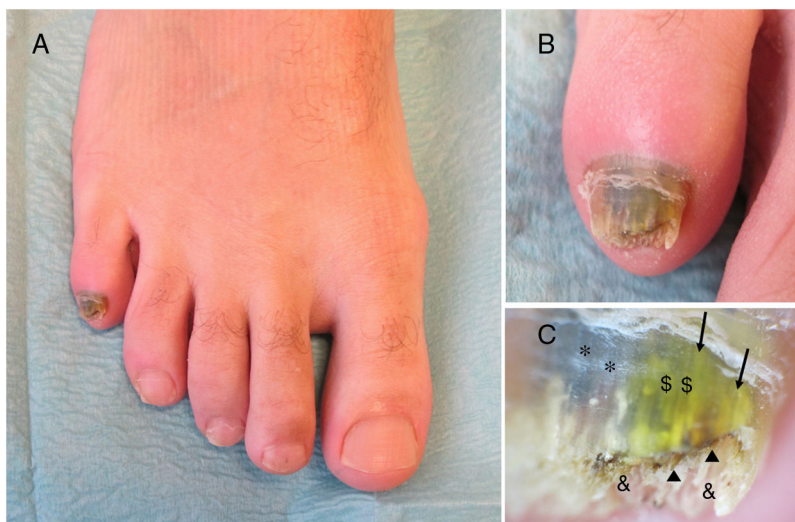


Figure 1 Nail of the fifth toe of the right foot. A, Yellow-green discoloration of the nail plate. B, Subungual hyperkeratosis and areas of yellow, green, and black discoloration. C, Dermoscopic image showing subungual hyperkeratosis (&), an irregular distal border, brown areas with a hemorrhagic appearance (?), and discoloration of the nail plate with homogeneous areas of green (\$) and blackish-blue (*) and longitudinally distributed areas of yellowish discoloration (→).

dermatophyte fungi (*Trichophyton mentagrophytes* and *Trichophyton rubrum*).^{8,9}

In the present case culture of a nail sample allowed isolation, but not identification, of a filamentous fungus. We were unable to determine whether the fungus in question was dermatophytic or not. Moreover, we did not collect samples from the interdigital spaces of the patient. The growth of dermatophytes such as *Trichophyton* species in cultures of these samples could have confirmed a clinical diagnosis of tinea pedis. Because the clinical, dermoscopic, and microbiological findings were compatible with a mixed bacterial (*P aeruginosa*) and fungal nail infection, we decided to prescribe treatment with ciprofloxacin and an oral anti-fungal for 3 months. Another useful therapeutic option in cases in which a single nail is affected is photodynamic therapy, which can be combined with concurrent tinea pedis treatment.¹⁰

In conclusion, we describe a new case of green nail caused by OM coinfecting with *P aeruginosa* in an immunocompetent adult male. Adequate treatment is essential in cases of OM with concomitant fungal and *Pseudomonas* infection. Because the interaction between the 2 agents can complicate microbiological diagnosis, it is important to be familiar with their respective clinical and dermoscopic features.

Conflicts of Interest

The authors declare that they have no conflicts of interest.

References

- García-Martínez FJ, López-Martín I, Castellanos-González M, Segurado-Rodríguez MA. Úlceras plantares verdes. *Enferm Infecc Microbiol Clin*. 2017;35:536–7.
- Chiriac A, Brzezinski P, Foia L, Marincu I. Chloronychia: green nail syndrome caused by *Pseudomonas aeruginosa* in elderly persons. *Clin Interv Aging*. 2015;10:265–7.
- Gish D, Romero BJ. Green fingernail. *J Fam Pract*. 2017;66: E7–9.
- Yang YS, Ahn JJ, Shin MK, Lee MH. *Fusarium solani* onychomycosis of the thumbnail coinfecting with *Pseudomonas aeruginosa*: report of two cases. *Mycoses*. 2011;54:168–71.
- Elewski BE. Bacterial infection in a patient with onychomycosis. *J Am Acad Dermatol*. 1997;37:493–4.
- Gupta AK, Skinner AR, Cooper EA. Interdigital tinea pedis (dermatophytosis simplex and complex) and treatment with ciclopirox 0.77% gel. *Int J Dermatol*. 2003;42 Suppl 1: 23–7.
- Aspiroz C, Toyas C, Robres P, Gilaberte Y. Interacción de *Pseudomonas aeruginosa* y hongos dermatofitos: repercusión en el curso clínico y en el diagnóstico microbiológico de la tinea pedis. *Actas Dermosifiliogr*. 2016;107:78–81.
- Treat J, James WD, Nachamkin I, Seykora JT. Growth inhibition of *Trichophyton* species by *Pseudomonas aeruginosa*. *Arch Dermatol*. 2007;143:61–4.
- Foster KW, Thomas L, Warner J, Desmond R, Elewski BE. A bipartite interaction between *Pseudomonas aeruginosa* and fungi in onychomycosis. *Arch Dermatol*. 2005;141: 1467–8.
- Robres P, Aspiroz C, Rezusta A, Gilaberte Y. Utilidad de la terapia fotodinámica en el manejo de la onicomycosis. *Actas Dermosifiliogr*. 2015;106:795–805.

B. Monteagudo,^{a,*} O. Figueroa,^b O. Suárez-Magdalena,^a
S. Méndez-Lage^b

^a Servicio de Dermatología, Complejo Hospitalario Universitario de Ferrol, Xerencia de Xestión Integrada de Ferrol, SERGAS, Ferrol, A Coruña, España

^b Servicio de Microbiología, Universitario de Ferrol, Xerencia de Xestión Integrada de Ferrol, SERGAS, Ferrol, A Coruña, España

* Corresponding author.

E-mail address: benigno.monteagudo.sanchez@sergas.es (B. Monteagudo).

<https://doi.org/10.1016/j.adengl.2018.04.023>
1578-2190/

© 2019 Elsevier España, S.L.U. and AEDV. Published by Elsevier España, S.L.U. All rights reserved.

***Microsporum audouinii*: Re-Emergence of Ringworm Due to the Dermatophyte[☆]**



***Microsporum audouinii*: un dermatofito causante de una tiña reemergente**

To the Editor:

Microsporum audouinii, an anthropophilic dermatophyte fungus that has been rarely reported since the middle of the last century, is re-emerging in several European countries. Unlike other species that cause ringworm, it can cause epidemics of tinea capitis in schools. We present a typical clinical case and summarize the clinical and epidemiological data from cases recorded in our microbiology department between 2005 and 2017.

A 5-year-old black boy was seen for multiple areas of alopecia and gray scaling on the scalp (Fig. 1) that had appeared 1 month earlier. Hair and scales were collected from the scalp with a scalpel, carpet square, and a sterile brush. Microscopic examination with 20% KOH + 40% DMSO revealed a mycelium and ectothrix spores compatible with a dermatophyte fungus. Hairs and scales were cultured in Sabouraud chloramphenicol actidione agar, in which flat colonies with a stellate fringe, a woolly-white superficial mycelium, and a pale yellow-orange underside grew after 5 days (Fig. 2A and B). Examination of microscopic morphology after 7 days in potato dextrose agar revealed pectinate hyphae, abortive macroconidia, and intercalary and terminal chlamydospores, enabling identification of the species as *M. audouinii* (Fig. 2C–F). *M. audouinii* was also identified by examination of the culture by matrix-assisted laser desorption/ionization time-of-flight mass spectrometry (MALDI-TOF MS; VITEK MS, bioMérieux, Marcy l'Etoile, France) after incubation for 7 days in potato dextrose agar. The patient had never left Spain, but did have contact with his black African father who had travelled outside the country. Clinical examination and mycological culture of scalp samples from members of the patient's family

(except for the father, who was unavailable) confirmed that none presented any lesions or were asymptomatic carriers. No new cases were reported in the patient's school. The patient was treated with micronized griseofulvin in oral suspension (10 mg/kg/d). He responded well during the first month, but fungal regrowth was observed in the second month and the dose was increased to 20 mg/kg/day. Four weeks later, with no further improvement observed, the dose was increased to 25 mg/kg/day. Cure was achieved 8 weeks later, after a total of 5 months of griseofulvin treatment.

Between 2005 and 2017, 16 cases of ringworm due to *M. audouinii* were recorded in our hospital (Table 1). The first was recorded in 2010. Eleven of the 16 cases had tinea capitis and 7 were originally from Africa or had been in contact with other Africans.

M. audouinii is a globally distributed anthropophilic dermatophyte fungus, and together with *Trichophyton soudanense* is the most common cause of tinea capitis in Africa, where it is endemic. Identification by MALDI-TOF MS involves characterization of the isolate's protein profile and comparison with those recorded in a protein library. The

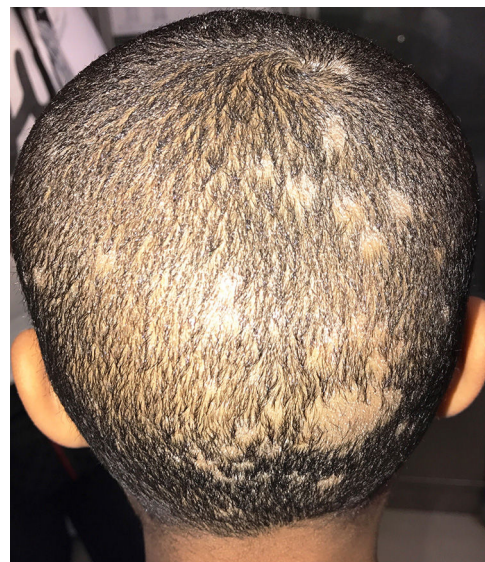

Figure 1 Tinea capitis in a 5-year-old black boy born in Spain. Multiple areas of alopecia with gray scales are evident on the scalp.

[☆] Please cite this article as: Lozano-Masdémont B. *Microsporum audouinii*: un dermatofito causante de una tiña reemergente Eczema y urticaria en Portugal. 2019;110:785–787.