



ACTAS Derma-Sifiliográficas

Full English text available at
www.actasdermo.org



E-IMAGES IN DERMATOLOGY

Diagnosis of Lung Cancer Due to a Complicated Abscess[☆]



Diagnóstico de cáncer de pulmón a raíz de un «absceso» complicado

I. Torres-Navarro,^{a,*} J. Piqueras-García,^a R. Botella-Estrada^{a,b}

^a Servicio de Dermatología, Hospital Universitario y Politécnico La Fe, Valencia, España

^b Departamento de Dermatología, Facultad de Medicina, Universidad de Valencia, Valencia, España

Received 15 November 2017; accepted 14 January 2018

A 46-year-old man was referred to the emergency department for drainage of a painful abscess on the left axilla that had grown rapidly during the previous 2 months.

Examination revealed an excrescent erythematous tumor in the form of a nodule with impaired skin integrity. The nodule was stony-hard, nonfluctuant, and attached to deeper layers (Fig. 1).

A subcutaneous nodule with similar characteristics was palpable immediately above the lesion (Fig. 1A, asterisk).

In addition, the patient reported intense asthenia and weight loss of 11 kg in recent months.

The clinical suspicion of skin metastasis of an internal tumor prompted us to perform a blood workup, which revealed no significant abnormalities, and chest x-ray (Fig. 1B, red arrow). The findings of the x-ray led us to perform a computed tomography scan of the chest (Fig. 1C, circle), which revealed a hilar mass in the right lung (Fig. 1B and c).

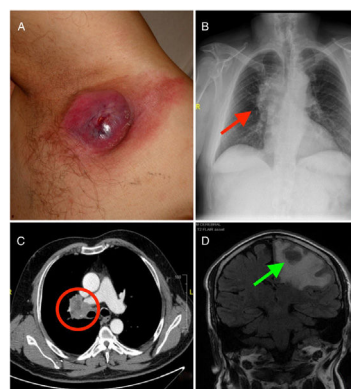


Figure 1

[☆] Please cite this article as: Torres-Navarro I, Piqueras-García J, Botella-Estrada R. Diagnosis of Lung Cancer Due to a Complicated Abscess Eczema y urticaria en Portugal. 2019;110:e1.

* Corresponding author.

E-mail address: ignaciotorresnavarro@gmail.com (I. Torres-Navarro).

The subsequent extension study revealed brain metastases (Fig. 1D, green arrow, note the surrounding cerebral edema).

Analysis of the biopsy of the lung mass confirmed the diagnosis of pulmonary adenocarcinoma, and palliative treatment was started.