



ACTAS Derma-Sifiliográficas

Full English text available at
www.actasdermo.org



E-IMAGES IN DERMATOLOGY

Recurrent Perimenstrual Vesicles Inside the Ear: A Rare Presentation[☆]



Vesículas perimenstruales recurrentes en el interior de la oreja. Una presentación inusual

V. Zawar, M. Pawar,* S. Kumavat

Dermatology, Skin Disease Centre, Nashik, Maharashtra, India

Received 13 September 2017; accepted 5 November 2017

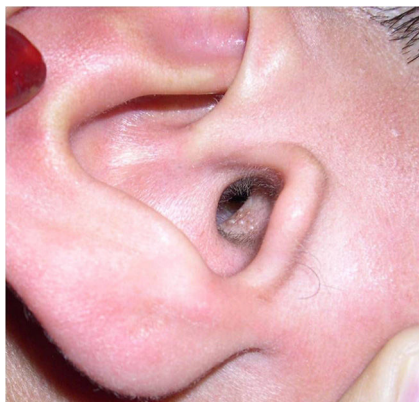

Figure 1

A 15-year-old girl attended the clinic with recurrent vesicular rash on an erythematous base along the external auditory meatus. The rash was usually worse before menstruation (Fig. 1) and was associated with regional enlarged lymph nodes. The patient was otherwise healthy. She reported having had labial herpes in the past. The rest of the physical examination, as well as the laboratory studies (gram stain, potassium hydroxide test, and bacterial culture of vesicular fluid), yielded negative results. Tzanck testing of the vesicular fluid revealed the presence of multinucleate giant

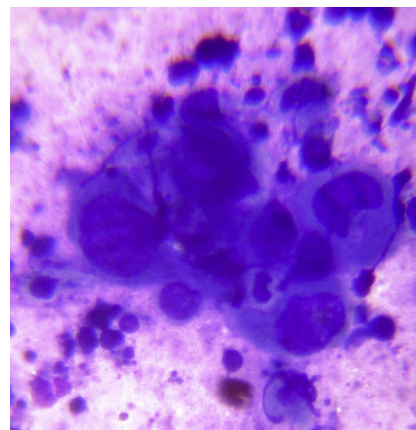


Figure 2

cells (Fig. 2), and in each recurrence, a positive titer was obtained for the antiviral antibody of *Herpes simplex virus* (HSV) 1. No predisposing factors were identified. Therapy with oral acyclovir was effective.

HSV infection typically affects the skin on the face (including the clinical form *Herpes gladiatorum* infection, which usually involves the ear) or genital mucosa and skin and is generally less common on the trunk and limbs. While HSV is known to infect several cranial nodes, involvement of the external auditory meatus is extremely rare. Hormonal changes associated with the menstrual cycle may affect the immune response to HSV, and, in some women, premenstrual recurrence of HSV infection is fairly typical, as in the case we report. Given the connections between the auditory nerve branches and facial nerve branches, local dissemination of HSV may lead to facial nerve palsy.

[☆] Please cite this article as: Zawar V, Pawar M, Kumavat S. Recurrent Perimenstrual Vesicles Inside the Ear: A Rare Presentation. *Actas Dermosifiliogr.* 2019;110:e15.

* Corresponding author.

E-mail address: manojpawar624@yahoo.com (M. Pawar).