

with daylight PDT, which has been proposed as an alternative when conventional facilities for PDT are unavailable.<sup>10</sup> Daylight PDT can be self-administered and is less painful.

In summary, PDT is a safe, less aggressive treatment that does not generate resistance and can achieve full clearance of CL lesions. It leaves residual scars that are not depressed and provides optimal long-term aesthetic results. These characteristics make it an effective alternative treatment for CL in our clinical practice.

## Conflicts of Interest

The authors declare that they have no conflicts of interest.

## References

1. Unger A, O'Neal S, Machado PR, Guimarães LH, Morgan DJ, Schriefer A, et al. Association of treatment of American cutaneous leishmaniasis prior to ulcer development with high rate of failure in northeastern Brazil. *Am J Trop Med Hyg.* 2009;80:574–9.
2. Aronson N, Herwaldt BL, Libman M, Pearson R, Lopez-Velez R, Weina P, et al. Diagnosis and treatment of leishmaniasis: Clinical practice guidelines by the Infectious Diseases Society of America (IDSA) and the American Society of Tropical Medicine and Hygiene (ASTMH). *Clin Infect Dis.* 2016;63:e202–64.
3. González U, Pinart M, Reveiz L, Alvar J. Interventions for Old World cutaneous leishmaniasis. *Cochrane Database Syst Rev.* 2008, <http://dx.doi.org/10.1002/14651858.CD005067.pub3>. CD005067.
4. Morton CA, Szeimies RM, Sidoroff A, Wennberg AM, Basset-Seguín N, Calzavara-Pinton P, et al. Guidelines on topical photodynamic therapy. *European Dermatology Forum.* 2017 [cited 2017 Jun 29]. Available from: <http://www.euroderm.org/edf/index.php/edf-guidelines/category/5-guidelines-miscellaneous>.
5. Jori G, Fabris C, Soncin M, Ferro S, Coppellotti O, Dei D, et al. Photodynamic therapy in the treatment of microbial infections: Basic principles and perspective applications. *Lasers Surg Med.* 2006;38:468–81.
6. Morton C, Szeimies RM, Sidoroff A, Wennberg AM, Basset-Seguín N, Calzavara-Pinton P, et al. European dermatology forum guidelines on topical photodynamic therapy. *Eur J Dermatol.* 2015;25:296–311.
7. Abok K, Cadenas E, Brunk U. An experimental model system for leishmaniasis. Effects of porphyrin-compounds and menadione on *Leishmania* parasites engulfed by cultured macrophages. *APMIS.* 1988;96:543–51.
8. Gardlo K, Horska Z, Enk CD, Rauch L, Megahed M, Ruzicka T, et al. Treatment of cutaneous leishmaniasis by photodynamic therapy. *J Am Acad Dermatol.* 2003;48:893–6.
9. Asilian A, Davami M. Comparasion between the efficacy of photodynamic therapy and topical paromomycin in the treatment of Old World cutaneous leishmaniasis: A placebo-controlled, randomized clinical trial. *Clin Exp Dermatol.* 2006;31:634–7.
10. Enk CD, Nasereddin A, Alper R, Dan-Goor M, Jaffe CL, Wulf HC. Cutaneous leishmaniasis responds to dayligh-activated photodynamic therapy: Proof of concept for a novel self-administered therapeutic modality. *Br J Dermatol.* 2015;172:1364–70.

L. Sainz-Gaspar,<sup>a,\*</sup> E. Rosón,<sup>a</sup> J. Llovo,<sup>b</sup> H. Vázquez-Veiga<sup>a</sup>

<sup>a</sup> *Servicio de Dermatología, Complejo Hospitalario Universitario, Santiago de Compostela, La Coruña, Spain*

<sup>b</sup> *Servicio de Microbiología y Parasitología, Complejo Hospitalario Universitario, Santiago de Compostela, La Coruña, Spain*

\* Corresponding author.

E-mail address: [laurasainzgaspar@gmail.com](mailto:laurasainzgaspar@gmail.com)

(L. Sainz-Gaspar).

1578-2190/

© 2018 Elsevier España, S.L.U. and AEDV. Published by Elsevier España, S.L.U. All rights reserved.

## Usefulness of 2% Topical Diltiazem in Chondrodermatitis Nodularis Helicis: A Report of 2 Cases<sup>☆</sup>



### Utilidad del diltiazem tópico al 2% en la condrodermatitis nodular del hélix: descripción de 2 casos

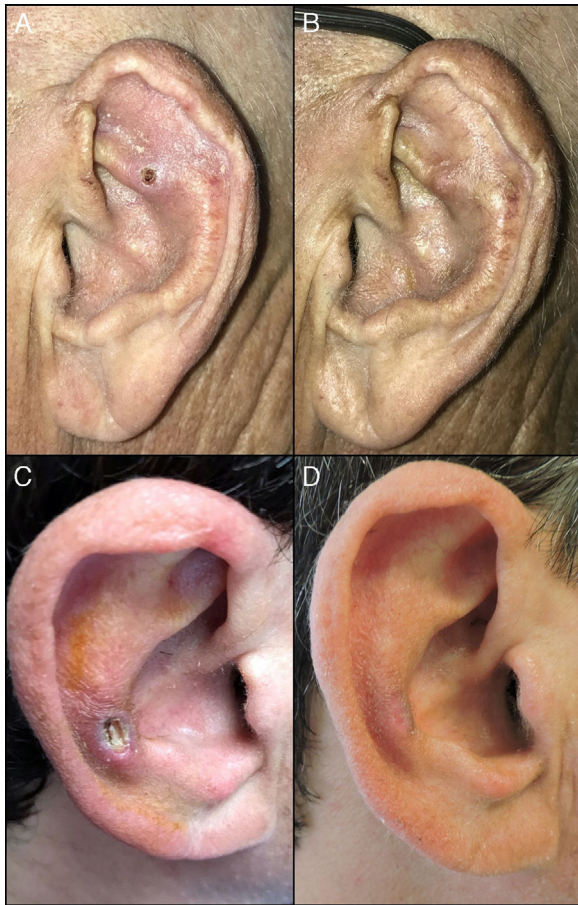
To the Editor:

Chondrodermatitis nodularis helicis (CNH) is a benign inflammatory disease that affects the skin and cartilage of the

helix and, less frequently, the antihelix. Intense pain on touching the affected area is reported by many patients with CNH, necessitating treatment. The etiology of CNH is unknown. However, it has been proposed that prolonged pressure on the atrial and perichondrial cartilage, an anatomical region with little protective subcutaneous cellular tissue, may result in local ischemia followed by transepithelial removal of degenerated material. Consequently, many authors consider CNH a form of perforating dermatosis.<sup>1</sup> Risk factors include chronic actinic damage, exposure to low temperatures, and repeated local trauma.<sup>2</sup> Treatment is challenging. Several therapeutic approaches, with varying cure rates, are described. We present 2 cases of CNH treated successfully with 2% topical diltiazem, a therapeutic option not described to date.

The first patient was a 74-year-old man who was seen for an erythematous nodule with central ulceration on the left antihelix (Fig. 1A). The lesion was painful to the touch and had appeared 4 months earlier. The second patient was a 46-year-old man with a history of chronic hepatitis C virus infection and parenteral drug addiction who was seen for a painful nodule with severe ulceration on

<sup>☆</sup> Please cite this article as: de Quintana-Sancho A, Carnero-González L, González-Pérez R, Drake-Monfort M. Utilidad del diltiazem tópico al 2% en la condrodermatitis nodular del hélix: descripción de 2 casos. *Actas Dermosifiliogr.* 2019;110:251–253.



**Figure 1** A, Patient 1 before starting treatment. B, Patient 1 after finishing treatment with 2% topical diltiazem. C, Patient 2 before starting treatment. D, Patient 2 after finishing treatment with 2% topical diltiazem.

the right antihelix (Fig. 1C). The lesion had appeared 6 months earlier and had not responded to corticosteroids or topical antibiotic treatment. In both cases, a clinical diagnosis of CNH was established and the patients were treated with an extemporaneous preparation of 2% diltiazem gel applied 3 times per day for 3 months (Table 1). No other concurrent treatments were administered during this period. By the end of the treatment period both patients showed marked improvements in the clinical appearance of the lesions and reported almost complete disappearance of the pain (Figs. 1B and 1D). No adverse effects associated with the procedure were observed.

There are a range of therapeutic options for CNH, including cryotherapy, scraping, devices to protect the ear from external pressure, topical or intralesional corticosteroids, carbon dioxide laser, photodynamic therapy with

**Table 1** Extemporaneous Preparation of 2% Diltiazem Gel for the Treatment of CNH

|                              |
|------------------------------|
| Diltiazem hydrochloride: 2 g |
| Propylene glycol: 10 mL      |
| Hydroxyethylcellulose: 2 g   |
| Sterile water to 100 mL      |

methyl-aminolevulinate,<sup>3</sup> and nitroglycerin administered at different concentrations either topically or via a transdermal patch. Cure rates of up to 92% have been reported in patients treated with 2% nitroglycerin gel, the most common adverse effect of which was transient headache (17% of patients).<sup>4,5</sup> Comparable cure rates and markedly better tolerance have been reported in patients treated with 0.2% nitroglycerin.<sup>6</sup> Surgical procedures, of which several are described,<sup>8,9</sup> offer cure rates of up to 82%.<sup>7</sup>

Diltiazem acts by selectively blocking calcium channels in muscle, inducing vasodilation. Oral diltiazem is used to treat arterial hypertension and angina pectoris, and as an antiarrhythmic agent. In CNH, topical diltiazem has an effect similar to that of topical nitroglycerin, inducing relaxation of the arteriolar smooth muscle, restoring local blood flow, and reversing ischemia in cartilage. The low dose of diltiazem administered in topical formulations results in absorption of a very small quantity of the drug, likely reducing the probability of systemic adverse effects.

In general surgery, topical diltiazem has been used successfully for many years for the treatment of chronic anal fissure. In this context, diltiazem has shown greater clinical efficacy than nitroglycerin in randomized controlled trials, and almost no adverse effects.<sup>10</sup>

We have carried out an exhaustive review of the literature and found no existing reports describing the use of topical diltiazem to treat CNH. Further research will be needed to determine whether the use of other excipients (e.g., oil/water emulsion instead of gel) increases the therapeutic efficacy of topical diltiazem. A limitation of this report is that it consists of only 2 clinical cases. Nonetheless, because topical diltiazem shows good efficacy, is well tolerated, and has a known mechanism of action, we feel that it should be considered as a novel therapeutic option for CNH.

## Conflicts of Interest

The authors declare that they have no conflicts of interest.

## References

1. Yoshinaga E, Enomoto U, Fujimoto N, Ohnishi Y, Tajima S, Ishibashi A. A case of chondrodermatitis nodularis chronica helicis with an autoantibody to denatured type II collagen. *Acta Derm Venereol.* 2001;81:137–8.
2. Wagner G, Liefelth J, Sachse MM. Clinical appearance, differential diagnoses and therapeutical options of chondrodermatitis nodularis helicis Winkler. *J Dtsch Dermatol Ges.* 2011;9:287–91.
3. García-Malinis AJ, Turrión-Merino L, Pérez-García B, Saceda-Corralo D, Harto-Castaño A, Gilaberte Y. Observational study of chondrodermatitis nodularis helicis treated with methyl aminolevulinate photodynamic therapy. *J Am Acad Dermatol.* 2017;76:1103–8.
4. Flynn V, Chisholm C, Grimwood R. Topical nitroglycerin: a promising treatment option for chondrodermatitis nodularis helicis. *J Am Acad Dermatol.* 2011;65:531–6.
5. Yélamos O, Dalmau J, Puig L. Chondrodermatitis nodularis helicis tratada con éxito con nitroglicerina al 2% en gel. *Actas Dermosifiliogr.* 2013;104:531–2.
6. Sanz-Motilva V, Martorell-Calatayud A, Gutiérrez García-Rodrigo C, Hueso-Gabriel L, García-Melgares ML, Pelufo-Enguix C,

- et al. La utilidad de la nitroglicerina tópica al 0,2% en la condrodermatitis nodular del hélix. *Actas Dermosifiliogr.* 2015;106:555–61.
7. Kechichian E, Jabbour S, Haber R, Abdelmassih Y, Tomb R. Management of chondrodermatitis nodularis helicis: a systematic review and treatment algorithm. *Dermatol Surg.* 2016;42:1125–34.
  8. Bruns NM, Hessam S, Valavanis K, Scholl L, Bechara FG. Surgical treatment of chondrodermatitis nodularis helicis via a retroauricular incision. *J Dtsch Dermatol Ges.* 2015;13:1049–52.
  9. De Ru JA, Lohuis PJ, Saleh HA, Vuyk HD. Treatment of chondrodermatitis nodularis with removal of the underlying cartilage alone: Retrospective analysis of experience in 37 lesions. *J Laryngol Otol.* 2002;116:677–81.
  10. Puche JJ, García-Coret MJ, Villalba FL, Ali-Mahmoud I, Roig JV. Local treatment of a chronic anal fissure with diltiazem vs nitroglycerin. A comparative study. *Cir Esp.* 2010;87:224–30.
- A. de Quintana-Sancho,<sup>a,\*</sup> L. Carnero-González,<sup>b</sup> R. González-Pérez,<sup>b</sup> M. Drake-Monfort<sup>a</sup>
- <sup>a</sup> *Servicio de Dermatología, Hospital Universitario Marqués de Valdecilla, Santander, Spain*  
<sup>b</sup> *Servicio de Dermatología, Hospital Universitario de Araba, Vitoria, Spain*
- \* Corresponding author.  
 E-mail address: [adriandeq@gmail.com](mailto:adriandeq@gmail.com) (A. de Quintana-Sancho).  
 1578-2190/  
 © 2018 Elsevier España, S.L.U. and AEDV. Published by Elsevier España, S.L.U. All rights reserved.

## Coexistence of Tumid Lupus Erythematosus and Discoid Lupus Erythematosus<sup>☆</sup>



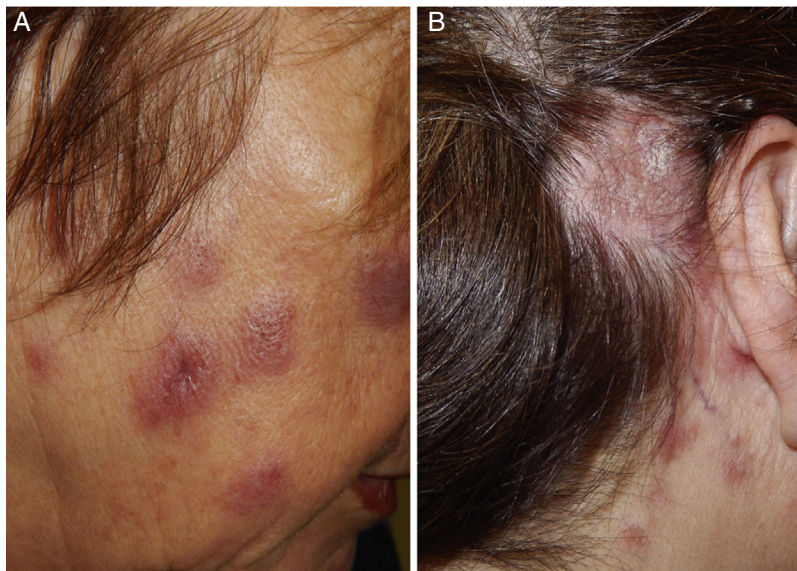
### Coexistencia de lupus eritematoso tómico y lupus eritematoso discoide

To the Editor:

In 1909 the term lupus erythematosus tumidus was coined by Hoffmann,<sup>1</sup> and in 1930 Gougerot and Burnier<sup>2</sup> described the cases of 5 patients with similar clinical pictures consisting of

nonscarring, erythematous, indurated facial lesions without surface changes. This condition, also known as tumid lupus erythematosus (TLE), has been largely overlooked in the literature, but has been recently characterized as a subtype of cutaneous lupus erythematosus (CLE) with peculiar clinical, photobiological, histological, and prognostic features.

A 70-year-old woman with a history of hypertension and Hashimoto thyroiditis was seen for asymptomatic skin lesions on the face that had appeared during the summer 5 months earlier and were not associated with any systemic clinical signs. The appearance of the facial lesions coincided with worsening of pre-existing lesions on the scalp and associated hair loss.



**Figure 1** A, Succulent, erythematous-violaceous facial plaques, without surface changes. B, Brownish, desquamative, alopecic erythematous plaque located in the retroauricular area of the scalp.

<sup>☆</sup> Please cite this article as: Abadías-Granado I, Sánchez-Bernal J, Felipo-Berlanga F, Ara-Martín M. Coexistencia de lupus eritematoso tómico y lupus eritematoso discoide. *Actas Dermosifiliogr.* 2019;110:253–255.