



ACTAS Derma-Sifiliográficas

Full English text available at
www.actasdermo.org



E-IMAGES IN DERMATOLOGY

Torus Palatinus[☆]

Torus palatinus



E. Rozas-Pérez,^a C. Bravo,^a E. Rozas-Muñoz^{b,*}

^a Departamento de Estomatología, Facultad de Odontología, Universidad de Concepción, Concepción, Chile

^b Servicio de Dermatología, Hospital de la Santa Creu i Sant Pau, Barcelona, España

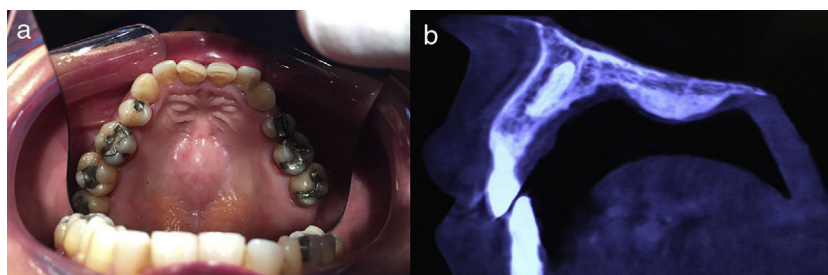


Figure 1

A 70-year old man was referred to the dermatology department for evaluation of a solitary mass on the roof of his palate. He reported that the lesion had been present since birth, but he was concerned because it had increased in size, causing difficulty during eating. Physical examination revealed a nontender, nodular protuberance, with normal overlying mucosa, located along the longitudinal ridge of the hard palate (fig. 1a). The patient's medical history was unremarkable and the rest of the physical examination disclosed no abnormalities. Tomographic examination revealed

a concentric radiopaque image in the region of the hard palate, confirming the clinical diagnosis of torus palatinus (fig. 1b). Since the patient complained of discomfort, surgical excision was performed.

Torus palatinus is a benign congenital outgrowth of the bone that affects the hard palate and palatine processes. It is the most common intraoral exostosis with an estimated prevalence of 20% in the general population, being more frequent in women and certain ethnic groups such as blacks.

Its etiology is still unknown, and a combination of genetic and environmental factors have been proposed as possible etiological culprits. Since the lesions are benign and usually asymptomatic treatment is not warranted. In case of discomfort, prosthetic treatment, or need for autogenous bone grafting, surgical removal can be performed.

[☆] Please cite this article as: Rozas-Pérez E, Bravo C, Rozas-Muñoz E. Torus palatinus. Actas Dermosifiliogr. 2019;110:e6.

* Corresponding author.

E-mail address: docrozas@yahoo.com (E. Rozas-Muñoz).