

Three Cases of Scalp Sarcoidosis with Alopecia[☆]



Tres casos de sarcoidosis del cuero cabelludo con alopecia

To the Editor:

Scalp sarcoidosis is a relatively infrequent disease that mainly affects African-American women.¹ To date, very few cases of this disease have been described. We describe 3 patients with scalp sarcoidosis, which manifested as infiltrated plaques with alopecia.

Case 1. The patient was a 50-year-old woman who was admitted to our hospital with exertional dyspnea, photophobia, and skin rash. The physical examination revealed several indurated brown plaques on both lower limbs, as well as partial, irregularly distributed alopecia and scaling erythema (Fig. 1A). Radiography and computed tomography (CT) of the thorax revealed bilateral hilar lymphadenopathy (BHL) and mediastinal lymphadenopathy. Serum levels of angiotensin converting enzyme (ACE) were elevated (72.8 U/L; normal range, 7–25 U/L). The patient had a negative reaction in the tuberculin test. The ophthalmological examination revealed uveitis. Biopsy of the scalp showed non-necrotizing epithelioid granulomas located in the upper to mid dermis with minimal lymphocytic infiltration (Fig. 1B). Naked granulomas were also detected in

another sample taken from the leg. The patient was treated with local topical steroids, to which she responded poorly.

Case 2. The patient was a 51-year-old man who was referred to our department with pulmonary sarcoidosis and uveitis. He complained of blurred vision. The ophthalmological examination revealed nodules in the iris, inflammation of the anterior segment, and vitreous opacity. Radiography and a chest CT scan revealed BHL. Serum ACE levels were elevated (64.5 U/L). The patient had a negative reaction in the tuberculin test. The physical examination revealed indurated reddish-brown plaques and regularly distributed areas of alopecia with black spots on the scalp (Fig. 1C), as well as dark red subcutaneous nodules on the legs. Biopsies of the scalp and legs revealed sarcoid granulomas located in the dermis (Fig. 1D). The patient was treated with local topical steroids, to which he responded poorly.

Case 3. The patient was a 71-year-old man who was referred to our department with uveitis. He reported skin rash on the scalp and the right leg. Physical examination of the scalp revealed multiple erythematous, scaly, indurated areas and an egg-sized, indurated alopecic plaque with black spots (Fig. 1E). There were dark red subcutaneous nodules on the right leg. Radiography and a chest CT scan revealed BHL. Serum ACE levels were elevated (42.5 U/L). The patient had a negative reaction in the tuberculin test. He complained of myodesopsia and the ophthalmological examination revealed iritis and lens opacity. Biopsy of the plaque on the scalp showed sarcoid granulomas extending from the mid to deep dermis (Fig. 1F). The patient was

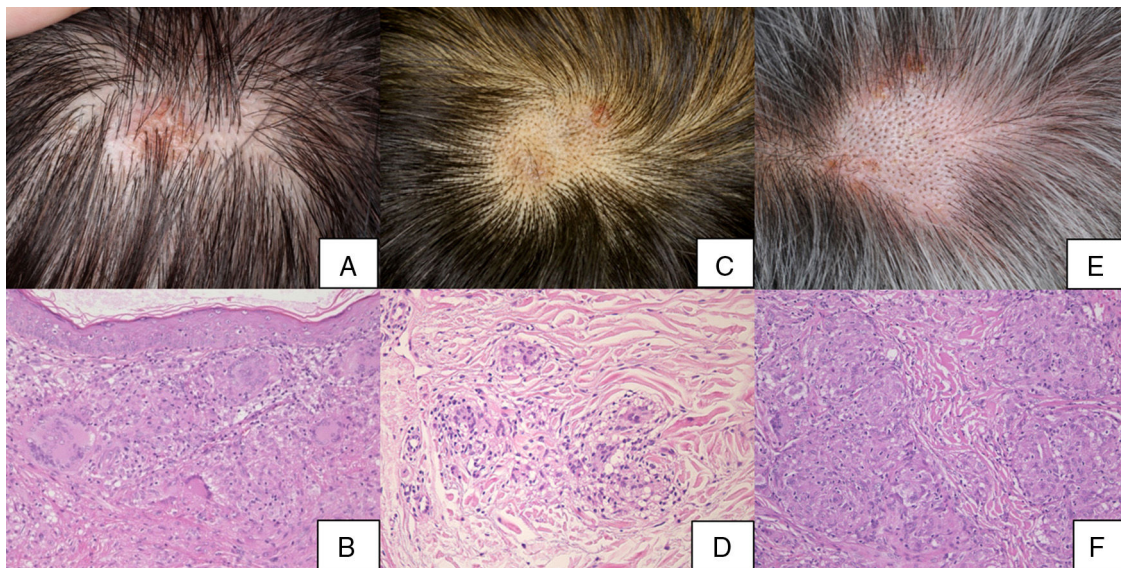


Figure 1 Clinical and histological characteristics of scalp sarcoidosis (hematoxylin-eosin staining, original magnification $\times 200$). A and B, Case 1. C and D, Case 2. E and F, Case 3.

[☆] Please cite this article as: Ishikawa M, Ohtsuka M, Yamamoto T. Three Cases of Scalp Sarcoidosis with Alopecia. *Actas Dermosifiliogr.* 2018;109:933–934.

treated with local topical steroids, to which he responded poorly.

All 3 patients were treated with local topical steroids, with a poor outcome in all cases. No systemic treatments were administered.

The clinical presentation of scalp sarcoidosis consists of indurated verrucous plaques and nodular lesions, often accompanied by alopecia, and can resemble that of discoid lupus erythematosus, necrobiosis lipoidica, organoid nevus, and cicatricial alopecia.¹⁻⁵ In general, scalp sarcoidosis is accompanied by sarcoid skin lesions in other locations.^{1,2} Our 3 patients had infiltrated plaques with alopecia. Unfortunately, a trichoscopic examination, which is necessary to identify the trichoscopic features of scalp sarcoidosis, was not performed prior to biopsy. The alopecia may have been a consequence of the effects of the sarcoid granuloma on the follicles or of follicular replacement by the granuloma. All 3 patients had cutaneous sarcoidosis on the legs as well as the scalp. Sarcoidosis of other organs is common in patients with scalp sarcoidosis, and pulmonary and ophthalmologic sarcoidosis was observed in all 3 patients. In most cases, scalp sarcoidosis affects patients with active systemic sarcoidosis. We have previous experience with 2 other cases of scalp sarcoidosis in which biopsies were taken from locations other than the scalp. In both cases the patients' alopecia was strongly suggestive of sarcoidosis. Scalp involvement is common in cases of cutaneous sarcoidosis, and therefore a careful examination of the scalp should be performed if sarcoidosis is suspected. Indeed, scalp sarcoidosis may be less rare than previously thought. It is therefore important to include a scalp examination in the clinical examination of sarcoidosis patients.

Conflicts of Interest

The authors declare that they have no conflicts of interest.

References

1. Katta R, Nelson B, Chen D, Roenigk H. Sarcoidosis of the scalp: A case series and review of the literature. *J Am Acad Dermatol.* 2000;42:690-2.
2. La Placa M, Vincenzi C, Misciali C, Tosti A. Scalp sarcoidosis with systemic involvement. *J Am Acad Dermatol.* 2008;59:S126-7.
3. Henderson CL, Lafleur L, Sontheimer RD. Sarcoidal alopecia as a mimic of discoid lupus erythematosus. *J Am Acad Dermatol.* 2008;59:143-5.
4. Harman KE, Calonje E, Robson A, Black MM. Sarcoidosis presenting as a scarring alopecia resembling necrobiosis lipoidica. *Clin Exp Dermatol.* 2003;28:565-6.
5. Yamamoto T, Yokozeki H. Scalp sarcoidosis mimicking organoid nevus. *Eur J Dermatol.* 2015;25:78-9.

M. Ishikawa,* M. Ohtsuka, T. Yamamoto

Departamento de Dermatología, Universidad de Medicina de Fukushima, Fukushima, Japón

* Corresponding author.

E-mail address: ishimasa@fmu.ac.jp (M. Ishikawa).

9 June 2017 21 November 2017

1578-2190/

© 2018 Elsevier España, S.L.U. and AEDV. Published by Elsevier España, S.L.U. All rights reserved.

Stewart-Bluefarb Syndrome: Case Report and Review of the Literature[☆]



Síndrome de Stewart-Bluefarb: caso clínico y revisión de la literatura

To the Editor:

Stewart-Bluefarb syndrome (SBS), also known as pseudo-Kaposi sarcoma, is a very rare subtype of angiodermatitis associated with congenital arteriovenous malformations (AVMs). We report a case of SBS and review the literature on this disease.

A 46-year-old man was referred to our unit for assessment of a painful, slow-growing ulcer on the lower right limb that had first appeared 3 months earlier. The patient had dyslipidemia and was an active smoker. The patient presented

with raised, self-limiting brownish papular lesions that had recurred since childhood and had never been diagnosed. Physical examination revealed symmetrical, bilateral palpable pulses without bruit or thrill, raised brownish-violaceous tumors in the pretibial and outermost supramalleolar region, perilesional eczema, and an ulcer measuring 3 × 2 cm with irregular borders, a fibrinous base, and mild signs of infection (Fig. 1), with no dysmetria of the lower limbs. Complete blood count, biochemistry, and serologic tests were negative or normal. Given the presence of atypical skin lesions, a complete Doppler ultrasound examination was performed on both limbs and a skin biopsy was carried out.

Histologic examination revealed the proliferation of capillaries in the deep dermis and papillary dermis, fibrosis, extravasated red blood cells, hemosiderin deposits, and tortuous vessels consistent with SBS. Doppler ultrasound confirmed the presence of underlying arteriovenous fistulas of the anterior and posterior tibial arteries with arterialized venous flow distal to the fistulas (Fig. 2).

Conservative treatment with 10 days of targeted antibiotic therapy was initiated after microbiologic culture detected the presence of *Staphylococcus aureus*. Compression therapy was also initiated with 2-in-1 compression stockings with a lateral zipper, as well as local wound care with a lipido-colloid dressing. At 3 months, the ulcer had healed and the pain had disappeared. The patient

[☆] Please cite this article as: García Blanco VE, Doiz Artázcov E, Galera Martínez MC, Rodríguez Piñero M. Síndrome de Stewart-Bluefarb: caso clínico y revisión de la literatura. *Actas Dermosifiliogr.* 2018;109:934-936.