

structures are absent. Sclerodermiform basal cell carcinoma lacks ductal structures containing amorphous material. Finally, stellate sclerosis, which is absent in syringoma, is very common in the benign condition known as sclerosing adenosis of the sweat glands.^{4,5}

Acral syringoma is limited to the distal areas of the upper and/or lower extremities. This form is very rare, and only a few cases are described in the literature (Table 1).^{6,7} Distinctive characteristics of this form include onset at more advanced ages and a similar prevalence in men and women.^{6,8} Concomitant periorbital involvement is absent in most reported cases. It is important to highlight the occasional association of acral syringoma with malignant tumors, including pulmonary carcinoid tumor, cutaneous melanoma, basal cell carcinoma, breast carcinoma, and promyelocytic leukemia.⁶⁻⁸ Our patient was a healthy woman with no symptoms and no known tumors.

The differential diagnosis of papular acral lesions should include syringoma, as well as lichen planus, milium cysts, urticaria pigmentosa, flat warts, and certain photodermatoses.^{8,9}

Given the benign nature of the process treatment is not required, although aesthetic or symptomatic treatment is often instituted. Available therapeutic options include surgical excision, electrocoagulation, cryotherapy, laser ablation, topical retinoids, and trichloroacetic acid.

Conflicts of Interest

The authors declare that they have no conflicts of interest.

References

- Hughes PS, Apisarnthanarax P. Acral syringoma. *Arch Dermatol*. 1977;113:1435-6.
- Friedman SJ, Butler DF. Syringoma presenting as milia. *J Am Acad Dermatol*. 1987;16:310-4.
- Dupré A, Carrère S, Bonafé JL, Christol B, Lassère J, Tournon P. Syringomes éruptifs généralisés, grains de milium et atrophodermie vermiculée. Syndrome de Nicolau et Balus. *Dermatologica*. 1981;162:281-6.
- Klein W, Chan E, Seykora JT. Tumors of the epidermal appendages. In: Elder DE, Elenitsas R, Johnson BL Jr, Murphy GF, editors. *Lever's Histopathology of the skin*. 9th ed. Philadelphia: Lippincott Williams & Wilkins; 2005. p. 900.
- Henner MS, Shapiro PE, Ritter JH, Leffell DJ, Wick MR. Solitary syringoma: Report of five cases and clinicopathologic comparison with microcystic adnexal carcinoma of the skin. *Am J Dermatopathol*. 1995;5:465-70.
- Valdivielso-Ramos M, de la Cueva P, Gimeno M, Hernanz JM. Acral syringomas. *Actas Dermosifiliogr*. 2010;101:458-60.
- Varas-Meis E, Prada-García C, Samaniego-González E, Rodríguez Prieto MA. Acral syringomas associated with hematological neoplasm. *Indian J Dermatol Venereol Leprol*. 2017;83:136.
- Iglesias Sancho M, Serra Llobet J, Salleras Redonnet M, Sola Casas MA, Creus Vila L, Sánchez Regaña M, et al. Siringomas diseminados de inicio acral, aparecidos en la octava década. *Actas Dermosifiliogr*. 1999;90:253-7.
- Martín-García RF, Muñoz CM. Acral syringomas presenting as a photosensitive papular eruption. *Cutis*. 2006;77:33-6.

C. Gómez-de Castro,^{a,*} B. Vivanco Allende,^b
B. García-García^a

^a Servicio de Dermatología, Hospital Universitario Central de Asturias, Oviedo, Asturias, España

^b Servicio de Anatomía Patológica, Hospital Universitario Central de Asturias, Oviedo, Asturias, España

* Corresponding author.

E-mail address: celiagomez.88@hotmail.com

(C. Gómez-de Castro).

1578-2190/

© 2017 Elsevier España, S.L.U. and AEDV. Published by Elsevier España, S.L.U. All rights reserved.

Ultrasound Assessment of a Subcutaneous Eumycetoma of the Eyebrow in an Immunocompromised Patient[☆]



Evaluación ecográfica de un eumicetoma subcutáneo ciliar en una paciente inmunodeprimida

To the Editor:

A 74-year-old Spanish woman who had a history of type 2 diabetes mellitus and high blood pressure, had undergone

a kidney transplant in 2013 due to chronic renal failure secondary to diabetes, and was receiving immunosuppressant treatment with tacrolimus (1 mg/12 h), everolimus (1 mg/12 h), and prednisone (5 mg/24 h) was seen in the Dermatology Department for asymptomatic lesions on the right eyebrow that had appeared 2 months earlier and had grown progressively. The patient reported no history of trauma in the affected area. Physical examination revealed 2 painless nodules on the right eyebrow of 1 cm in diameter that were the same color as the neighboring skin and showed no signs of associated phlogosis (Fig. 1A and B).

Skin ultrasound (MyLab 25 Gold; Esaote SpA, Genoa, Italy) in B mode using an 18-MHz probe revealed the presence in the subdermis of 2 well-delimited, rounded, hypochoic/anechoic structures with posterior reinforcement and lateral acoustic shadowing (Fig. 1C). Color Doppler mode revealed an increase in perilesional flow (Fig. 1D). There was no evidence of involvement of adjacent muscle or bone. Suspecting simple cysts, the lesions were excised and samples sent for pathologic examination and culture.

[☆] Please cite this article as: Combalia A, Giavedoni P, Pigem R, Mascaró Jr JM. Evaluación ecográfica de un eumicetoma subcutáneo ciliar en una paciente inmunodeprimida. *Actas Dermosifiliogr*. 2018;109:836-838.

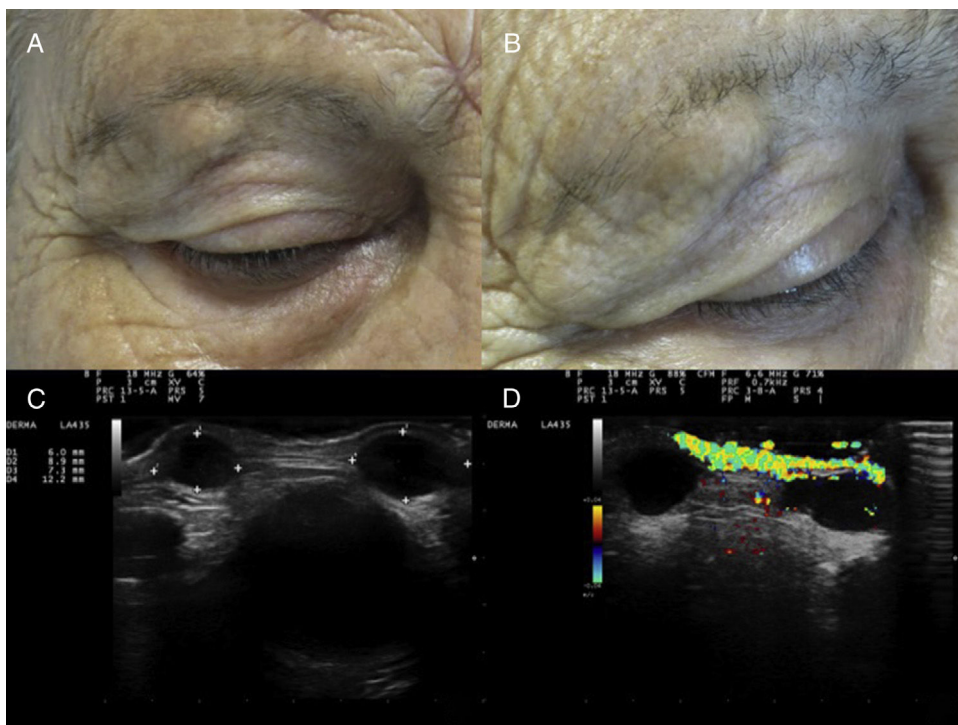


Figure 1 A and B, Two painless, skin-colored nodules of 1 cm in diameter on the right eyebrow, showing no signs of associated phlogosis. C, B-mode skin ultrasound (18-MHz probe) showing 2 well-delimited, rounded, hypoechoic/anechoic subdermal structures with posterior reinforcement and lateral acoustic shadowing. D, Color Doppler skin ultrasound (18-MHz probe) showing increased perilesional flow.

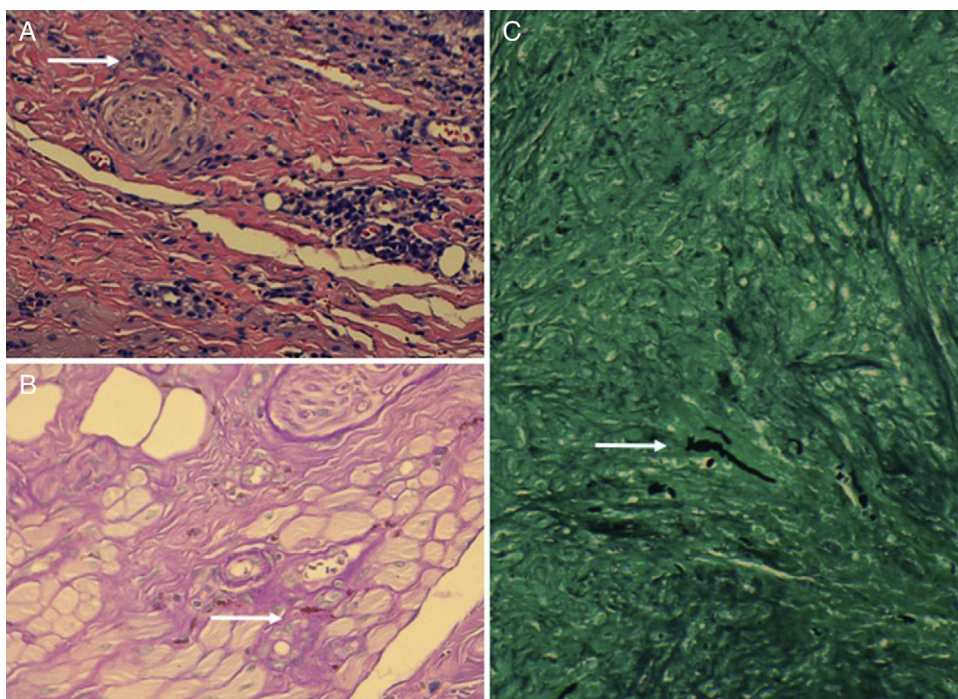


Figure 2 A, Granulomas and multinucleated giant cells (hematoxylin-eosin, original magnification $\times 200$). White arrow indicates one of the multinucleated giant cells. B, Tortuous hyphae (periodic acid-Schiff, original magnification $\times 400$). White arrow indicates one of the hyphae. C, Tortuous hyphae (silver staining, original magnification $\times 200$). White arrow indicates one of the hyphae.

Hematoxylin-eosin staining revealed the presence of granulomas with a necrotic center and associated tortuous hyphae, which were visualized by periodic acid-Schiff and silver staining (Fig. 2). Lesion culture was positive for *Fusarium* species, and polymerase chain reaction sequencing confirmed the presence of *Fusarium solani*. Based on these findings, a diagnosis of fungal infection with secondary granulomatous reaction was established. Analysis of disease progression ruled out local invasion and associated systemic infection. Following consultation with the infection service it was decided not to administer specific systemic treatment, and complete excision of the lesions was selected as a curative treatment. After 8 months of follow-up the patient remains asymptomatic without lesion recurrence.

Mycetoma is a disease typical of tropical and subtropical regions, where it constitutes a major health problem.¹ It is a locally destructive, chronic, slowly progressing and often painless infection of the skin, subcutaneous tissue, aponeurosis, muscle, and bone² that is difficult to diagnose and treat. It is usually caused by traumatic implantation of fungi (eumycetoma) or bacteria (actinomycetoma). Eumycetoma caused by *Fusarium* species is rare.¹ *F. solani* is a dimorphic fungus that forms chlamydospores and causes an infection in humans known as fusariosis. It is found in contaminated soil and water, and is usually inoculated into the skin of farmers or construction workers, or after accidental trauma. Infection of the face is unusual; the most commonly affected areas are the feet and/or hands.³ Diagnosis is based on identification of the causative organism. This can be facilitated by the use of biopsy and/or ultrasound-guided fine-needle aspiration.

The ultrasound image of subcutaneous eumycetoma can resemble that of a simple cyst with peripheral hypervascularization, and may reveal the presence in the cyst interior of multiple hyperechoic granules,^{3,4} which can facilitate differential diagnosis with actinomycetoma.⁴ The so-called dot-in-circle sign, a central hyperechoic focus (dot) within a hypoechoic area (circle), is a very specific ultrasound marker of eumycetoma in soft tissue and bone,⁵ although the presence of this sign is reported in very few cases in the literature. This finding has also been described in nuclear magnetic resonance images.³

In our patient, skin ultrasound revealed the presence of cyst-like nodules with rich peripheral vascularization, but not the dot-in-circle sign, which could have helped

establish diagnosis. It is important to include subcutaneous eumycetoma in the differential diagnosis of lesions of cystic appearance in immunocompromised patients, and to remember that skin ultrasound is a useful tool for distinguishing this lesion type from other skin lesions. In our patient, fungal inoculation may have occurred due to trauma, despite the patient's claims to the contrary.

Conflicts of Interest

The authors declare that they have no conflicts of interest.

References

1. Salas-Coronas J, Cabezas-Fernández T, Martínez-Lage MJ, Villarejo-Ordóñez A. Mycetoma caused by *Fusarium solani*. *Rev Clin Esp*. 2011;211:e16–8 [Article in Spanish].
2. Tomimori-Yamashita J, Ogawa MM, Hirata SH, Fischman O, Michalany NS, Yamashita HK, et al. Mycetoma caused by *Fusarium solani* with osteolytic lesions on the hand: Case report. *Mycopathologia*. 2002;153:11–4.
3. Fahal AH, Mahgoub el S, El Hassan AM, Abdel-Rahman ME. Mycetoma in the Sudan: An update from the Mycetoma Research Centre, University of Khartoum, Sudan. *PLoS Negl Trop Dis*. 2015;9:e0003679.
4. Fahal AH, Skeik HE, Homeida MMA, Arabi Y, Mahgoub ES. Ultrasonographic imaging of mycetoma. *Br J Surg*. 1997;84:1120–2.
5. Laohawiriyakamol T, Tanutit P, Kanjanapradit K, Hongsakul K, Ehara S. The «dot-in-circle» sign in musculoskeletal mycetoma on magnetic resonance imaging and ultrasonography. *Springerplus*. 2014;3:671.

A. Combalia,* P. Giavedoni, R. Pigem, J.M. Mascaró Jr

Servicio de Dermatología, Hospital Clínic de Barcelona, Barcelona, España

* Corresponding author.

E-mail address: andreacombalia@gmail.com (A. Combalia). 1578-2190/

© 2018 Elsevier España, S.L.U. and AEDV. Published by Elsevier España, S.L.U. All rights reserved.