




ACTAS Derma-Sifiliográficas

Full English text available at
www.actasdermo.org



IMAGES IN DERMATOLOGY

Huge Squamous Cell Carcinoma Arising on Severe Hidradenitis Suppurativa[☆]



Carcinoma de células escamosas grandes a partir de un cuadro de hidradenitis supurativa grave

T. Miura,* M. Ishikawa, T. Mori, Y. Hanami, M. Ohtsuka, T. Yamamoto

Unidad de Dermatología, Facultad de Medicina, Universidad de Fukushima, Fukushima, Japón

A 45-year-old man developed painful ulcerative lesions on the buttock. He was a trucker driving long distance and was suffering from occasional discharges from the inflamed lesions of the buttocks for over 20 years. He was a smoker (25 tobaccos a day) over 25 years. Physical examination revealed coalesced large erosive and ulcerative lesions, granulation, ulcerative reddish nodules covered with necrotic tissues on the buttock and the flexor aspects of the thighs (Fig. 1). Laboratory examination showed slight anemia, but liver and renal functions were normal. C-reactive protein was elevated (4.38 mg/dl), and squamous cell carcinoma (SCC)-related antigen was 3.3 ng/ml (normal <1.5). Bacterial cultures yielded *Pseudomonas aeruginosa*. Two biopsy specimens were taken, which showed similar features such as proliferation of highly atypical squamous cells in the dermis, which were immunoreactive for pancytokeratin (AE1/3), E-cadherin, and epithelial membrane antigen, but negative for vimentin and N-cadherin. We made a diagnosis of poorly-differentiated SCC arising severe hidradenitis suppurativa (Hurley stage III) involving the buttocks and thighs.

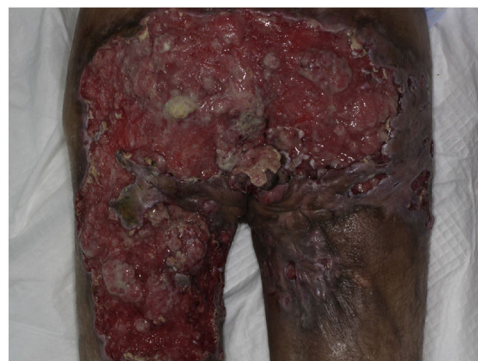

Figure 1

Neither HPV 16 nor 68 were detected by HPV typing. Detailed examination revealed inguinal lymph node and lung metastases (T3N2M0, stage IV). Radiation therapy was started but he died of multiple organ failure 4 months later.

[☆] Please cite this article as: Miura T, Ishikawa M, Mori T, Hanami Y, Ohtsuka M, Yamamoto T. Carcinoma de células escamosas grandes a partir de un cuadro de hidradenitis supurativa grave. Actas Dermosifiliogr. 2018;109:828.

* Corresponding author.

E-mail address: m-takako@fmu.ac.jp (T. Miura).