

8. Pellacani G, Cesinaro A, Seidenari S. Reflectance-mode confocal microscopy for the in vivo characterization of pagetoid melanocytosis in melanomas and nevi. *J Invest Dermatol*. 2005;125:532–7.
9. Van Raamsdonk C, Bezrookove V, Green G, Bauer J, Gaugler L, O'Brien J, et al. Frequent somatic mutations of GNAQ in uveal melanoma and blue naevi. *Nature*. 2008;457:599–602.
10. Buntinx-Krieg T, Ouyang J, Cartwright M. An orbital malignant melanoma arising in cellular blue nevus in a patient with nevus of Ota. *Cureus*. 2016;8:698.

L. Diluvio,\* M. Mazzeo, L. Bianchi, E. Campione

*Unidad de Dermatología, Universidad de Roma Tor Vergata, Roma, Italia*

\*Corresponding author.

E-mail address: [lauradiluvio@yahoo.it](mailto:lauradiluvio@yahoo.it) (L. Diluvio).  
1578-2190/

© 2017 Elsevier España, S.L.U. and AEDV. Published by Elsevier España, S.L.U. All rights reserved.

## Enfermedad de Rosai-Dorfman cutánea: una nueva presentación clínica<sup>☆</sup>



### Cutaneous Rosai-Dorfman Disease: A Novel Clinical Presentation

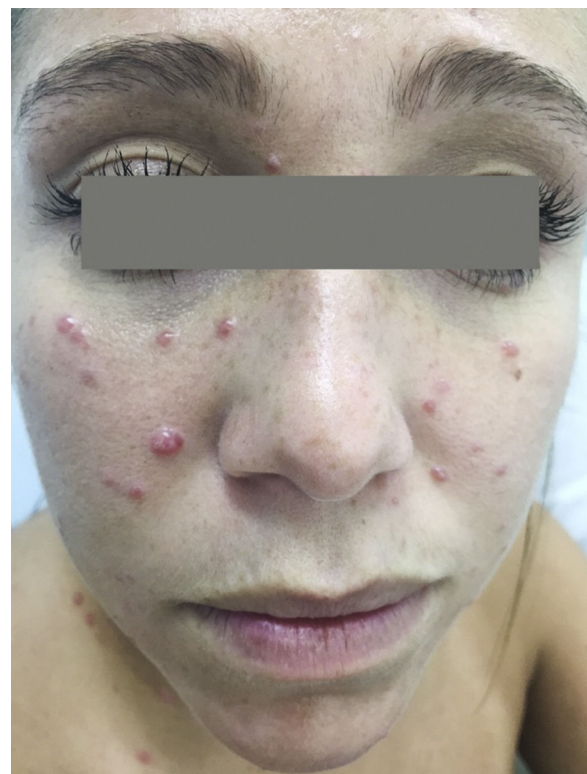To the Editor:

A 21-year-old woman presented with a 3-month history of a diffuse asymptomatic eruption on her face and trunk. She denied fever or any other constitutional symptoms and her review of symptoms was non-contributory. She denied any pertinent past medical or family history. Her only medication included norgestimate/ethinyl estradiol which she had been taking for several years. Physical examination revealed diffuse scattered non-follicular based flesh-colored papules and small nodules. Many lesions demonstrated a central indentation resembling molluscum contagiosum (see [Figures 1 & 2](#)). She did not have any cervical, axillary, or inguinal lymphadenopathy. Mucous membrane examination was unremarkable and lacrimal glands did not appear enlarged. Routine histologic examination of her right neck lesion revealed a dense nodular dermal mononuclear cell rich infiltrate showing a significant number of plasma cells and numerous scattered S100 positive multinucleated histiocytes with marked emperipolesis and inconspicuous eosinophils (see [Figure 3](#)). Complete blood count with differential, erythrocyte sedimentation rate, lactate dehydrogenase, liver transaminases, alkaline phosphatase, bilirubin, and creatinine were negative or within normal limits. Chest and abdominal magnetic resonance imaging were normal. She was treated with a 60mg oral prednisone taper over six months which resulted in complete resolution of her skin lesions. Follow up at 10 months from onset of disease demonstrated complete remission.

Rosai-Dorfman Disease (RDD) is a relatively rare histiocytic proliferation disorder that was first described in 1969.<sup>1</sup> Though RDD classically presents with bilateral massive lymphadenopathy and systemic symptoms, it typically

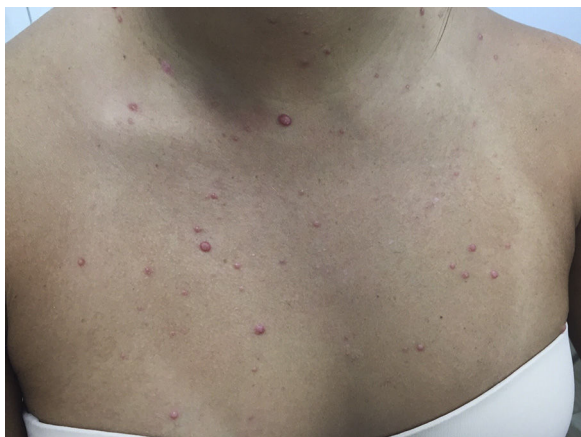has a benign clinical course and favorable prognosis. In RDD, 43% of patients have involvement of other extranodal sites with skin being the most common site.<sup>2</sup> Though skin comprises 10% of extranodal sites involved, approximately 3% are solely cutaneous Rosai-Dorfman Disease (CRDD) without any nodal or other extranodal sites.<sup>3</sup> While incidence is reportedly low, CRDD is more prevalent in middle-aged White and Asian women.<sup>2</sup> The etiology of RDD is unclear although immunologic,<sup>4</sup> viral, and genetic causes including SLC29A3 mutations have been hypothesized.<sup>5</sup>

The classic presentation of CRDD is a relatively asymptomatic self-involving nodulo-plaque with surrounding satellite papules.<sup>3</sup> However, an evolving wide spectrum of clinical morphologic presentations have been reported. The most common site involved is the face, followed by thigh, and trunk. Recurrence has been reported to occur within 1

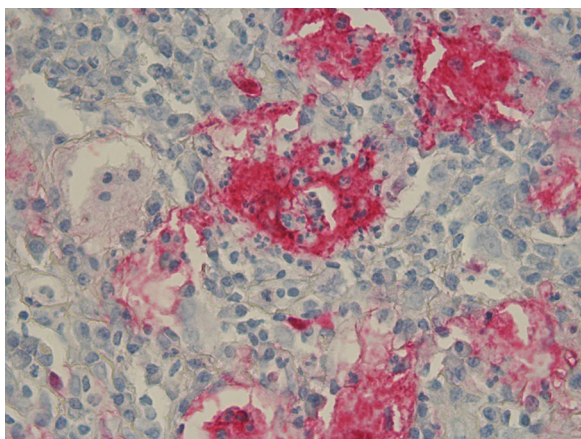


**Figure 1** Diffuse scattered non-follicular based flesh-colored papules and small nodules, some with central indentations, were seen on the face and the trunk.

<sup>☆</sup> Please cite this article as: Conde JM, Kim AY, de Miguel R, Nousari CH. Enfermedad de Rosai-Dorfman cutánea: una nueva presentación clínica. *Actas Dermosifiliogr*. 2018;109:655–657.



**Figure 2** Diffuse scattered non-follicular based flesh-colored papules and small nodules, some with central indentations, were seen on the face and the trunk.



**Figure 3** Histopathological features. Dense nodular dermal mononuclear cell rich infiltrate showing a significant number of plasma cells and numerous scattered S100 positive multinucleated histiocytes with marked emperipolesis and inconspicuous eosinophils.

to 3.5 years.<sup>6</sup> To the best of our knowledge, this will be the first description of RDD mimicking molluscum contagiosum.

The pathognomonic histologic finding of RDD is emperipolesis of intact lymphocytes by S100 and CD68 positive as well as CD1a and langerin negative pale histiocytes characterized also by vesicular nuclei and small nucleoli. Of note, emperipolesis entitles the presence of engulfing of intact hematologic cells, as opposed to hemophagocytosis which degrades engulfed cells, by histiocytes or megakaryocytes. The so called "Rosai-Dorfman cell" is a type of histiocyte characterized by emperipolesis of only haloed lymphocytes.

These characteristic histiocytes can be abundant or inconspicuously scattered amidst other inflammatory cells.<sup>7</sup> Plasma cells are virtually present in all lesions of CRDD. Polymorphonuclear cells, namely eosinophils, are frequently found in skin lesions. Increased vascularity with plump endothelium, with or without fibrosis, are not uncommonly identified namely in long standing lesions.

Emperipolesis in cutaneous disorders has been traditionally related to RDD until recent descriptions of other disorders related to the so-called H syndrome.<sup>8</sup> This disorder is characterized by hyperpigmentation, hypertrichosis, hearing loss, heart anomalies, hepatosplenomegaly, hypogonadism, and hallux valgus<sup>9</sup> and is caused by a mutation in the SLC29A3 gene. Many authors believe that syndromes associated with mutations in SLC29A3 including familial RDD and pigmented hypertrichosis with insulin-dependent diabetes,<sup>5</sup> in addition to H syndrome, fall into the same spectrum of RDD.

Recognition of the pleomorphic genetic and phenotypic presentations of SCL29A3-related diseases is important for diagnosis and for consideration in the histopathologic differential diagnosis of emperipolesis. In addition to SCL29A3-related diseases, IgG4-related diseases have also been shown to have some overlap with RDD as a subset of RDD has been found to contain increased numbers of IgG4-positive plasma cells.<sup>4</sup> However, much controversy remains regarding this.

Currently there is no standard guideline for the management of CRDD. The clinical course of CRDD is usually benign and self-limited. Spontaneous resolution varies and ranges from months to several years.<sup>2</sup> A wide spectrum of therapeutic interventions including surgical excision, cryotherapy, radiotherapy, lesional and systemic corticosteroids, thalidomide, methotrexate, and even chemotherapy<sup>10</sup> have also been reported to be successful for resistant and/or recurrent lesions.

In summary, we first present a case of CRDD with a peculiar eruption resembling molluscum contagiosum thus expanding the spectrum of the cutaneous clinical presentation of the disease and making CRDD another dermatologic masquerader. The nonspecific clinical presentation along with the not infrequently inconspicuous finding of Rosai-Dorfman cells in skin samples and furthermore the typical spontaneous resolution may represent clinico-pathologic characteristics that lead to the tangible possibility of CRDD being underreported.

## Conflicts of Interest

The authors declare that they have no conflicts of interest.

## References

1. Rosai J, Dorfman RF. Sinus histiocytosis with massive lymphadenopathy: A newly recognized benign clinicopathological entity. *Arch Pathol.* 1969;87:63-70.
2. Brenn T, Calonje E, Granter S, Leonard N, Grayson W, Fletcher CDM, McKee PH. Cutaneous Rosai-Dorfman disease is a distinct clinical entity. *Am J Dermatopathol.* 2002;24:385-91.
3. Lu CI, Kuo TT, Wong WR, Hong HS. Clinical and histopathologic spectrum of cutaneous Rosai-Dorfman disease in Taiwan. *J Am Acad Dermatol.* 2004;51:931-9.
4. Zhang X, Hyjek E, Vardiman J. A subset of Rosai-Dorfman disease exhibits features of IgG4-related disease. *Am J Clin Pathol.* 2013;139:622-32.
5. Morgan NV, Morris MR, Vangul H, Gleeson D, Straatman-Iwanowska A, Davies N, et al. Mutations in SLC29A3, encoding an equilibrative nucleoside transporter ENT3, cause a familial

- histiocytosis syndrome (Faisalaba histiocytosis) and familial Rosai-Dorfman disease. *PLoS Genet.* 2010;6:e1000833.
6. Liu P, Wang P, Du J, Zhang J. Successful treatment of refractory cutaneous Rosai-Dorfman disease with vincristine. *J Dermatol.* 2015;42:97–8.
  7. Kutlubay Z, Bairamov O, Sevim A, Demirkesen C, Mat MC. Rosai-Dorfman disease: A case report with nodal and cutaneous involvement and re-evaluated literature. *Am J Dermatopathol.* 2014;36:353–7.
  8. Colmenero I, Molho-Pessach V, Torrelo A, Ziotogorski A, Requena L. Emperipolesis: An additional common histopathologic finding in H syndrome and Rosai-Dorfman disease. *Am J Dermatopathol.* 2012;34:315–20.
  9. Molho-Pessach V, Lerer I, Abeliovich D, Agha Z, Libdeh AA, Brothilova V, et al. The H Syndrome Is Caused by Mutations in the Nucleoside Transporter hENT3. *Am J Hum Genet.* 2008;86:529–34.
  10. Wang KH, Chen WY, Liu HN, Huang CC, Lee WR, Hu CH. Cutaneous Rosai-Dorfman disease: Clinicopathological profiles,

spectrum and evolution of 21 lesions in six patients. *Br J Dermatol.* 2006;154:277–86.

J.M. Conde,<sup>a,\*</sup> A.Y. Kim,<sup>b</sup> R. de Miguel,<sup>c</sup> C.H. Nousari<sup>a</sup>

<sup>a</sup> *Dermatology, Broward Health Medical Center/Nova Southeastern University College of Osteopathic Medicine, Fort Lauderdale, FL, EE.UU.*

<sup>b</sup> *Nova Southeastern University College of Osteopathic Medicine, Fort Lauderdale, FL, EE.UU.*

<sup>c</sup> *Celimar Central Clinic, West Bay, Islas Caimán*

\* Corresponding author.

E-mail address: [docmoscoso@gmail.com](mailto:docmoscoso@gmail.com) (J.M. Conde). 1578-2190/

© 2017 Elsevier España, S.L.U. and AEDV. Published by Elsevier España, S.L.U. All rights reserved.

## Kikuchi-Fujimoto Disease with Scalp Involvement<sup>☆</sup>



### Enfermedad de Kikuchi-Fujimoto con compromiso de cuero cabelludo

Dear Editor,

We report the case of a 49-year-old Peruvian woman who presented with a 5-month history of cervical lymphadenopathy and neck pain. Social, family and medical past history were noncontributory. Physical examination revealed bilateral cervical lymphadenopathy, and a 3-cm-diameter erythematous plaque on her scalp (Figure 1a). Blood tests showed neutropenia ( $2.2 \times 10^9/L$ ) and positive serum antinuclear antibodies (titers 1:160). Computed tomographic scan (CTS) and 18-fluorodeoxyglucose positron emission tomography (PET) disclosed bilateral cervical lymphadenopathy with up to 2-cm enlarged lymph nodes.

Skin biopsy showed mild vacuolar change in epidermal basal cells as well as perifollicular lymphohistiocytic infiltration and karyorrhexis in the reticular dermis (Figure 1b, 1c). Immunohistochemical analysis revealed that the lymphoid infiltrate was predominantly CD3+, with CD8 positive cells predominating over CD4 (Figure 1d). By the other side CD68, CD163 and myeloperoxidase (MPO) immunostaining disclosed the presence of many histiocytes, and CD123 revealed that there were some plasmacytoid monocytes. Neutrophils and eosinophils were absent, and no granulomas were evidenced. Vasculitis was not a feature. Lymph node biopsy showed paracortical hyperplasia, patchy necrosis with abundant cellular debris

and profuse peripheral histiocytic cells. She was diagnosed with Kikuchi-Fujimoto disease (KFD) with cutaneous involvement.

KFD, also known as histiocytic necrotizing lymphadenitis, was first described by Kikuchi<sup>1</sup> and Fujimoto<sup>2</sup> in 1972. It is a benign and self-limiting disorder characterized by lymphadenopathy associated with low-grade fever and flu-like symptoms. Unilateral and posterior cervical nodes are the commonest to be involved although it can present as generalized lymphadenopathy.<sup>3</sup>

The female to male ratio is more than 4:1. The predominance of reports from Japan, and the fact that many of the patients reported in Europe and the USA have been of Asian descent, may point to a racial or genetic susceptibility.<sup>4</sup> Its etiology remains uncertain. A viral origin has long been suspected; however, the clinical course of the disease, the disappearance of lesions without any specific treatment, and some similarity with features of systemic lupus erythematosus (SLE) suggests the involvement of autoimmune mechanisms.<sup>3</sup>

The diagnosis is confirmed by lymph node biopsy.<sup>5</sup> Involved lymph nodes characteristically demonstrate architecture partially effaced by confluent paracortical necrotic foci with abundant karyorrhectic debris, surrounded by CD68+ and MPO+ histiocytes, immunoblasts, CD8+ T-cells and CD123+ plasmacytoid dendritic cells.<sup>6</sup> Neutrophils and eosinophils are absent. KFD has been classified into three histological subtypes, and is thought to progress from the proliferative type (expanded paracortex with an increase in histiocytes and plasmacytoid dendritic cells and karyorrhectic nuclear debris) to the necrotizing type (predominance of necrosis), and finally resolve into the xanthomatous type (predominance of foamy histiocytes).<sup>6</sup>

The skin is the most frequently affected extranodal organ, as cutaneous involvement has been reported in 16–40% of patients.<sup>7</sup> Although some cases of KFD cutaneous lesions mimicking urticarial, morbilliform, rubella-like or drug-eruption-like rashes have been described, cutaneous KFD usually presents as erythematous papules and plaques, predominantly on the face, arms and upper neck. The

<sup>☆</sup> Please cite this article as: Combalia A, Fustà-Novell X, García-Herrera A, Ferrando J. Enfermedad de Kikuchi-Fujimoto con compromiso de cuero cabelludo. *Actas Dermosifiliogr.* 2018;109:657–659.