



IMAGES IN DERMATOLOGY

Proliferating Pilomatricoma Mimicking a Malignant Tumor[☆]



Pilomatricoma proliferante simulando malignidad

P. García-Montero,^{*} J.B. Repiso-Jiménez, I. Fernández-Canedo

Departamento de Dermatología, Hospital Costa del Sol, Marbella, Málaga, Spain

A 76-year-old man with no relevant past history presented with a fast-growing lesion that had appeared 3 months earlier on the right temple. The lesion, with a diameter of 4 cm, presented as a hard subcutaneous tumor unattached to underlying tissues and covered by erythematous-violaceous skin. There was no noticeable fluid thrill and palpation elicited intense pain (Fig. 1A). The rest of the physical examination was unremarkable. Cutaneous ultrasound with an 18-MHz linear probe showed a well-defined heteroechoic nodular structure without hyperechoic dotted areas in the dermis and hypodermis; the structure was surrounded by a hypoechoic halo (Fig. 1B). Doppler ultrasound (18-MHz linear probe) showed intense intralesional vascularity (Fig. 1C). As the features suggested possible malignancy, the lesion was completely excised under local anesthesia and the defect repaired by direct closure. Histopathology findings were consistent with a pilomatricoma and showed high mitotic activity and a higher proportion of matrix than shadow cells. The diagnosis was proliferating pilomatricoma. The intense intralesional vascularity typically seen in malignant tumors is an uncommon finding in classic pilomatricoma, and we believe that it may be a feature of this fast-growing subtype.

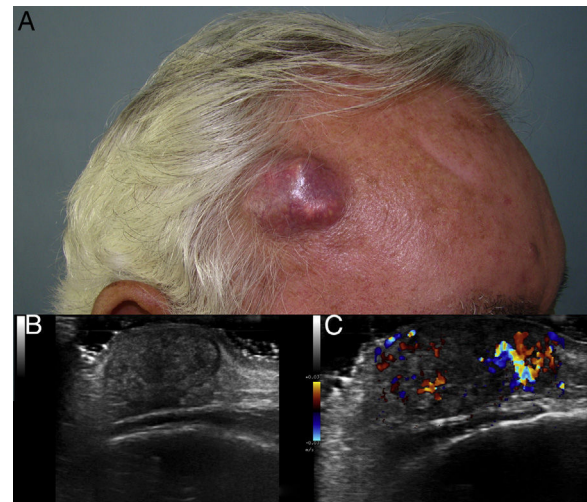


Figure 1

[☆] Please cite this article as: García-Montero P, Repiso-Jiménez JB, Fernández-Canedo I. Pilomatricoma proliferante simulando malignidad. Actas Dermosifiliogr. 2018;109:359.

^{*} Corresponding author.

E-mail address: garciamonteropablo@gmail.com
(P. García-Montero).