



IMAGES IN DERMATOLOGY

Angiolymphoid Hyperplasia With Eosinophilia[☆]



Hiperplasia angiolinfoide con eosinofilia

M.D. Nakandakari,^{a,b,*} D.N. de la Rosa,^{a,b} J. Arias^c

^a Sociedad Científica de Estudiantes de Medicina de la Universidad Privada San Juan Bautista (SOCIEM UPSJB), Lima, Perú

^b Escuela de Medicina Humana, Universidad Privada San Juan Bautista, Lima, Perú

^c Departamento de Dermatología, Hospital Nacional Hipólito Unanue, Lima, Perú

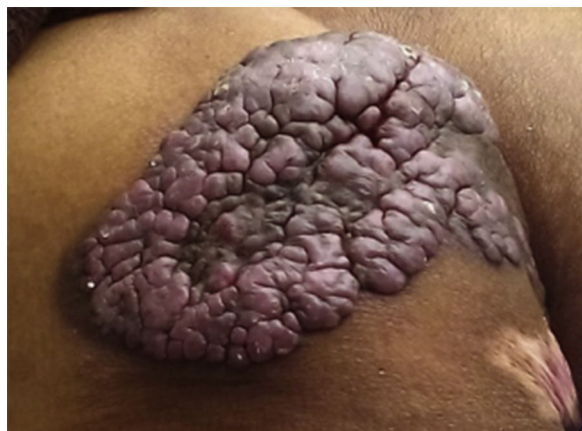

Figure 1

A 74-year-old man from Huanuco, Peru, was seen in the dermatology department of Hospital Nacional Hipólito Unanue for a solitary angiomasous mass that had arisen 20 years earlier in the left gluteal region. The tumor measured 21 × 13 × 1 cm and bled on contact (Fig. 1). It was not painful or pruritic. The differential diagnosis included Kimura disease, bacillary angiomatosis, angioma, epithelioid

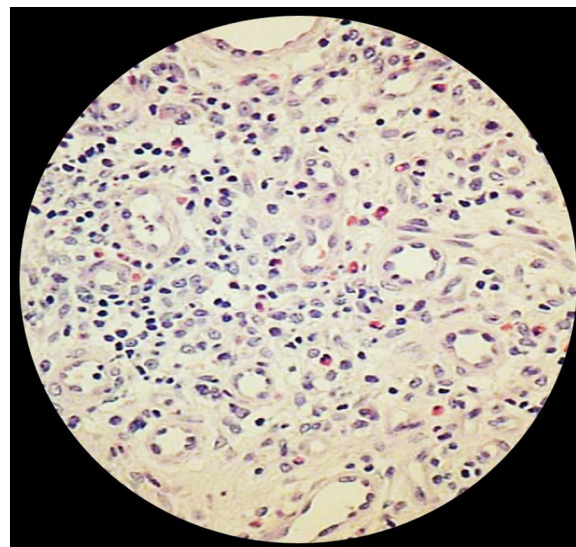


Figure 2

hemangioendothelioma, and Kaposi sarcoma. Histology of a biopsy of the tumor showed a lesion of benign characteristics, with intense vascular proliferation with prominent endothelial cells that projected into the lumina of the blood vessels. A chronic interstitial infiltrate with a predominance of lymphocytes and eosinophils was also observed (Fig. 2). Based on these findings we made a diagnosis of angiolymphoid hyperplasia with eosinophilia. As recurrence of this disease is typically around 30%, whatever the treatment, and as it is a benign disease, conservative treatment was recommended.

[☆] Please cite this article as: Nakandakari MD, de la Rosa DN, Arias J. Hiperplasia angiolinfoide con eosinofilia. Actas Dermosifiliogr. 2017;108:586.

* Corresponding author.

E-mail address: mdngmedicinaupsjb@hotmail.com
(M.D. Nakandakari).