

Azathioprine-Induced Hypersensitivity Reaction Presenting as Erythema Nodosum[☆]



Eritema nudoso como reacción de hipersensibilidad a la azatioprina

To the Editor:

Hypersensitivity reactions to drugs have a very varied clinical spectrum and can present different types of skin lesion, including erythema nodosum.

A 44-year-old woman with no known drug allergies, diagnosed with Crohn disease 2 years earlier, had started treatment with azathioprine (AZT) 3 weeks prior to consultation because of laboratory and radiological signs of progression of her Crohn disease. She came to the emergency department with a 7-day history of painful erythematous lesions on both lower limbs, associated with general malaise, loss of appetite, and knee and ankle pain. She did not report fever.

Examination revealed multiple disperse, occasionally tender, erythematous subcutaneous nodules measuring between 10 and 20 mm on both lower limbs. There were also a number of violaceous macules of residual appearance measuring 15 to 20 mm in diameter (Fig. 1).

Histopathology of a lesion showed thickening and fibrosis of septa in the subcutaneous cellular tissue, with a chronic inflammatory infiltrate formed of histiocytes and lymphocytes, and granulomas with multinucleated giant cells were also present (Fig. 2, A and B). No microorganisms were observed on staining with periodic acid-Schiff, Gram, and Ziehl-Neelsen stains. Laboratory findings were as follows: hemoglobin, 10.4 g/dL; mean corpuscular volume, 78.4 fL; mean corpuscular hemoglobin, 25.3 pg; elevation of the transaminases (alanine aminotransferase, 82 U/L); γ -glutamyl transferase, 126 U/L; C-reactive protein, 12.59 mg/dL (normal range, 0.1-0.5 mg/dL); and no abnormalities in the autoimmunity study. There was no induration on the tuberculin skin test and chest x-ray showed no changes (Table 1).

Given the possibility that the lesions could have been due to the AZT, it was decided to interrupt the treatment. This led to the resolution of systemic symptoms within 24 h and of the skin lesions within 3 days, with no other treatment. Based on these findings, we made a diagnosis of hypersensitivity reaction to AZT with cutaneous manifestations in the form of erythema nodosum.

AZT is a precursor of 6-mercaptopurine and is used as an immunosuppressant drug for the treatment of chronic inflammatory diseases such as inflammatory bowel disease (IBD).

Adverse effects associated with this drug are subdivided into early and late reactions.

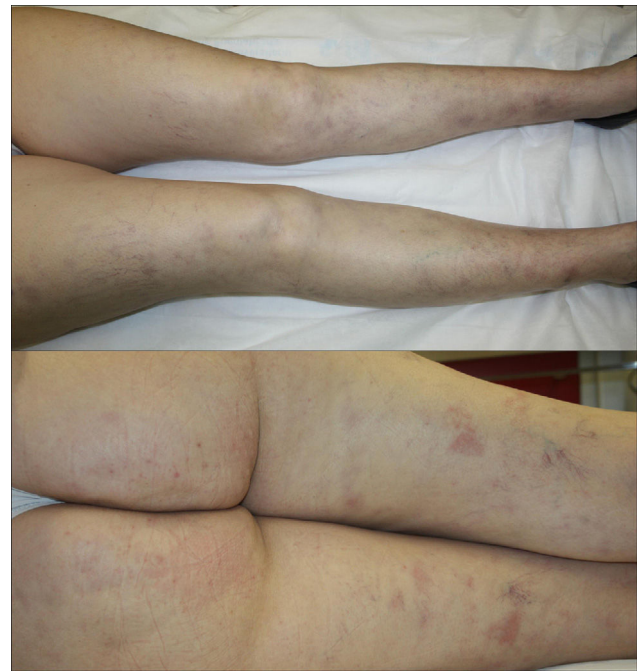


Figure 1 Subcutaneous nodules with superficial erythema and erythematous-violaceous macules of residual appearance on the anterior and posterior aspects of both lower limbs.

Early reactions, including hypersensitivity reactions, are common.¹ These are idiosyncratic reactions that occur in approximately 2% of patients in the first 4 weeks of treatment, though they are probably underdiagnosed.^{1,2} Clinically they can present with fever, hypotension, general malaise, joint pain, gastrointestinal symptoms, hepatitis, pancreatitis, nephritis, pneumonia, pericarditis, and skin lesions.^{1,3} After the interruption of treatment, the lesions resolve rapidly, within 2 to 3 days.² Many cases are initially diagnosed as infectious diseases or exacerbations of the underlying disease, and the hypersensitivity reaction may not be detected until re-exposure to the drug.^{2,3} Symptom recurrence after rechallenge to the drug will confirm the cause-effect relationship, but as the reaction is more intense and develops more rapidly, occasionally within a few hours,³ rechallenge is contraindicated.² Patients with IBD have been considered to be at greater risk of hypersensitivity reactions to AZT; this may be due to a polymorphism in the gene that codes for inosine triphosphate pyrophosphatase.⁴

In 2011, Bidinger et al.² reviewed all published cases of hypersensitivity to AZT, finding that approximately 50% presented cutaneous manifestations. The most common cutaneous presentation was Sweet syndrome, followed in order of frequency by nonspecific maculopapular, vesicular, pustular, or urticarial rashes, small-vessel vasculitis, erythema nodosum,^{1,5} and acute generalized exanthematous pustulosis. A dozen more cases with skin involvement have been published since that time, the majority presenting as Sweet syndrome, though also including 2 cases of neutrophilic eccrine hidradenitis,^{6,7} an association not previously described. The most common histopathology finding is a neutrophilic dermatosis.²

[☆] Please cite this article as: González-Olivares M. Eritema nudoso como reacción de hipersensibilidad a la azatioprina. *Actas Dermosifiliogr.* 2017;108:591-593.

Table 1 Review of Published Cases of Erythema Nodosum as a Hypersensitivity Reaction to Azathioprine.

	Age, y, and Sex	Underlying Disease	Latency Period	Time to Resolution, d	Recurrence After Rechallenge
de Fonclare et al. ¹	17, F	IBD	14 d	16 d	12 h
	49, F	IBD	8 d	12 d	4 h
	75, M	IBD	14 d	14 d	Not performed
Vargas-Hitos et al. ⁵	65, F	Bullous pemphigoid	7 d	14 d	Not performed

Abbreviations: F, female; IBD, inflammatory bowel disease; M, male.

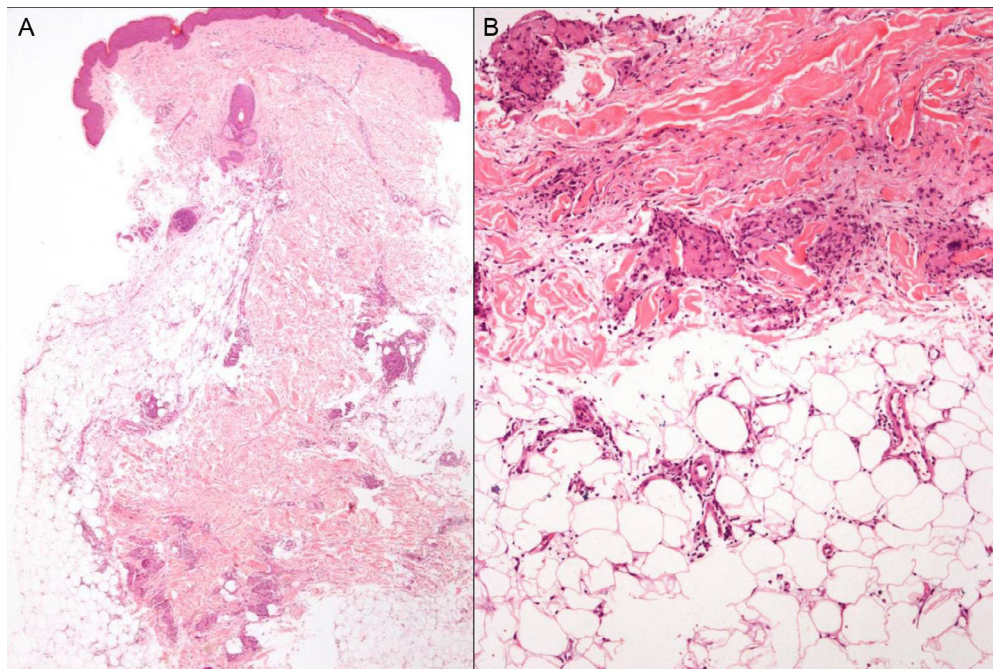


Figure 2 Histopathology. A, Septal thickening with fibrosis. Hematoxylin and eosin, original magnification $\times 4$. B, Lymphohistiocytic infiltrate with granulomas in the septa. Hematoxylin and eosin, original magnification $\times 40$.

Erythema nodosum associated with IBD is observed in up to 10% of patients with ulcerative colitis and 15% of those with Crohn disease. The course of the skin lesions usually parallels activity of the bowel disease and resolve with appropriate treatment of that disease.⁸

Late reactions, such as myelosuppression, are dose dependent and can be avoided to a great extent by measuring activity of the enzyme thiopurine methyltransferase.¹

In our patient, the lesions resolved within 3 days without treatment. After resolution of the alterations, treatment was started with infliximab, which had to be interrupted due to an infusion reaction and possible drug-induced dermatitis. A year after consultation, the patient has presented occasional outbreaks of her bowel disease, presenting as episodes of subacute intestinal occlusion, but no further episodes of erythema nodosum.

The presence of erythema nodosum lesions in patients on treatment with AZT who do not present signs of an exacerbation of IBD or intercurrent infection must alert us to a possible hypersensitivity reaction to the drug.

Conflicts of Interest

The authors declare that they have no conflicts of interest.

References

- de Fonclare AL, Khosrotehrani K, Aractingi S, Duriez P, Cosnes J, Beaugerie L. Erythema nodosum-like eruption as a manifestation of azathioprine hypersensitivity in patients with inflammatory bowel disease. *Arch Dermatol*. 2007;143:744–8.
- Bidinger JJ, Sky K, Battafarano DF, Henning JS. The cutaneous and systemic manifestations of azathioprine hypersensitivity syndrome. *J Am Acad Dermatol*. 2011;65:184–91.
- Sofat N, Houghton J, McHale J, Higgins CS. Azathioprine hypersensitivity. *Ann Rheum Dis*. 2001;60:719–20.
- Marinaki AM, Ansari A, Duley JA, Arenas M, Sumi S, Lewis CM, et al. Adverse drug reactions to azathioprine therapy are associated with polymorphism in the gene encoding inosine triphosphate pyrophosphatase (ITPase). *Pharmacogenetics*. 2004;14:181–7.

5. Vargas-Hitos JA, Sabio JM, Tercedor J, Navarrete-Navarrete N, Jiménez-Alonso J. Erythema nodosum as azathioprine hypersensitivity reaction in a patient with bullous pemphigoid. *Indian J Dermatol.* 2013;58:406.
6. Schmutz JL. Neutrophilic eccrine hidradenitis and azathioprine hypersensitivity syndrome. *Ann Dermatol Venereol.* 2014;141:738–9.
7. García-Martín P, Sánchez-Pérez J, Fraga J, García-Díez A. Neutrophilic eccrine hidradenitis in a patient with Crohn's disease and azathioprine hypersensitivity syndrome. *J Eur Acad Dermatol Venereol.* 2014;28:1830–2.
8. Vavricka SR, Schoepfer A, Scharl M, Lakatos PL, Navarini A, Rogler G. Extraintestinal manifestations of inflammatory bowel disease. *Inflamm Bowel Dis.* 2015;21:1982–92.

M. González-Olivares,* R. Khedaoui, C. Martínez-Morán, J. Borbujo

Servicio de Dermatología y Anatomía Patológica, Hospital Universitario de Fuenlabrada, Fuenlabrada, Madrid, Spain

*Corresponding author.

E-mail address: mgonzalezo@salud.madrid.org

(M. González-Olivares).

1578-2190/

© 2017 Elsevier España, S.L.U. and AEDV. All rights reserved.

Refractory solar urticaria successfully treated with omalizumab with normalization of phototest



Urticaria solar refractaria tratada satisfactoriamente con omalizumab y normalización del fototest

Dear Editor,

Solar urticaria (SU) is a rare photodermatosis characterized by sudden onset of urticarial skin lesions, intense itching or burning on photo-exposed areas, occurring a few minutes after sun exposure with great impact on patients' quality of life. It is considered a type I hypersensitivity reaction, and therefore, it is an immunoglobulin E (IgE)-mediated condition that may be accompanied by other systemic symptoms and signs, such as dizziness, headache and angioedema. The action of spectrum for SU includes ultraviolet A (UVA), ultraviolet B (UVB), visible light (VL) and some patients may be sensitive to multiple action spectra. Although the diagnosis is made by the characteristic clinical presentation, it can be confirmed by phototesting.¹

The treatment of choice consists in broad-spectrum sunscreens and high-dose H1-antihistamines; however, SU is often unresponsive to them. Other treatment options are leukotriene receptor antagonists, UV-hardening, cyclosporine A, antimalarial drugs, plasmapheresis and intravenous immunoglobulin (IVIg). Efficacy of these treatments is usually partial or transient and may induce several unwanted effects, i.e. anaphylaxis, immunosuppression and malignancy.

Omalizumab is a humanized monoclonal IgG1-kappa antibody against IgE recently approved by the US Food and Drug Administration and the European Medicines Agency for antihistamine refractory patients with chronic spontaneous urticaria (CSU) who are at least 12 years of age.² Omalizumab binds to free IgE with a greater affinity than IgE itself binds to the high-affinity FcεRI receptors present on basophils. Thus, it reduces the availability of free IgE for binding and promotes down-regulation of FcεRI on the

surface of mast cells and basophils preventing IgE-mediated histamine release.³

We report a case of a previously healthy 21 year-old Caucasian female with a 4-year history of erythema, intense itch, swelling and hives after minimal sun exposure even through window glass. No history of asthma or food allergy was reported. Phototest performed on the patient's back (Waldman® UV 181 UVA and Waldman® UV 800 broad band UVB) was positive for UVA, minimal urticarial dose 7 J/cm², and showed no reaction to UVB (Fig. 1). Visible light was not tested. IgE serum levels were elevated (294 kU/L) and other blood test determinations fell within normal limits; cell count, porphyrins, antinuclear antibodies, liver and renal function panel, and serum triptase. She was diagnosed with Solar Urticaria (SU) induced by UVA, and partially

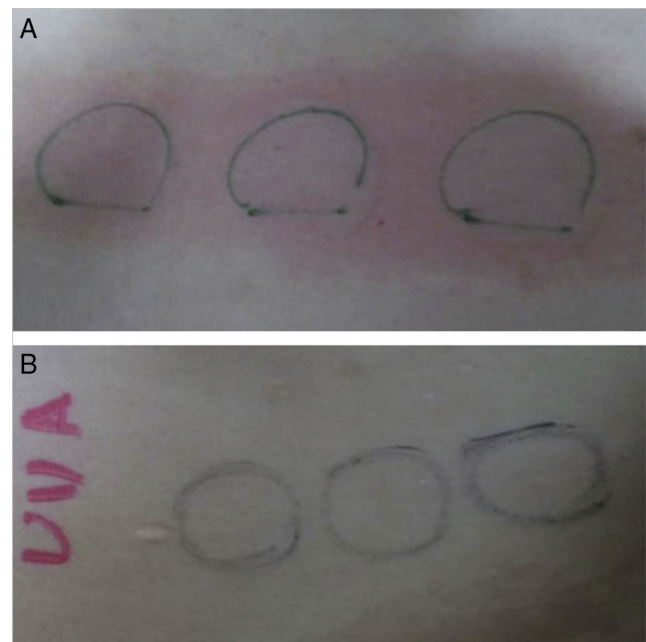


Figure 1 (A) Phototest before omalizumab (Waldman® UV 181 UVA) was positive for UVA, minimal urticarial dose 7 J/cm². (B) Phototest after omalizumab (Waldman® UV 181 UVA): no reaction occurred to UVA after 6 months of treatment.