

M. Álvarez-Salafranca,<sup>a,\*</sup> S. Hernández-Ostiz,<sup>a</sup>  
S. Salvo Gonzalo,<sup>b</sup> M. Ara Martín<sup>a</sup>

<sup>a</sup> Servicio de Dermatología, Hospital Clínico Universitario Lozano Blesa, Zaragoza, Spain

<sup>b</sup> Servicio de Microbiología, Hospital Clínico Universitario Lozano Blesa, Zaragoza, Spain

\* Corresponding author.

E-mail address: [marcialaspn@gmail.com](mailto:marcialaspn@gmail.com)

(M. Álvarez-Salafranca).

1578-2190/

© 2016 Elsevier España, S.L.U. and AEDV. All rights reserved.

## Late Xanthomatous Pseudotumor Following Treatment for Breast Cancer<sup>☆</sup>



### Seudotumor xantomatoso diferido tras tratamiento de cáncer de mama

To the Editor:

Radiation therapy is well known to cause both acute and chronic changes in irradiated skin. Isolated cases of immediate xanthomatous changes following radiotherapy or chemotherapy have been described in association with certain tumors and with inflammatory disorders such as herpes zoster infection and mosquito bites.

We present the case of an 83-year-old woman with a history of diabetes mellitus, dyslipidemia, chronic kidney failure, Parkinson disease, and left breast cancer treated with breast-conserving surgery with axillary lymph node dissection, radiotherapy, and chemotherapy in 2008. The patient was referred to our department for assessment of an asymptomatic yellowish plaque of 6 months' duration on the left breast. The physical examination showed a large yellow-brown plaque that was slightly hard to the touch and had a verrucous, papilliform surface surrounded by an erythematous halo. The plaque had well-delimited borders and a peculiar geometric shape. There was no evidence of inflammation or local infection (Fig. 1). No other relevant findings were observed in the examination.

A skin biopsy was performed to investigate the suspected diagnoses of tumor recurrence, xanthogranulomatous mastitis, and radiation-induced xanthomatous changes. The histopathologic findings showed a thinned epidermis with flattened rete ridges, an infiltrate consisting of numerous clusters of foamy histiocytes interspersed with inflammatory cells in the superficial dermis, and discrete inflammatory interstitial infiltrates in the deep dermis (Fig. 2). There were no signs suggestive of malignancy. The xanthoma-like cells were positive for CD68 and negative for cytokeratins in the immunohistochemical study. Results of a complete blood count, chest radiograph, and abdominal ultrasound were unremarkable.

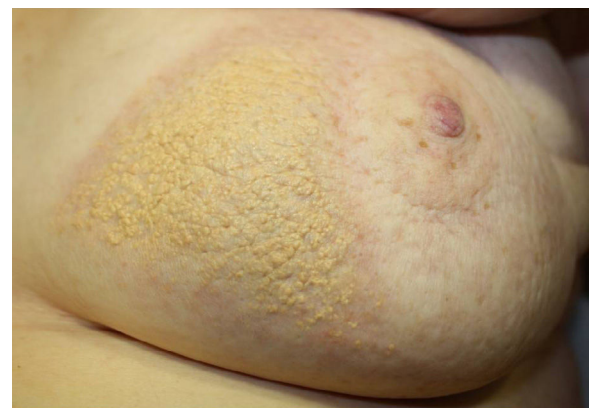A diagnosis of delayed xanthomatous pseudotumor secondary to chemotherapy and radiotherapy was established.

The general criteria for diagnosing radiation-induced tumors include histologic confirmation of a tumor in the irradiated area, a period of latency between exposure to radiation and development of the tumor, and exclusion of a tumor before radiotherapy.<sup>1</sup>

Few cases of xanthomatous transformation have been reported in patients with tumors treated by radiotherapy and/or chemotherapy, and most have involved B-cell lymphomas (Table 1).<sup>1-9</sup>

These inflammatory pseudotumors are an enigmatic entity and appear to be due to a localized inflammatory process mediated by inadequate production of cytokines. Several terms have been proposed to describe formations of xanthomatous cells that appear after radiotherapy and/or chemotherapy, including *postchemotherapy histiocyte-rich pseudotumor*, *xanthomatous pseudotumor*, and *benign histiocytic proliferation with xanthomatous changes*.<sup>2,5,7,9,10</sup>

Despite the few cases published, it has been hypothesized that these xanthomatous cells may be histiocytes that survived the chemotherapy or radiotherapy or histiocytes from peripheral blood that engulf necrotic fat debris released by destroyed tumor cells and become xanthomatous cells.<sup>1,3-5,7,9</sup> It is plausible that chemotactic substances released in response to the tumor necrosis trigger the recruitment of monocytes, which then differentiate into histiocytes. These, in turn, would be activated, increase in size, and trigger the release of more chemokines, leading to the recruitment of additional monocytes and a considerable accumulation of histiocytes in response to the tumor necrosis.<sup>7</sup> This process does not appear to be

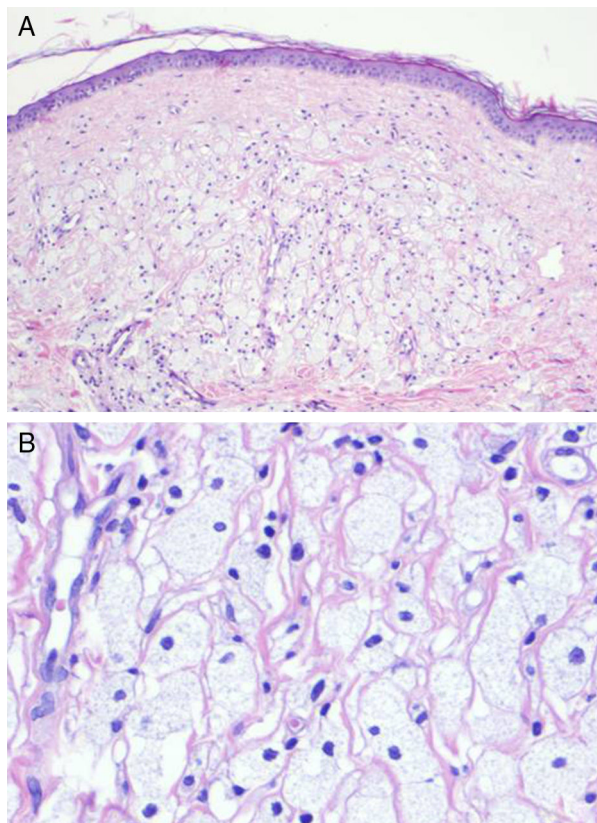


**Figure 1** Yellowish plaque with a verrucous, papilliform surface surrounded by an erythematous halo on the left breast.

<sup>☆</sup> Please cite this article as: González-Sabín M, Mallo-García S, Rodríguez-Díaz E, Gonzalvo-Rodríguez P. Seudotumor xantomatoso diferido tras tratamiento de cáncer de mama. *Actas Dermosifiliogr*. 2017;108:484-486.

**Table 1** Summary of Cases of Xanthomatous Transformation of a Tumor Following Radiotherapy and/or Chemotherapy.

|   | Type of Tumor  | Treatment                       | Latency Period                                   |
|---|--|---------------------------------|--|
| Sasaki et al. (1983) <sup>2</sup>         | Malignant pleomorphic fibrous histiocytoma                           | Radiotherapy                    | 3 wk   |
| Ashfaq et al. (1992) <sup>3</sup>         | Abdominal Burkitt lymphoma   | Polychemotherapy                | 4 mo   |
| Ijiri et al. (2000) <sup>1</sup>          | Ependymoma   | Radiotherapy + chemotherapy     | 8 y  |
| Chung et al. (2003) <sup>4</sup>          | Primary cutaneous CD30 <sup>+</sup> large T-cell lymphoma            | Radiotherapy                    | 5 wk   |
| Tan et al. (2003) <sup>5</sup>            | High-grade invasive ductal carcinoma                                 | Chemotherapy                    | Immediate, on completion of chemotherapy         |
| Chumsri et al. (2007) <sup>6</sup>        | Hodgkin lymphoma   | Radiotherapy + polychemotherapy | Immediate, on completion of treatment            |
| Chandra et al. (2009) <sup>7</sup>        | Two cases of diffuse large B-cell lymphoma                           | Polychemotherapy                | 1 and 3 mo                                       |
| Otto et al. (2012) <sup>8</sup>           | Diffuse large B-cell lymphoma  | Polychemotherapy                | 3 mo   |
| Turrión-Merino et al. (2016) <sup>9</sup> | Primary cutaneous CD30 <sup>+</sup> anaplastic large T-cell lymphoma | Radiotherapy + methotrexate     | Immediate, on completion of methotrexate therapy |



**Figure 2** A, Infiltration of the superficial dermis by numerous clusters of foamy histiocytes interspersed with isolated inflammatory cells (hematoxylin-eosin, original magnification  $\times 25$ ). B, Detail of foamy histiocytes (hematoxylin-eosin, original magnification  $\times 100$ ).

related to high cholesterol or triglyceride levels. Rather, it seems to be an unpredictable treatment sequela related to phagocytosis of necrotic cell debris.<sup>3</sup>

These collections of xanthomatous cells can form large pseudotumors and polypoid lesions that can mimic neoplastic disease, and their recognition is essential from the perspective of patient management.<sup>3</sup> The transformation generally occurs within the first few weeks or months of treatment. In our case, the xanthomatous pseudotumor appeared 7 years after the patient was treated with radiotherapy and chemotherapy. There is just 1 other report in the literature of a similarly long latency period: that of a xanthomatous meningioma that developed 8 years after radiotherapy.<sup>1</sup>

In our patient, the site of the lesion (clearly located in the irradiation field) and its characteristics (clearly demarcated borders) suggest that radiotherapy may have been the main factor responsible for the xanthomatous transformation.

We have reported the first case of a xanthomatous pseudotumor following the treatment of breast cancer with radiotherapy and chemotherapy. The long latency period between the treatment and the appearance of the changes is particularly noteworthy.

### Conflicts of Interest

The authors declare that they have no conflicts of interest.

### References

- Ijiri R, Tanaka Y, Hara M, Sekido K. Radiation-associated xanthomatous meningioma in a child. *Childs Nerv Syst.* 2000;16:304–8.
- Sasaki R, Sakai S, Itoh M, Murata M, Honda M, Aozasa K. Malignant fibrous histiocytoma in the maxillary sinus.

- Xanthoma-like change of the tumor after radiotherapy. *Laryngoscope*. 1983;93:202–4.
3. Ashfaq R, Timmons CF. Xanthomatous pseudotumor of the small intestine following treatment for Burkitt's lymphoma. *Arch Pathol Lab Med*. 1992;116:299–301.
  4. Chung HG, Chung YL, Kang JM, Yang WI, Suh CO, Hahn JS, et al. CD30 (Ki-1)-positive large-cell cutaneous T-cell lymphoma with secondary xanthomatous changes after radiation therapy. *J Am Acad Dermatol*. 2003;48 Suppl 2:S28–30.
  5. Tan KB, Thamboo TP, Raju GC. Xanthomatous pseudotumor. An unusual postchemotherapy phenomenon in breast cancer. *Arch Pathol Lab Med*. 2003;127:739–41.
  6. Chumsri S, Tummala MK, Khna AM, Zhao XF, Rapoport AP. Persistent positron emission tomography positivity secondary to benign histiocytic proliferation after treatment of Hodgkin lymphoma. *Leuk Lymphoma*. 2007;48:616–8.
  7. Chandra P, Wen YH, Tuli S, Raphael BG, Amorosi EL, Medeiros LJ, et al. Postchemotherapy histiocyte-rich pseudotumor involving the spleen. *Am J Clin Pathol*. 2009;132:342–8.
  8. Otto M, Shulkin BL, Kundu M, Sandlund JT, Snyder SE, Metzger ML. Histiocyte-rich xanthomatous pseudotumor mimicking relapse on positron emission tomography imaging in an adolescent with primary mediastinal diffuse large B-cell lymphoma. *J Pediatr Hematol Oncol*. 2012;34:232–5.
  9. Turrión-Merino L, Perez-Gala S, Hermosa-Zarza E, Urech-García-de-la-Vega M, Carrillo-Guijón R, Jaén-Olasolo P. Primary cutaneous CD30<sup>+</sup> anaplastic large cell lymphoma treated with radiotherapy and methotrexate with development of xanthomas at the sites of prior disease. *J Cutan Pathol*. 2016;43:400–5.
  10. Bisceglia M, Fusilli S, Zaffarano L, Fiorentino F, Tardio B. Inflammatory pseudotumor of the breast. Report of a case and review of the literature. *Pathologica*. 1995;87:59–64.
- M. González-Sabín,<sup>a,\*</sup> S. Mallo-García,<sup>a</sup> E. Rodríguez-Díaz,<sup>a</sup> P. Gonzalvo-Rodríguez<sup>b</sup>
- <sup>a</sup> *Servicio de Dermatología, Hospital de Cabueñes, Gijón, Asturias, Spain*  
<sup>b</sup> *Servicio de Anatomía Patológica, Hospital de Cabueñes, Gijón, Asturias, Spain*
- \* Corresponding author.  
 E-mail address: [martagonzalezsabin@gmail.com](mailto:martagonzalezsabin@gmail.com)  
 (M. González-Sabín).  
 1578-2190/  
 © 2016 Elsevier España, S.L.U. and AEDV. All rights reserved.

## Morphea in a Patient With Psoriasis on Treatment With Ustekinumab: Comorbidity or Adverse Effect?<sup>☆</sup>



## Morfea en una paciente con psoriasis en tratamiento con ustekinumab: ¿coexistencia o efecto adverso?

To the Editor:

We report the case of a 63-year-old woman with a history of pustular and plaque psoriasis that had first appeared 4 years earlier. The patient had previously received treatment with topical clobetasol, calcipotriene-betamethasone, and oral acitretin at a dose of 25 mg/d, as well as narrowband UV-B phototherapy. Because of the persistence of the lesions, we decided to initiate systemic therapy with ustekinumab. At a follow-up appointment 6 months after the start of biologic therapy, the psoriasis had improved. However, on the back of both legs, several hard, pearly plaques with violaceous edges had appeared in lightened areas of older psoriasis plaques (Figures 1A and 1B). Localized morphea was clinically suspected. A biopsy specimen was taken from one of the lesions and histologic examination resulted in a diagnosis of morphea (Figure 1C).

The coexistence of morphea and psoriasis is a rare finding in routine clinical practice. To date, 19 cases have been described in the literature (Table 1).<sup>1–8</sup> Nevertheless, psoriasis is the autoimmune disease most frequently associated with morphea, accounting for 11.6% of cases in which an immune-mediated disease occurs in conjunction with morphea.<sup>1</sup> The small number of case reports and the lack of knowledge about the pathophysiologic mechanisms of both entities make it difficult to understand this phenomenon. Nevertheless, we have developed several hypotheses.

First, our patient could have developed morphea concomitantly with psoriasis due to a common immunologic basis of the 2 entities. Multiple helper T (T<sub>H</sub>) cell differentiation pathways besides those mentioned in this article have been described; 3 such pathways are of special interest in our case.<sup>9,10</sup> The T<sub>H</sub>1 pathway and its associated interleukins (IL)—IL-2, IL-12, and interferon (IFN)  $\gamma$ —regulate cellular immunity and are associated with conditions such as psoriasis, inflammatory bowel disease, and graft-versus-host disease. The T<sub>H</sub>2 pathway—which is associated with IL-4, IL-5, and IL-13—is involved in humoral immunity and is, to date, the main pathway known to be involved in morphea. A third, recently described pathway—T<sub>H</sub>17, associated with IL-17, IL-22, and IL-23—is believed to play a more important role in immune-mediated diseases. This pathway appears to interact with the 2 pathways mentioned above. Several authors have argued that dysregulation of these pathways could be responsible for the coexistence of morphea and psoriasis in the same patient.<sup>3,4,11</sup> The immunologic environment of psoriasis, dominated by the T<sub>H</sub>1 pathway, could mask manifestations of sclerosing diseases such as morphea, which are dominated by T<sub>H</sub>2. Along these lines, Bezalel et al.<sup>11</sup> reported the case of a patient who developed plaques of morphea while receiving IFN treatment for multiple sclerosis. The authors concluded that IFN-induced activation of

<sup>☆</sup> Please cite this article as: Corral Magaña O. Morfea en una paciente con psoriasis en tratamiento con ustekinumab: ¿coexistencia o efecto adverso?. *Actas Dermosifiliogr*. 2017;108:486–488.