




ACTAS Derma-Sifiliográficas

Full English text available at
www.actasdermo.org



IMAGES IN DERMATOLOGY

Lip Swelling in an Immunocompetent Man[☆]



Tumefacción labial en varón inmunocompetente

N. Valdeolivas-Casillas,^{*} A.B. Piteiro-Bermejo, L. Trasobares-Marugán

Servicio de Dermatología, Hospital Universitario Príncipe de Asturias, Alcalá de Henares, Madrid, Spain

Received 6 November 2014; accepted 4 February 2015

The patient was a 27-year-old man with no personal history of interest who consulted for lesions on the lower lip that had appeared 2 days earlier. Examination revealed vesicles containing a clear fluid and erosions. The patient was therefore diagnosed with herpes simplex and treated with oral valacyclovir. His condition worsened during the following days, and he complained of intense pain and swelling of the lower lip, which was the site of

several pustules draining through multiple sinuses (Figure 1). The purulent liquid was cultured for fungi, bacteria, and mycobacteria. *Staphylococcus aureus* was isolated, and the patient was diagnosed with lip abscess. Treatment with intravenous amoxicillin clavulanic acid and manual drainage led to an excellent clinical response. Figure 1B shows the appearance of the lip 1 month after completion of treatment.

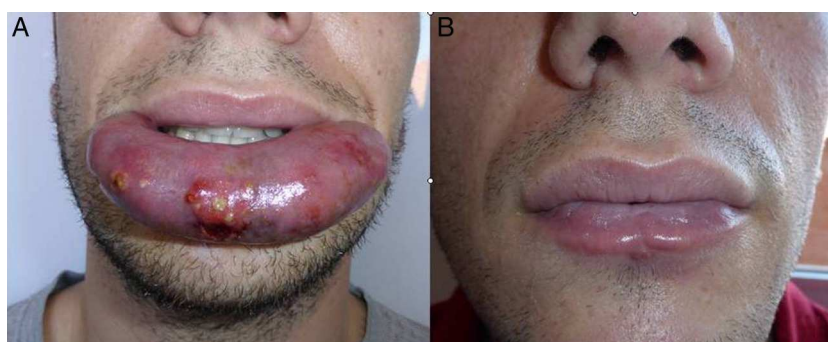

Figure 1

[☆] Please cite this article as: Valdeolivas-Casillas N, Piteiro-Bermejo A, Trasobares-Marugán L. Tumefacción labial en varón inmunocompetente. Actas Dermosifiliogr. 2015;106:430.

^{*} Corresponding author.

E-mail address: n.valdeolivas@gmail.com (N. Valdeolivas-Casillas).