



IMÁGENES EN DERMATOLOGÍA

[Translated article] Nodules in a Young Traveler: Utility of Dermoscopy in Cutaneous Myiasis

Nódulos en una joven viajera: utilidad de la dermatoscopia en las miasis cutáneas

J. Gil-Lianes^{a,b}, M. Ivars^{b,*}

^a Departamento de Dermatología, Hospital Clínic, Universidad de Barcelona, Barcelona, España

^b Departamento de Dermatología, Hospital Sant Joan de Déu, Esplugues de Llobregat, Barcelona, España

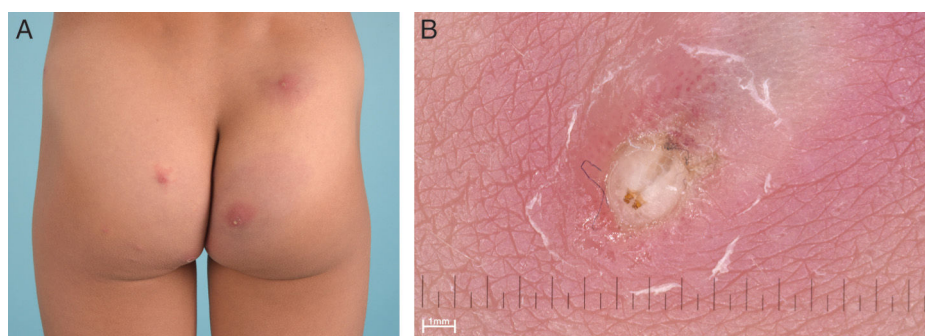


Figure 1

A healthy 7-year-old patient consulted due to a 2-week history of multiple painful nodules after a trip to Senegal. Some family members exhibited similar lesions. On physical examination, erythematous, indurated nodules with an asymmetrical distribution were observed on the thighs, chest, buttocks, and feet (fig. 1A). Dermoscopy revealed the presence of an ellipsoid, bilobed white structure at the center of the nodules with 2 brown linear structures (fig. 1B). A diagnosis of furuncular cutaneous myiasis caused by the species *Cordylobia anthropophaga* was suspected.

Cutaneous myiasis is a skin infestation caused by fly larvae of the order *Diptera*. It can be primary (furuncular or migratory type) or secondary (in wounds). Epidemiological factors, the type of lesion, and larval morphology will guide the diagnosis. Furuncular myiasis is endemic in West Africa, with *C. anthropophaga* being the most common causative species. Female flies lay their eggs on dry soil or soil contaminated with feces. Once they hatch, in the context of prolonged contact, the larvae can penetrate the host's skin forming furuncular cysts. Dermoscopy can be a useful diagnostic tool in cutaneous parasitic infections, especially in resource-limited areas. Furuncular myiasis shows as a cream-white area with central brownish structures resembling 2 legs or hooks, corresponding to the posterior segment of the larvae. Additionally, black dots, larval movement, bubbles under occlusion, or increased peripheral vascularization can be observed.

DOI of original article:

<https://doi.org/10.1016/j.ad.2023.05.043>

* Corresponding author.

E-mail address: marta.ivars@sjd.es (M. Ivars).

<https://doi.org/10.1016/j.ad.2024.10.012>

0001-7310/© 2024 AEDV. Published by Elsevier España, S.L.U. This is an open access article under the CC BY-NC-ND license (<http://creativecommons.org/licenses/by-nc-nd/4.0/>).

Please cite this article as: J. Gil-Lianes and M. Ivars, [Translated article] Nodules in a Young Traveler: Utility of Dermoscopy in Cutaneous Myiasis, ACTAS Dermo-Sifiliográficas, <https://doi.org/10.1016/j.ad.2024.10.012>