

IMAGES IN DERMATOLOGY

[Translated article] Myeloid Sarcoma After «Complete» Remission of Acute Myeloid Leukemia



Sarcoma mieloide tras remisión «completa» de leucemia mieloide aguda

F.J. Rodríguez-Cuadrado^{a,*}, G. Silvestre-Egea^b, I. Salguero-Fernández^a

^a Servicio de Dermatología, Hospital Universitario Puerta de Hierro-Majadahonda, Majadahonda, Madrid, Spain

^b Servicio de Anatomía Patológica, Hospital Universitario Puerta de Hierro-Majadahonda, Majadahonda, Madrid, Spain

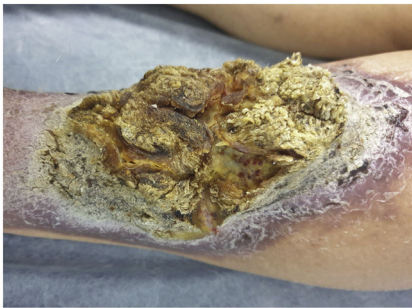


Figure 1

An 87-year-old woman presented with a 1-year old lesion on her left leg. The patient had a history of acute myeloid leukemia with trilineage dysplasia and BCR-ABL p1.90 mutation, for which she received chemotherapy until complete remission 18 years earlier. Physical examination revealed the presence of a 17 cm × 13 cm hyperkeratotic plaque of a yellowish-brown color with papillomatous projections of a villous appearance, on a highly infiltrated 21 cm × 16.5 cm erythematous-squamous base (Fig. 1).

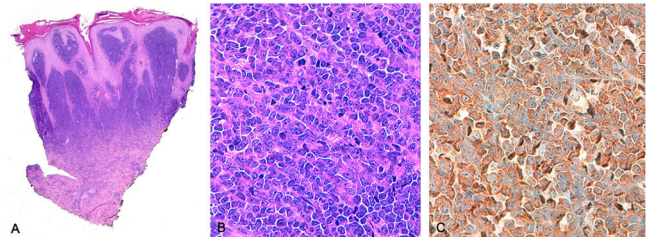


Figure 2

Biopsy of the lesion confirmed the dermal infiltration of polygonal eosinophilic cells with an elevated number of mitoses, pleomorphic nuclei, and karyorrhexis (Fig. 2A and 2B). Immunohistochemistry tested positive for CD123 (a marker for malignant hematologic neoplasms, including plasmacytoid dendritic cell neoplasm or acute myeloid leukemia) (Fig. 2C), and for CD43, CD45, CD99, CD117, and Bcl-2. Molecular study showed a mutated/non-mutated FLT3 ratio of 0.78; a pathogenic mutation in exon 12 of NPM1; and expression of the WT1 gene, without identification of the BCR-ABL mutation. These findings led to a diagnosis of myeloid sarcoma associated with the previous myeloproliferative process.

The patient was treated with radiotherapy (1st cycle of 4Gy fractionated in 2 sessions and 2nd cycle of 20Gy fractionated in 10 sessions) and chemotherapy (8 cycles of azacitidine 100mg every 24h for 7 days per cycle and midostaurin 50mg every 12h). Two years after diagnosis, the patient was still very responsive to therapy.

DOI of original article:

<https://doi.org/10.1016/j.ad.2023.05.037>

* Corresponding author.

E-mail address: franciscojose.rodriguezcuadrado@gmail.com (F.J. Rodríguez-Cuadrado).

<https://doi.org/10.1016/j.ad.2024.08.003>

0001-7310/© 2023 AEDV. Published by Elsevier España, S.L.U. This is an open access article under the CC BY-NC-ND license (<http://creativecommons.org/licenses/by-nc-nd/4.0/>).