




ACADEMIA ESPAÑOLA
DE DERMATOLOGÍA
Y VENEREOLOGÍA

ACTAS Dermo-Sifiliográficas

Full English text available at
www.actasdermo.org



REVIEW

[Translated article] Mpox – Formerly Monkey Pox – in Dermatology: A Review of Epidemiologic Features, Clinical Presentation, Diagnosis, and Treatment

A. Catala*, J. Riera, I. Fuertes

Servicio de Dermatología y Venereología, Hospital Clínic, Barcelona, Spain

Received 23 November 2022; accepted 8 January 2023

Available online 26 February 2023

KEYWORDS

Monkeypox;
Mpox;
Infection;
Zoonosis;
Nonsurgical
dermatology

Abstract Mpox is an emerging zoonotic disease that has spread rapidly around the world. It has been declared a public health emergency of international concern by the World Health Organization. This review is an update for dermatologists on the epidemiology, clinical presentation, diagnosis, and treatment of Mpox. The primary mode of transmission in the current outbreak is close physical contact during sexual activity. Although most of the initial cases were reported in men who have sex with men, anyone who has close contact with an infected person or contaminated fomites is at risk. Classic prodromal features of Mpox include subclinical manifestations and a mild rash. Complications are common but rarely require hospitalization. Polymerase chain reaction analysis of mucocutaneous lesions is the test of choice for a definitive diagnosis. In the absence of specific treatments, management focuses on symptomatic relief. © 2023 AEDV. Published by Elsevier España, S.L.U. This is an open access article under the CC BY-NC-ND license (<http://creativecommons.org/licenses/by-nc-nd/4.0/>).

PALABRAS CLAVE

Viruela del mono;
MPOX;
Infección;
Zoonosis;
Dermatología médica

MPOX (antes viruela del mono): revisión de los aspectos clínicos, epidemiológicos, diagnósticos y terapéuticos más relevantes para el dermatólogo

Resumen MPOX es una enfermedad zoonótica emergente que se ha propagado rápidamente por todo el mundo y que ha sido declarada por la OMS como una emergencia de salud pública de interés internacional. Esta es una revisión no sistemática de los aspectos clínicos, epidemiológicos, diagnósticos y terapéuticos más relevantes para el dermatólogo. En el brote actual, la transmisión durante las relaciones sexuales es la principal forma de contagio como resultado del contacto físico cercano. Si bien los casos iniciales se informaron en hombres que tienen sexo con hombres, cualquier persona en contacto cercano con personas o fómites infectados

DOI of original article: <https://doi.org/10.1016/j.ad.2023.01.002>

* Corresponding author.

E-mail address: albacatal@hotmail.com (A. Catala).

<https://doi.org/10.1016/j.ad.2023.02.012>

0001-7310/© 2023 AEDV. Published by Elsevier España, S.L.U. This is an open access article under the CC BY-NC-ND license (<http://creativecommons.org/licenses/by-nc-nd/4.0/>).

está en riesgo. El pródromo clásico puede ser subclínico y la erupción puede ser sutil. Las complicaciones son frecuentes, pero el requerimiento de hospitalización es infrecuente. El diagnóstico definitivo se realiza mediante PCR de las lesiones mucocutáneas. Actualmente no existen tratamientos específicos, y el tratamiento sintomático es el pilar terapéutico.

© 2023 AEDV. Publicado por Elsevier España, S.L.U. Este es un artículo Open Access bajo la licencia CC BY-NC-ND (<http://creativecommons.org/licenses/by-nc-nd/4.0/>).

Introduction

Mpox (formerly monkey pox) is caused by an orthopoxvirus¹ from the same genus as the *Variola* virus (responsible for smallpox) and the *Vaccinia* virus (used in the smallpox vaccine).² With the eradication of smallpox, Mpox became the most significant and pathogenic orthopoxvirus in humans.

History and Epidemiology

Mpox was first isolated in Denmark from a colony of *Cynomolgus* monkeys transported from a Singapore laboratory for polio virus research.¹ Its ability to cause disease in humans was first recognized in 1970 during intensive surveillance in the Democratic Republic of the Congo (DRC) to ensure the eradication of smallpox.³ These early studies showed that the smallpox vaccination provided 85% protection against Mpox.⁴

Since then, Mpox has mainly been observed in central and western Africa, where it is endemic. Many strains of Mpox and 2 clades of the virus – the Congo Basin clade (clade 1) and the West African clade (clade 2) – have been identified and sequenced.^{5,6}

The increase in Mpox cases in Africa since 2016 has been particularly notable in the DRC, Nigeria, the Central African Republic, Liberia, and Sierra Leone.⁷ Prior to the current outbreak, the largest outbreak in humans outside the DRC occurred in Nigeria in 2017 and 2018.⁶

The first cases of Mpox in humans outside Africa were reported in several US states between May and June 2003, with 47 confirmed or probable cases.⁸ Most were zoonotic and had been caused by contact with infected prairie dogs. Person-to-person spread was not reported, and the likely source of infection was considered to be indirect contact.⁹

In February 2022, Bunge et al.¹⁰ published a systematic review on the changing epidemiology of Mpox in humans that dramatically illustrated the progressive rise in cases.^{11–13}

A few months later, on May 7, 2022, a case of Mpox involving a UK citizen who had returned from Nigeria was confirmed in England.¹⁴ The outbreak spread rapidly, with several countries in the European Union reporting cases not linked to endemic areas.¹⁵

On July 23, 2022, the World Health Organization (WHO) declared the 2022 Mpox outbreak a public health emergency of international concern.¹⁶

Transmission Route and Contagion

As a zoonotic disease, Mpox is acquired through contact with an infected animal (body fluids, bites, or ingestion of bush meat).¹⁷ The reservoir is unknown, but it is likely to be rodent.¹⁸ Viral particles can enter the body through broken skin, the respiratory tract, or mucosal surfaces (e.g., mouth, nose, vagina, anus, conjunctiva).^{19,20} Evidence of Mpox infection has been found in many types of animals in Africa (squirrels, rats, African dormouse, and monkeys), but like humans, these are incidental hosts.

Person-to-person spread can occur in several ways,^{19,20} namely via

- direct contact: contact with wounds, scabs, or infectious body fluids, facilitated by mucosal microabrasions
- indirect contact through fomites
- respiratory secretions: through microdroplets during prolonged close contact
- vertical transmission: through the placental barrier, causing congenital Mpox

Infections caused by orthopoxviruses can be classified as systemic or localized depending on the route of entry.^{20–22} Systemic disease following a respiratory infection usually manifests as a diffuse rash, viremia, and spread of the virus to internal organs. Subcutaneous inoculation, by contrast, may cause a localized rash at the site of entry, with involvement of the regional lymphatic system, followed or not by a few disseminated lesions.

Prior to the 2022 outbreak, transmission outside the family environment and sustained person-to-person spread were rare. The suspected route of transmission in 95% of patients in the outbreak starting in 2022, however, was sexual contact.²³ Between 23% and 26% of patients had a regular sexual partner with Mpox,^{23–25} compared with between 1% and 3% who had been exposed to a contact in the home environment.^{24,26} Just 1% of patients had been infected as the result of an occupational contact (health care provider).²⁴ In most cases, it was difficult to conduct full contact tracing and identify the source of the infection.

Mpox DNA has been detected in saliva, rectal, nasopharyngeal, semen, urine, and fecal samples, suggesting that body fluids might have an important role in transmission.²⁷

One study of viral loads in different locations found higher loads in skin versus pharyngeal swabs,²⁶ suggesting that direct contact is the main transmission route in the current outbreak, with respiratory secretions playing a lesser role. Few asymptomatic infections have been described,²⁸ and in these cases, it was not actually possible to confirm

whether the patients were completely asymptomatic or just paucisymptomatic.

A person is considered to be infectious from the onset of symptoms to re-epithelialization of all lesions, a process that can last 2 to 4 weeks or more. Persistent positivity (>3 weeks) has been demonstrated by polymerase chain reaction (PCR) in blood and upper respiratory tract samples,²⁹ but the significance of these findings in terms of infectivity is unclear. Based on studies of replication-competent viruses in some studies,^{30,31} infectivity time might actually be shorter.

Clinical Manifestations

Endemic Form

Affected Population

Historically, children have been affected most by Mpox. Against an increasing number of cases in the DRC in the 1980s, patients vaccinated against smallpox were found to have a milder rash and less swollen lymph nodes, and there were no associated deaths.^{32,33}

Clinical Characteristics

Incubation time, which varies between 5 and 13 days (range, 4–21 days)⁹ could be shorter after invasive exposure (animal bites or scratches) compared with noninvasive exposure (touch).⁹

Mpox has traditionally caused systemic disease, which can be divided into 2 periods: an invasion period and a rash period.³⁴

Invasion period. In endemic areas, where the main route of transmission is respiratory, the invasion period lasts from 0 to 5 days. Systemic symptoms are common and precede the rash (prodromal stage) or occur shortly afterwards (early clinical stage). Symptoms described include^{6,17,18,20}

- fever (88%)
- intense headache (79%)
- swollen lymph nodes (69%):
 - inguinal and cervical
 - distinctive feature in relation to other diseases (chickenpox, measles, smallpox).
- myalgia (63%)
- odynophagia (58%)
- profound weakness or fatigue

Skin rash period. This usually starts within 1 to 3 days of fever onset.³⁵ In endemic areas, the rash tends to affect the

- face (96%)
- legs (91%)
- trunk (80%)
- arms (79%)
- palms (69%)
- genitalia (68%)
- soles (64%)

Lesion numbers vary from several to thousands,³² although the mean count at presentation has been estimated at 370.⁶

Sequelae, Severity, and Case Fatality

Blood tests show multiple nonspecific findings, such as abnormal aminotransferases, leukocytosis, thrombocytopenia, and hypoalbuminemia.³³

Severe Mpox is more common among children and is related to

- extent of virus exposure
- health status
- complications
- access to quality healthcare

Data on disease severity in immunocompromised patients is scarce. In previous outbreaks, advanced HIV infection was linked to an increased risk of severe disease, with more and longer-lasting lesions.³³

The most common complications are pain, ulceration, and bacterial superinfection. Complications affecting other organs have also been described, such as meningoencephalitis, myocarditis, bronchopneumonia, and kidney failure. Neurological involvement and sepsis due to bacterial superinfection have the highest mortality risk.¹⁹ Similarly to in smallpox, the most common sequelae in Mpox are scars.

Historically, the case fatality rate in Africa has been 1% to 10% (depending on the clade), although the figure has lowered in recent years (3% to 6%).¹⁹

Clinical Characteristics During the 2022 Outbreak

Several series have been published since the start of the 2022 outbreak.^{23–26,36,37} The data are very similar across the studies and show features that differentiate this outbreak from previous ones. The median incubation period has been estimated at 6 to 9 days (range, 4–10 days).^{24,26,38,39}

Affected Population

The current outbreak predominantly affects men who have sex with men (MSM), with a median age of 38 years. It should be noted, however, that the mode of community transmission may change. Case rates are very high among patients with (generally well-controlled) HIV coinfection, and high rates have also been reported for HIV-negative people on pre-exposure prophylaxis (PrEP).^{23–26,36,37}

Risk factors for sexually transmitted infections (STIs) are present in a high proportion of patients, with over 50% of Mpox patients who underwent STI screening testing positive for at least 1 STI.^{24,25}

Clinical Characteristics

Similarly to with other poxviruses (orf and molluscum), primary lesions in inoculated areas are usually pseudopustules (solid papules that look like pustules but in which it is impossible to scrape the roof and obtain pus) (Fig. 1).²⁴ These findings have been confirmed histologically.⁴⁰ Inoculation lesions vary in number and are mainly observed in the genital or perianal regions (Fig. 2) or on the face²⁴ (Table 1). The lesions are usually well-circumscribed, umbilicated, deep lesions that are described as painful and take weeks to heal completely. In some cases, they have a tendency to coalesce or become necrotic, and hence become ulcerated. They are usually accompanied by swollen regional lymph

Table 1 Summary of Main Characteristics of Mpox Cases Published in the 2022 Outbreak.

Study	N Engl J Med Thornhill et al. ²³	BMJ Patel et al. ²⁵	Lancet Tarín-Vicente et al. ²⁶	Br J Dermatol Català et al. ²⁴	Clin Microbiol Infect Mailhe et al. ³⁷
No.	528	197	181	185	264
Sex	Male > 99%	Male 100%	Male 97%	Male 100%	Male 99%
	Transgender < 1%	Female 0%	Female 3%	Female 0%	Female 1%
Mean age, y	38	38	37	38.7	35
Sexual orientation	MSM or 99% bisexual Heterosexual 1%	MSM or > 99% bisexual	MSM or 92% bisexual Heterosexual 8%	MSM or 99% bisexual Heterosexual 1%	MSM 95%
HIV	41%	35.9%	40%	42%	29%
	Viral load < 50 copies/mL 95% ≠ ART therapy 96%	Viral load < 50 copies/mL 78.6%	CD4 > 500 cells/ μ L 89%	Viral load < 50 copies/mL 92%	
If HIV(–) PrEP user	57%	–	–	77%	71%
History of smallpox vaccination	9%	–	18%	11%	12%
Cutaneous lesions, No. (%)	< 5 (39%) 5–10 (25%) 11–20 (21%) > 20 (11%)	1 (11.2%) 2–10 (51.8%) 11–50 (18.3%) 51–100 (0%) \geq 100 (4.1%)	1–2 (12%) 3–20 (80%) > 20 (8%)	1 (11%) 2–25 (82%) 26–100 (6%) > 100 (1%)	Mean 5 Range, 3–10
Extracutaneous manifestations					
Swollen lymph nodes	56%	57.9% (mostly inguinal or cervical)	85% (mostly inguinal or cervical)	56%	69%
Fever	62%	61.9%	72%	54%	68%
Weakness or fatigue	41%	23.4%	81%	44%	–
Myalgia	31%	31.5%		44%	–
Headache	27%	24.8%	53%	32%	35%
Odynophagia	21%	16.8%	36%	18%	20%

Abbreviations: ART, antiretroviral therapy; MSM, men who have sex with men; PrEP, pre-exposure prophylaxis.

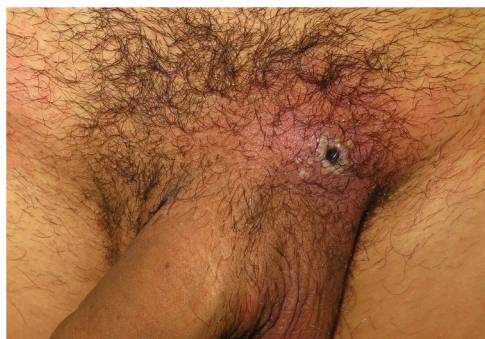

Figure 1 Lesion at inoculation site. Confluent pseudopustules with a depressed necrotic center associated with perilesional erythema and edema.

nodes and surrounding edema, which in some cases can be very severe.

Other forms of presentation include perioral pseudopustules, lesions on the tongue—which are usually white papules with a central depression—or ulcerated lesions of the oral

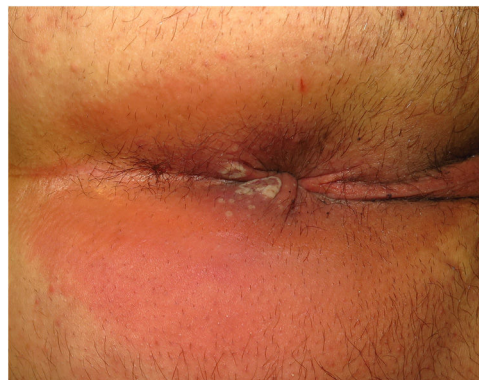

Figure 2 Multiple perianal pseudopustules, some crater-shaped with erosive centers.

mucosa or lips. Solitary primary lesions forming a whitlow have also been observed on the fingers.²⁴

This first phase may be followed by a secondary rash with lesions that progress from macules to vesicles, pustules, and scabs. (This need not occur simultaneously.) These

lesions are described as pruritic and take days to resolve. They are located on the face, scalp, arms, legs, palms, soles, and trunk. Although extracutaneous manifestations are very common^{24–26,36,37} and generally occur in association with cutaneous manifestations, just 36% of patients report prodromal symptoms before the onset of skin lesions.²⁴ Between 6% and 13.7% of patients develop a maculopapular morbilliform rash,^{24,25} which may be due to an immune phenomenon analogous to that of other viral infections, such as those caused by Epstein-Barr virus, cytomegalovirus, and SARS-CoV-2. Depending on the context, however, other possibilities such as a toxic drug reaction and secondary syphilis must be ruled out.

Mucocutaneous Complications, Severity, and Case Fatality

Mpox is mostly a mild, self-limiting, disease that resolves in 1 to 4 weeks. Some patients, however, may develop serious complications or illnesses.

Proctitis. Between 14% and 36% of patients experience anorectal pain, tenesmus, constipation, purulent discharge, or bleeding,^{23–26,36,37} accompanied or not by visible lesions in the perianal area. These patients usually have a history of receptive anal intercourse and more frequently develop a systemic prodrome.²⁶ Proctoscopy is not recommended given the intense associated pain. Magnetic resonance imaging is preferable when rectal perforation is suspected (intense pain or signs of sepsis).²⁵ Other causes of proctitis must always be ruled out.

Ulcerative tonsillopharyngitis. Odynophagia and dysphagia have been described in between 10% and 21% of patients.^{22–26,36,37} They occur in association with nonspecific ulcerative plaques on the palatine tonsils or pharynx and are generally accompanied by painful, swollen cervical lymph nodes. Mpox should be ruled out in areas with high transmission rates and in patients with epidemiological risk factors and a negative rapid antigen test for group A *Streptococcus*.²⁶

Genital edema. Lesions on the penis, especially on the penile glans, foreskin, and urinary meatus, may be associated with glans and foreskin swelling that can cause paraphimosis (8%–16% of reported cases).^{22–26,36,37} Urologic evaluation may be required.

Severe bacterial superinfection. Progressive swelling, pain, and worsening ulcerative lesions can indicate a secondary bacterial infection that may require hospitalization and intravenous treatment.²⁵ This complication was reported in 3%–4% of cases in the 2022 outbreak.^{22–26,36,37} Sample collection for culture and antibiogram is recommended, as multiresistant bacteria have been detected.²⁵

Eye involvement. Eye involvement in the form of conjunctivitis, blepharitis, eyelid papules or edema, corneal ulcers, and/or periorbital cellulitis has been reported.⁴¹ Corneal involvement in particular can compromise vision and requires a rapid response in collaboration with the ophthalmology department.

Hospitalization was uncommon during the 2022 outbreak (1–13% of all reported cases). The main reason for admission was intravenous treatment for pain control. Other reasons were management of complications (secondary infections, penile edema, dysphagia, encephalitis, ocular disease,

myocarditis) or proper isolation.^{22–26,36,37} Case fatality rates in western countries have been very low (<0.1%) compared with those reported for African outbreaks.⁴²

Similarly to in the 2003 US outbreak,³³ prior smallpox vaccination was not associated with symptom severity.^{22–26} Severity also did not differ between patients with or without HIV infection. It should be noted, however, that most patients with HIV coinfection in the 2022 outbreak were receiving effective antiretroviral therapy and are a well-controlled population, unlike previous cases involving patients with advanced-stage HIV.^{33,43}

Diagnosis

Mpox is diagnosed on the basis of epidemiological, clinical, and laboratory findings. The case definitions proposed by the European Centre for Disease Prevention and Control (ECDC) are provided in [Table 2](#).⁴⁴

The following entities should be entertained in the differential diagnosis: chickenpox, herpes zoster infection, measles, Zika virus infection, dengue, chikungunya, herpes simplex, impetigo, methicillin-resistant *Staphylococcus aureus* infection, disseminated or localized gonorrhoea, primary or secondary syphilis, chancroid, lymphogranuloma venereum, and molluscum contagiosum.

Patients who meet the criteria for a suspected or probable case of Mpox should undergo specific PCR testing for this or other orthopoxviruses, which should then be confirmed by sequencing. If negative, these patients should be excluded.

Sequencing of genomes obtained in Spain showed that they belong to the West African clade and are almost identical to genomes uploaded in other European countries.⁴⁵

Isolation, Quarantine, and Contact Tracing

Patients who undergo diagnostic PCR should remain isolated until results are available. Contact and respiratory isolation must be maintained throughout the infectious period. Respiratory isolation is an empirical precaution, and some authors have speculated that the degree of viremia following inoculation is low or absent, meaning that there would be minimal replication in the respiratory tract and little or no transmission through respiratory droplets.²⁶

Mpox is a notifiable disease. Contact tracing, even if incomplete, can help reduce the spread of the virus.⁴⁶ Quarantine for asymptomatic contacts following exposure to Mpox should be considered on a case-by-case basis.

Information on transmission during the 2022 outbreak is emerging rapidly. It is unknown whether viral DNA detected in samples from asymptomatic individuals is replication competent. One study conducted in Israel highlighted the strong correlation between Mpox quantification cycle (Cq) levels and virus infectivity and defined a threshold for predicting slightly infectious or noninfectious specimens (Cq \geq 35; viral DNA \leq 4300 copies/mL).⁴⁷

Table 2 Criteria for Suspected, Probable, and Confirmed Cases According to the Criteria of the European Centre for Disease Prevention and Control.⁴⁰**Suspected case**

(a) A person who is a contact of a probable or confirmed Mpox case in the 21 days before the onset of signs or symptoms, and who presents with any of the following: acute onset of fever (>38.5 °C), headache, myalgia (muscle pain/body aches), back pain, profound weakness or fatigue

OR

(b) A person presenting since January 1, 2022 with an unexplained acute skin rash, mucosal lesions, or swollen lymph nodes. The skin rash may include single or multiple lesions in the anogenital region or elsewhere on the body. Mucosal lesions may include single or multiple oral, conjunctival, urethral, penile, vaginal, or anorectal lesions. Anorectal lesions can also manifest as anorectal inflammation (proctitis), pain, and/or bleeding.

And for which other causes have been ruled out: varicella zoster, herpes zoster, measles, herpes simplex, bacterial skin infections, disseminated gonococcus infection, primary or secondary syphilis, chancroid, lymphogranuloma venereum, granuloma inguinale, molluscum contagiosum, allergic reaction (e.g., to plants), and any other locally relevant common causes of papular or vesicular rash

Probable case

A person presenting with an unexplained acute skin rash, mucosal lesions, or swollen lymph nodes. The skin rash may include single or multiple lesions in the anogenital region or elsewhere on the body. Mucosal lesions may include single or multiple oral, conjunctival, urethral, penile, vaginal, or anorectal lesions. Anorectal lesions can also manifest as anorectal inflammation (proctitis), pain and/or bleeding.

AND

1 or more of the following:

1. has an epidemiological link^a to a probable or confirmed case of Mpox in the 21 days before symptom onset
2. identifies as gay, bisexual, or other cisgender or transgender man who has sex with men
3. has had multiple and/or casual sexual partners in the 21 days before symptom onset
4. has detectable levels of anti-orthopoxvirus immunoglobulin (Ig) M antibody^b (during the period of 4–56 days after rash onset) or a 4-fold rise in IgG antibody titer based on acute (up to day 5–7) and convalescent (day 21 onwards) samples in the absence of a recent smallpox/Mpox vaccination or other known exposure to orthopoxvirus
5. has a positive test result for orthopoxvirus infection (e.g., orthopoxvirus-specific polymerase chain reaction [PCR]) without Mpox-specific PCR or sequencing^c

Confirmed case

A person with laboratory-confirmed Mpox infection by detection of unique sequences of viral DNA by PCR^c and/or sequencing

^a The person has been exposed to a probable or confirmed Mpox case. A contact is defined as a person who has been exposed to an infected person during the infection period, i.e., the period beginning with the onset of the index case's first symptoms and ending when all scabs have fallen off, and who has 1 or more of the following exposures with a probable or confirmed case of Mpox: a) direct skin-to-skin and skin-to-mucosal physical contact (such as touching, hugging, kissing, and intimate or sexual contact); b) contact with contaminated materials such as clothing or bedding, including material dislodged from bedding or surfaces during handling of laundry or cleaning of contaminated rooms; c) prolonged face-to-face respiratory exposure in close proximity; d) respiratory exposure (i.e., possible inhalation of) or eye mucosal exposure to lesion material (e.g., scabs/crusts) from an infected person; e) the former also apply for health workers potentially exposed in the absence of proper use of appropriate personal protective equipment.

^b Serology can be used for retrospective case classification for a probable case in specific circumstances such as when diagnostic testing through PCR of skin lesion specimens has not been possible, or in the context of research with standardized data collection. The primary diagnostic test for Mpox diagnosis is PCR of skin lesion material or another specimen such as an oral or nasopharyngeal swab as appropriate. Serology should not be used as a first-line diagnostic test.

^c PCR on a blood specimen may be unreliable and should also not be used alone as a first-line diagnostic test. If blood PCR is negative and was the only test done, this is not sufficient to discard a case that otherwise meets the definition of a suspected or probable case.

Treatment

Currently, there are no treatments specifically approved for Mpox by the US Food and Drug Administration (FDA) or the European Medicines Agency (EMA). Symptomatic treatment thus is the mainstay option and consists of¹⁵

- antipyretics
- nonsteroidal anti-inflammatory drugs
- topical corticosteroids (or systemic when there is significant inflammation)
- painkillers
- creation of a clean, moist microenvironment with covering of infectious ulcers to potentially mitigate transmission and favor re-epithelialization of the exanthem
- appropriate antibiotics to treat secondary bacterial infections

Antivirals approved for the treatment of smallpox may be prescribed.

- Tecovirimat is the only antiviral with EMA approval for the treatment of orthopoxvirus infections, including Mpox.
- Brincidofovir has FDA but not EMA approval for the treatment of Mpox.
- Cidofovir has demonstrated in vitro activity against smallpox, but nephrotoxicity associated with systemic use makes it unsuitable as a first-line treatment. Topical off-label use, however, does seem to be associated with a shorter time to resolution of lesions and better cosmetic outcomes.⁴⁸

The risks and benefits of initiating specific treatments should be weighed up and local guidelines followed.⁴⁹

Vaccines

Smallpox vaccination may provide cross-protection of up to an estimated 85% against Mpox.⁴ This protective effect diminishes with time (>20 years), although lifelong protection against severe disease might be provided through B and T memory cells.⁵⁰

Early off-label smallpox vaccination (within 4 days of exposure) may prevent Mpox or reduce its severity.⁵⁰

A third-generation, nonreplicating vaccine (Imvanex, modified vaccinia virus Ankara) has been licensed for use against smallpox and been recommended for people at risk^{51,52}:

- People who engage in high-risk sexual practices, mainly but not exclusively MSM on PrEP or with HIV infection, and
- People with occupational risk, such as health personnel in STI/HIV clinics, laboratory staff handling potentially contaminated samples, and personnel in charge of cleaning surfaces in specialized clinics.

Previous-generation smallpox vaccines (Dryvax and ACAM2000) are no longer authorized in the European Union due to their adverse effects.

The standard regimen involves a 0.5-mL subcutaneous injection (2 doses with a 28-day interval). Against a background of vaccine shortages and global demand, the EMA approved an alternative intradermal regimen of 0.1-mL (2 doses with a 28-day interval) on August 19, 2022.⁵³

Conclusions

Mpox is an emerging zoonotic disease that has spread rapidly around the world. There is concern that its continued spread will lead to new endemic areas.

Sexual contact was the main route of transmission during the 2022 Mpox outbreak. Although the earliest cases were primarily reported in MSM, anyone in contact with infected people, animals, or contaminated fomites is at risk of developing the disease within 21 days.

Systemic prodromal features may be subclinical, and the rash (which can be mild) may start in the genital or anal

regions. Typical pseudopustules and swollen lymph nodes are useful findings for distinguishing Mpox from other diseases.

Local complications are common though not generally serious.

A definitive diagnosis of Mpox requires PCR detection of viral DNA in a lesion sample. STI coinfection is possible and common.

Conflicts of Interest

The authors declare that they have no conflicts of interest.

References

1. Von Magnus P, Andersen EK, Petersen KB, Birch-Andersen A. A pox-like disease in Cynomolgus monkeys. *Acta Pathol Microbiol Scand.* 2009;46:156–76.
2. Monkeypox. Available from: www.who.int/news-room/fact-sheets/detail/monkeypox [cited 2022 Oct 31].
3. Ladnyj ID, Ziegler P, Kima E. A human infection caused by monkeypox virus in Basankusu Territory Democratic Republic of the Congo. *Bull World Health Organ.* 1972;46:593–7.
4. Fine PEM, Jezek Z, Grab B, Dixon H. The transmission potential of Monkeypox Virus in human populations. *Int J Epidemiol.* 1988;17:643–50.
5. Weinstein RA, Nalca A, Rimoin AW, Bavari S, Whitehouse CA. Reemergence of Monkeypox: prevalence, diagnostics, and countermeasures. *Clin Infect Dis.* 2005;41:1765–71.
6. Yinka-Ogunleye A, Aruna O, Dalhat M, Ogoina D, McCollum A, Disu Y, et al. Outbreak of human monkeypox in Nigeria in 2017–18: a clinical and epidemiological report. *Lancet Infect Dis.* 2019;19:872–9.
7. Durski KN, McCollum AM, Nakazawa Y, Petersen BW, Reynolds MG, Briand S, et al. Emergence of Monkeypox – West and Central Africa, 1970–2017. *MMWR Morb Mortal Wkly Rep.* 2018;67:306–10.
8. Hammarlund E, Lewis MW, Carter SV, Amanna I, Hansen SG, Strelow LI, et al. Multiple diagnostic techniques identify previously vaccinated individuals with protective immunity against monkeypox. *Nat Med.* 2005;11:1005–11.
9. Reynolds MG, Yorita KL, Kuehnert MJ, Davidson WB, Huhn GD, Holman RC, et al. Clinical manifestations of human monkeypox influenced by route of infection. *J Infect Dis.* 2006;194:773–80.
10. Bunge EM, Hoet B, Chen L, Lienert F, Weidenthaler H, Baer LR, et al. The changing epidemiology of human monkeypox – a potential threat? A systematic review. *PLoS Negl Trop Dis.* 2022;16:e0010141.
11. Damon IK, Roth CE, Chowdhary V. Discovery of Monkeypox in Sudan. *N Engl J Med.* 2006;355:962–3.
12. Monkeypox – United States of America. Available from: <https://www.who.int/emergencies/disease-outbreak-news/item/monkeypox-the-united-states-of-america> [cited 2022 Oct 31].
13. Monkeypox – United Kingdom of Great Britain and Northern Ireland. Available from: <https://www.who.int/emergencies/disease-outbreak-news/item/monkeypox-united-kingdom-of-great-britain-and-northern-ireland> [cited 2022 Oct 31].
14. Monkeypox cases confirmed in England – latest updates. Available from: <https://www.gov.uk/government/news/monkeypox-cases-confirmed-in-england-latest-updates> [cited 2022 Oct 31].
15. Updates on EU/EEA countries, the Western Balkans and Türkiye. Available from: <https://www.ecdc.europa.eu/en/news-events/monkeypox-situation-update> [cited 2022 Oct 31].

16. Second meeting of the International Health Regulations (2005) (IHR) Emergency Committee regarding the multi-country outbreak of monkeypox. Available from: [https://www.who.int/news/item/23-07-2022-second-meeting-of-the-international-health-regulations-\(2005\)-\(ihr\)-emergency-committee-regarding-the-multi-country-outbreak-of-monkeypox](https://www.who.int/news/item/23-07-2022-second-meeting-of-the-international-health-regulations-(2005)-(ihr)-emergency-committee-regarding-the-multi-country-outbreak-of-monkeypox) [cited 2022 Oct 31].
17. Koenig KL, Bej CK, Marty AM. Monkeypox 2022 Identify-Isolate-Infom: a 3I Tool for frontline clinicians for a zoonosis with escalating human community transmission. *One Health*. 2022;15:100410.
18. Vaughan A, Aarons E, Astbury J, Brooks T, Chand M, Flegg P, et al. Human-to-human transmission of monkeypox virus, United Kingdom, October 2018. *Emerg Infect Dis*. 2020;26:782–5.
19. Farahat RA, Abdelaal A, Shah J, Ghazy S, Sah R, Bonilla-Aldana DK, et al. Monkeypox outbreaks during COVID-19 pandemic: are we looking at an independent phenomenon or an overlapping pandemic? *Ann Clin Microbiol Antimicrob*. 2022;21:26.
20. Mitjà O, Ogoina D, Titanji BK, Galvan C, Muyembe J-J, Marks M, et al. Monkeypox. *Lancet*. 2023;401:60–2174.
21. Saijo M, Ami Y, Suzaki Y, Nagata N, Iwata N, Hasegawa H, et al. Virulence and pathophysiology of the Congo Basin and West African strains of monkeypox virus in non-human primates. *J Gen Virol*. 2009;90:2266–71.
22. Zaucha GM, Jahrling PB, Geisbert TW, Swearngen JR, Hensley L. The pathology of experimental aerosolized monkeypox virus infection in *Cynomolgus* monkeys (*Macaca fascicularis*). *Lab Invest*. 2001;81:1581–600.
23. Thornhill JP, Barkati S, Walmsley S, Rockstroh J, Antinori A, Harrison LB, et al. Monkeypox virus infection in humans across 16 countries – April–June 2022. *N Engl J Med*. 2022;387:679–91.
24. Català A, Clavo-Escribano P, Riera-Monroig J, Martín-Ezquerria G, Fernandez-Gonzalez P, Revelles-Peñas L, et al. Monkeypox outbreak in Spain: clinical and epidemiological findings in a prospective cross-sectional study of 185 cases. *Br J Dermatol*. 2022;187:765–72.
25. Patel A, Bilinska J, Tam JCH, Da Silva Fontoura D, Mason CY, Daunt A, et al. Clinical features and novel presentations of human monkeypox in a central London centre during the 2022 outbreak: descriptive case series. *BMJ*. 2022;378:e072410.
26. Tarín-Vicente EJ, Alemany A, Agud-Dios M, Ubals M, Suñer C, Antón A, et al. Clinical presentation and virological assessment of confirmed human monkeypox virus cases in Spain: a prospective observational cohort study. *Lancet*. 2022;400:661–9.
27. Peiró-Mestres A, Fuertes I, Camprubi-Ferrer D, Marcos MÁ, Vilella A, Navarro M, et al. Frequent detection of monkeypox virus DNA in saliva, semen, and other clinical samples from 12 patients Barcelona, Spain, May to June 2022. *Euro Surveill*. 2022;27:2200503.
28. De Baetselier I, Van Dijck C, Kenyon C, Coppens J, Michiels J, de Block T, et al. Retrospective detection of asymptomatic monkeypox virus infections among male sexual health clinic attendees in Belgium. *Nat Med*. 2022;28:2288–92.
29. Zachary KC, Shenoy ES. Monkeypox transmission following exposure in healthcare facilities in nonendemic settings: low risk but limited literature. *Infect Control Hosp Epidemiol*. 2022;43:920–4.
30. Suñer C, Ubals M, Tarín-Vicente EJ, Mendoza A, Alemany A, Hernández-Rodríguez Á, et al. Viral dynamics in patients with monkeypox infection: a prospective cohort study in Spain. *Lancet Infect Dis*. 2022;12:S1473-3099(22)00794-0.
31. Dunning J, Ochu C. An opportunity seized: rapid clinical research provides insights into monkeypox virus dynamics and durations of infectiousness. *Lancet Infect Dis*. 2022;12: S1473-3099(22)00829-5.
32. Di Giulio DB, Eckburg PB. Human monkeypox: an emerging zoonosis. *Lancet Infect Dis*. 2004;4:15–25.
33. Huhn GD, Bauer AM, Yorita K, Graham MB, Sejvar J, Likos A, et al. Clinical characteristics of human monkeypox, and risk factors for severe disease. *Clin Infect Dis*. 2005;41:1742–51.
34. National Monkeypox Public Health Response Guidelines. Copyright ©2019 Federal Ministry of Health – Nigeria Centre for Disease Control.
35. Jezek Z, Szczeniowski M, Paluku KM, Mutombo M, Grab B. Human monkeypox: confusion with chickenpox. *Acta Trop*. 1988;45:297–307.
36. Girometti N, Byrne R, Bracchi M, Heskin J, McOwan A, Tittle V, et al. Demographic and clinical characteristics of confirmed human monkeypox virus cases in individuals attending a sexual health centre in London, UK: an observational analysis. *Lancet Infect Dis*. 2022;22:1321–8.
37. Mailhe M, Beaumont AL, Thy M, Le Pluart D, Perrineau S, Houhou-Fidouh N, et al. Clinical characteristics of ambulatory and hospitalized patients with monkeypox virus infection: an observational cohort study. *Clin Microbiol Infect*. 2023;29:233–9, <http://dx.doi.org/10.1016/j.cmi.2022.08.012>.
38. Miura F, van Ewijk CE, Backer JA, Xiridou M, Franz E, Op de Coul E, et al. Estimated incubation period for monkeypox cases confirmed in the Netherlands, May 2022. *Euro Surveill*. 2022;27.
39. Guzzetta G, Mammone A, Ferraro F, Caraglia A, Rapiti A, Marziano V, et al. Early estimates of monkeypox incubation period, generation time, and reproduction number, Italy, May–June 2022. *Emerg Infect Dis*. 2022;28:2078–81.
40. Maronese CA, Beretta A, Avallone G, Boggio FL, Marletta DA, Murgia G, et al. Clinical, dermoscopic and histopathological findings in localized human monkeypox: a case from northern Italy. *Br J Dermatol*. 2022;187:822–3.
41. Abdelaal A, Serhan HA, Mahmoud MA, Rodríguez-Morales AJ, Sah R. Ophthalmic manifestations of monkeypox virus. *Eye (Lond)*. 2023;37:383–5, <http://dx.doi.org/10.1038/s41433-022-02195-z>.
42. 2022 Mpx (Monkeypox) Outbreak: Global Trends. Available from: <https://worldhealthorg.shinyapps.io/mpx-global/> [cited 2022 Oct 31].
43. Viguier C, de Kermel T, Boumaza X, Benmedjahed NS, Izopet J, Pasquier C, et al. A severe monkeypox infection in a patient with an advanced HIV infection treated with tecovirimat: clinical and virological outcome. *Int J Infect Dis*. 2022;125:135–7.
44. Monkeypox (MPX) Reporting Protocol Version 3.2, 23 September 2022. Available from: <https://www.ecdc.europa.eu/sites/default/files/documents/MPX.Reporting%20Protocol.v3.2.pdf> [cited 2022 Oct 31].
45. Second draft genome from Spain of the Monkeypox virus 2022 outbreak. Available from: <https://virological.org/t/second-draft-genome-from-spain-of-the-monkeypox-virus-2022-outbreak/846> [cited 2022 Oct 31].
46. Rivers C. Don't lose sight of monkeypox containment. *Nature*. 2022;609:10.
47. Paran N, Yahalom-Ronen Y, Shifman O, Lazar S, Ben-Ami R, Yakubovsky M, et al. Monkeypox DNA levels correlate with virus infectivity in clinical samples, Israel, 2022. *Euro Surveill*. 2022;27:2200636.
48. Sobral-Costas TG, Escudero-Tornero R, Servera-Negre G, Bernardino JI, Arroyo AG, Díaz-Menéndez M, et al. Human monkeypox outbreak: epidemiological data and therapeutic potential of topical cidofovir in a prospective cohort study. *J Am Acad Dermatol*. 2022, <http://dx.doi.org/10.1016/j.jaad.2022.10.043>. S0190-9622(22)02970-X.
49. Desai AN, Thompson GR, Neumeister SM, Arutyunova AM, Trigg K, Cohen SH. Compassionate use of tecovirimat for the treatment of monkeypox infection. *JAMA*. 2022;328:1348.
50. Van Dijck C, Hens N, Kenyon C, Tsoumanis A. The roles of unrecognized monkeypox cases contact isolation

- and vaccination in determining epidemic size in Belgium: a modeling study. *Clin Infect Dis.* 2023;76:e1421–3, <http://dx.doi.org/10.1093/cid/ciac723>.
51. Spicknall IH, Pollock ED, Clay PA, Oster AM, Charniga K, Masters N, et al. Modeling the impact of sexual networks in the transmission of monkeypox virus among gay bisexual, and other men who have sex with men – United States, 2022. *MMWR Morb Mortal Wkly Rep.* 2022;71:1131–5.
 52. Suárez Rodríguez B, Guzmán Herrador BR, Díaz Franco A, Sánchez-Seco Fariñas MP, Del Amo Valero J, Aginagalde Llorente AH, et al. Epidemiologic features and control measures during monkeypox outbreak, Spain, June 2022. *Emerg Infect Dis.* 2022;28:1847–51.
 53. EMA's Emergency Task Force advises on intradermal use of Imvanex/Jynneos against monkeypox. Available from: <https://www.ema.europa.eu/en/news/emas-emergency-task-force-advises-intradermal-use-imvanex-jynneos-against-monkeypox> [accessed 31.10.22].