

CASES FOR DIAGNOSIS

Long-term Unilateral Enlargement of the Nipple



Agrandamiento unilateral y prolongado del pezón

Case history

A 76-year-old male with no past medical history of interest was presented with a thirty-year history of pruritus and unilateral enlargement of the left nipple.

Physical examination

Cutaneous examination showed a one-centimeter enlargement of the left nipple (Fig. 1A). Dermoscopy revealed milky-red areas with central ulceration and polymorphous vessels (Fig. 1B). No other breast lesions were detected and no axillary lymphadenopathy was palpated.

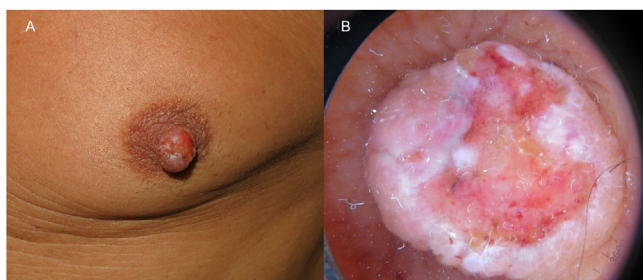


Figure 1

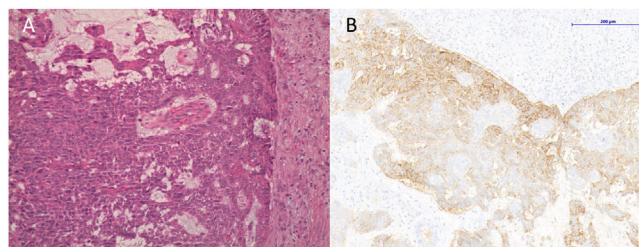


Figure 2 (A) Hematoxylin-eosin, 20 \times . (B) Staining with Ber-EP4, 11 \times .

Histopathology

A punch biopsy was performed. Hematoxylin-eosin staining showed a non-encapsulated proliferation of small irregular clumps of basaloid cells with peripheral palisading and a highly infiltrative growth pattern (Fig. 2A). In the immunohistochemical study, the cells stained positive for Ber-EP4 (Fig. 2B).

Complementary tests

The mammography and breast magnetic resonance imaging did not reveal significant alterations.

What is your diagnosis?

Diagnosis

Basal Cell Carcinoma (BCC) of the nipple-areola complex (NAC).

Course and treatment

The NAC was excised, confirming the presence of infiltrating BCC. After 10 months of clinical follow-up, no recurrences have been detected.

Comments

BCC of the NAC is extremely rare and it seems to be more prevalent in men. Based on our literature review, 59 cases have been described. However, its incidence may be underestimated.¹⁻⁵ Clinically, it tends to present as a scaly or ulcerated plaque or nodule.² Previous studies have suggested that ultraviolet irradiation might be the main causal factor.³

BCC of the NAC has been suggested to have a higher metastatic potential than other locations, showing a more aggressive course due to the presence of ducts and lymphatic plexus in the NAC.²

The differential diagnosis of the BCC of the NAC would also be with eczema, Paget's disease, Bowen's disease, erosive adenomatosis, melanoma, leiomyoma, adenoma, fibroma, and papilloma of the nipple.^{4,6} Despite histopathology is the gold standard for making the diagnosis, clinical suspect is essential.

Treatment of choice is surgical excision, the most commonly used options are simple excision, wide local excision and Mohs micrographic surgery, nevertheless simple mastectomy has been also reported. Tumor recurrence is uncommon after successful treatment.²

Conflict of interests

The authors declare they have no conflict of interest.

References

1. Alsaedi M, Shoimer I, Kurwa HA. Basal cell carcinoma of the nipple-areola complex. *Dermatol Surg.* 2017;43:142–6.
2. Chun KA, Cohen PR. Basal cell carcinoma of the nipple-areola complex: a comprehensive review of the world literature. *Dermatol Ther (Heidelb).* 2016;6:379–95.
3. Fujii M, Harimoto A, Namiki T. Basal cell carcinoma of the nipple-areola complex with multiple lesions: possible causative role of radiation. *J Dtsch Dermatol Ges.* 2018;16:193–5.
4. Ulanja MB, Taha ME, Al-Mashhadani AA, Al-Tekreeti MM, Elliot C, Ambika S. Basal cell carcinoma of the female breast masquerading as invasive primary breast carcinoma: an uncommon presentation site. *Case Rep Oncol Med.* 2018;2018:1–4.
5. Lakhmiri M, Meziane M, Znati K, Hassam B, Senouci K. Carcinome basocellulaire pigmenté de la plaque aréolo-mamelonnaire chez un patient transplanté rénal. *Ann Dermatol Venerol.* 2019;146:850–1.
6. Brugués A, Alós L, Fuertes de Vega I. Long-standing nodule of the nipple. *Actas Dermo-Sifiliográficas (English Ed).* 2015;106:501–2.

C. López-Llunell^{a,*}, C. Fernández-Sartorio^a,
E. Sáez Artacho^b

^a *Department of Dermatology, Consorci Corporació Sanitària Parc Taulí, Sabadell, Barcelona, Spain*

^b *Department of Pathology, Consorci Corporació Sanitària Parc Taulí, Sabadell, Barcelona, Spain*

* Corresponding author.

E-mail address: clopezllunell@gmail.com (C. López-Llunell).