



## IMAGES IN DERMATOLOGY

# [Translated article] Annular Plaques on the Foreskin and Scrotum in the Context of Secondary Reinfection Syphilis

## Placas anulares en el prepucio y el escroto en el contexto de una sífilis secundaria reinfección

P. Ruiz-Mesa<sup>a</sup>, M. Blanco-Calvo<sup>b</sup>, A. Martin-Gorgojo<sup>b,\*</sup>

<sup>a</sup> Centro de Atención Primaria Antonio Gutiérrez, Unidad Docente de Atención Primaria de León, Spain

<sup>b</sup> Servicio de ITS/Dermatología, Sección de Especialidades Médicas, Ayuntamiento de Madrid, Madrid, Spain

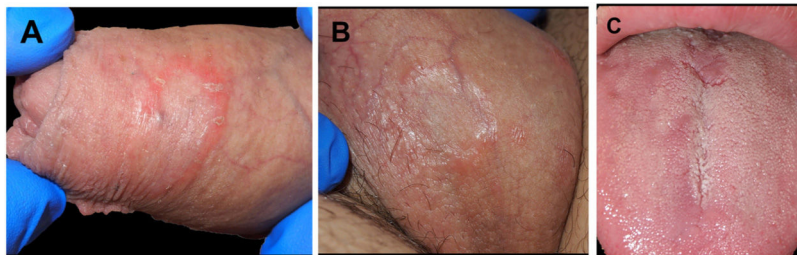


Figure 1

A 40-year-old cis-gender homosexual male patient with a history of HIV infection (undetectable viral load, CD4 count within the normal range, receiving dolutegravir/lamivudine) and 2 episodes of secondary syphilis in the past, attended the clinic for assessment of a desquamative, asymptomatic, erythematous plaque with an annular pattern on the foreskin (Fig. 1A). Given the circinate appearance of the lesion, he was treated with antifungal and anti-inflammatory cream and screened for venereal infections.

At the follow-up visit, the lesion on the foreskin had not improved, and new asymptomatic lesions were identified on the scrotum (Fig. 1B) and on the dorsum of the tongue (Fig. 1C). Serology revealed immunoglobulin G and M against *Treponema pallidum*, with a rapid plasma reagin titer of 1:32.

The other screening tests did not reveal additional findings. Given the diagnosis of secondary reinfection syphilis (supported by the positive rapid plasma reagin results with a 1/1 titer 3 months earlier), we administered a single intramuscular dose of benzylpenicillin G benzathine (2.4 million IU). The lesions had improved 1 week after treatment.

The incidence of syphilis is growing, and clinical presentation can be diverse. Cases of reinfection are less well characterized and may present with more subtle cutaneous findings, as in the present case. We report a case of psoriasiform and annular syphilis. The low frequency of this form of syphilis led us to varied differential diagnoses.

### Funding

No funding was received for the present study.

DOI of original article:

<https://doi.org/10.1016/j.ad.2022.03.007>

\* Corresponding author.

E-mail address: [alejandromartingorgojo@aedv.es](mailto:alejandromartingorgojo@aedv.es)

(A. Martin-Gorgojo).

<https://doi.org/10.1016/j.ad.2022.11.002>

0001-7310/© 2022 AEDV. Published by Elsevier España, S.L.U. This is an open access article under the CC BY-NC-ND license (<http://creativecommons.org/licenses/by-nc-nd/4.0/>).