




ACADEMIA ESPAÑOLA  
DE DERMATOLOGÍA  
Y VENEREOLÓGIA

# ACTAS Dermo-Sifiliográficas

Full English text available at  
[www.actasdermo.org](http://www.actasdermo.org)



## CASE AND RESEARCH LETTER

### [Translated article] Allergic Contact Dermatitis Due to Minoxidil in a Patient With Alopecia Areata

#### Dermatitis alérgica de contacto por minoxidil en paciente con alopecia areata

To the Editor,

Topical 2,6-diamino-4-piperidinopyrimidine 1-oxide (minoxidil) is probably the most widely used treatment for different types of alopecia. Although the topical solution is usually well tolerated, continued application can sometimes result in itching and irritant contact dermatitis.

A 38-year-old man with no personal or family history of interest was referred to our cutaneous immunology unit for evaluation of an eczematous neck rash that had developed over the previous 2 months.

He had been using topical minoxidil (Regaxidil) to treat alopecia areata for the previous 3 months. He mentioned an episode of alopecia areata characterized by multiple patches in childhood (at the age of 6 years) that had been treated with topical minoxidil at an unknown concentration. The treatment led to complete resolution after 6 months, and until now he had not experienced any other episodes.

Physical examination revealed erythematous, edematous papules and patches in the occipital region of the neck (Fig. 1A and B). The patient was patch tested with the European Baseline Series (Chemotechnique Diagnostics), 30% aqueous propylene glycol, and minoxidil 1% and 5% in dimethylsulfoxide (DMSO) (Fig. 1C). The results were



interpreted using the criteria of the International Contact Dermatitis Research Group. Readings were performed on days 2 and 4. The reaction to minoxidil 1% and 5% in DMSO was negative on day 2 (Fig. 1D) and positive (++/+++ ) on day 4 (Fig. 1E). Patch tests with minoxidil 1% and 5% in DMSO were negative in 12 controls.

The patient was diagnosed with allergic contact dermatitis due to minoxidil. The product was discontinued and the lesions disappeared completely within a week. No signs of hair regrowth were observed, despite the inflammatory reaction to contact dermatitis from minoxidil.

Few cases of allergic contact dermatitis due to minoxidil have been reported.<sup>1</sup> Other contact reactions related to the topical application of this product include pustular allergic contact dermatitis,<sup>2</sup> occupational allergic contact dermatitis, and pigmented contact dermatitis.<sup>3</sup> A case of persistent allergic patch test reactions to minoxidil manifesting as cutaneous lymphoid hyperplasia has also been reported.<sup>4</sup>

Choice of vehicle is important for patch testing. Direct testing may generate doubts, as topical minoxidil solution contains propylene glycol. That is why we chose DMSO as a vehicle, as it favors penetration of the active ingredients and is valid for both hydrophilic and lipophilic substances.

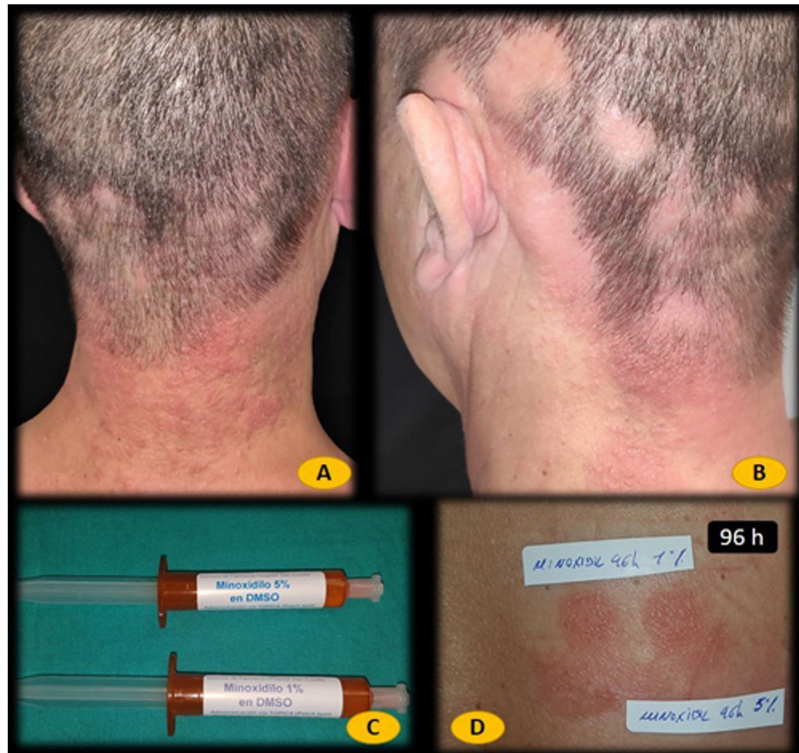The recent introduction of oral minoxidil has revolutionized the treatment of certain forms of alopecia (androgenetic alopecia).<sup>5</sup> Identifying patients sensitized to topical minoxidil could be important, as certain patients with alopecia may require oral minoxidil to control hair loss. Although oral minoxidil can probably be safely used, the possibility of systemic contact dermatitis cannot be fully ruled out, despite early reports suggesting it is unlikely.<sup>6,7</sup>

DOI of original article:

<https://doi.org/10.1016/j.ad.2021.08.009>

<https://doi.org/10.1016/j.ad.2022.10.029>

0001-7310/© 2021 AEDV. Published by Elsevier España, S.L.U. This is an open access article under the CC BY-NC-ND license (<http://creativecommons.org/licenses/by-nc-nd/4.0/>).



**Figure 1** A and B, Eczematous rash on the neck. C, Minoxidil 1% and 5% in dimethyl sulfoxide (DMSO) prepared by the hospital pharmacy. D, Negative patch test to minoxidil 1% and 5% in DMSO on day 2. E, Positive patch test to minoxidil 1% and 5% in DMSO on day 4.

## Conflicts of Interest

The authors declare that they have no conflicts of interest.

## References

1. Ebner H, Müller E. Allergic contact dermatitis from minoxidil. *Contact Dermatitis*. 1995;32:316–7.
2. Rodríguez-Martín M, Sáez-Rodríguez M, Carnerero-Rodríguez A, Cabrera de Paz R, Sidro-Sarto M, Pérez-Robayna N, et al. Pustular allergic contact dermatitis from topical minoxidil 5%. *J Eur Acad Dermatol Venereol*. 2007;21:701–2.
3. Trattner A, David M. Pigmented contact dermatitis from topical minoxidil 5%. *Contact Dermatitis*. 2002;46:246.
4. García-Rodiño S, Espasandín-Arias M, Suárez-Peñaranda JM, Rodríguez-Granados MT, Vázquez-Veiga H, Fernández-Redondo V. Persisting allergic patch test reaction to minoxidil manifested as cutaneous lymphoid hyperplasia. *Contact Dermatitis*. 2015;72:413–6.
5. Beach RA, McDonald KA, Barrett BM. Tolerated, effective, successful: low dose oral minoxidil for treating alopecia, a 3-year North American retrospective case series. *J Am Acad Dermatol*. 2020;S0190-9622:32844-9.
6. Therianou A, Vincenzi C, Tosti A. How safe is prescribing oral minoxidil in patients allergic to topical minoxidil? *J Am Acad Dermatol*. 2020;S0190-9622:30567-3.
7. Tosti A, Bardazzi F, de Padova MP, Caponeri GM, Melino M, Veronesi S. Contact dermatitis to minoxidil. *Contact Dermatitis*. 1985;13:275–6.

F.J. Navarro-Triviño, G.-V.A. Pegalajar-García,  
R. Ruiz-Villaverde\*

*Servicio de Dermatología, Hospital Universitario San Cecilio, Inst Invest Biosanitaria IBS Granada, Granada, Spain*

\*Corresponding author.

E-mail address: [ismenios@hotmail.com](mailto:ismenios@hotmail.com) (R. Ruiz-Villaverde).