

IMAGES IN DERMATOLOGY

Acroangiokeratitis of Mali—An Unusual Cause of Painful Ulcer

Acroangiokeratitis de Mali – una causa inusual de úlcera dolorosa

L. Sun^{a,*}, S. Duarte^a, L. Soares-de-Almeida^{a,b,c}

^a Dermatology Department, Hospital de Santa Maria, Centro Hospitalar Universitário Lisboa Norte EPE, Portugal

^b Dermatology University Clinic, Faculty of Medicine, University of Lisbon, Portugal

^c Dermatology Research Unit, iMM João Lobo Antunes, Portugal

A 58-year-old man presented with a two-month history of painful ulcers on the left leg, developed after minor trauma. Physical examination showed two well-defined ulcers, 1 and 3 cm in diameter, with red-violaceous elevated borders (Fig. 1a). The biopsy of the ulcer revealed an increased number of thick-walled capillaries that were present in a clustered pattern through the entire dermis, with prominent endothelial cells, extravasated erythrocytes and interstitial hemosiderin deposits (Fig. 1b). Human herpesvirus 8 staining was negative. Venous Doppler ultrasound demonstrated incompetence of saphenofemoral junction and popliteal vein of the left lower limb. A final diagnosis of acroangiokeratitis of Mali was made. The patient was treated with local wound care and was referred to a vascular surgeon.

Acroangiokeratitis of Mali, also known as pseudo-Kaposi sarcoma, is a rare chronic inflammatory skin process involving a reactive proliferation of capillaries and fibrosis of the skin induced by chronic tissue hypoxia. The lesions tend to be circumscribed, red-violaceous macules, papules, or

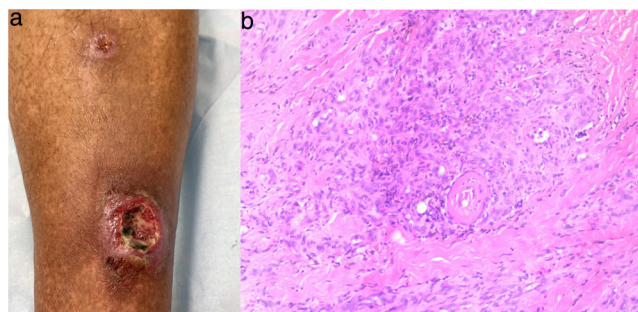


Figure 1

plaques that may develop into painful ulcerations. Most cases have been associated with venous insufficiency and the treatment involves correction of the underlying vascular pathology. Acroangiokeratitis of Mali is an unusual cause of non-healing painful ulcer that dermatologist should take in consideration.

* Corresponding author.

E-mail address: Lanyusun@gmail.com (L. Sun).