

## CASE AND RESEARCH LETTER

[Translated article]

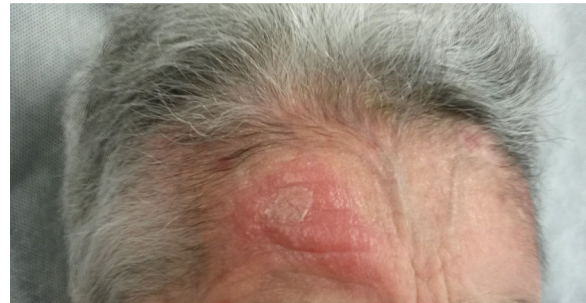### Electrocardiographic Alterations Related to Intralesional Glucantime® Treatments: A Potentially Severe Adverse Event

### Alteraciones electrocardiográficas por Glucantime® intralesional, un evento adverso potencialmente grave

To the Editor,

Meglumine antimoniate (MA) (Glucantime®, Sanofi-Aventis, S.A., Spain) is the treatment of choice in cutaneous leishmaniasis (CL).<sup>1–4</sup> It is administered intramuscularly (IM) and intralesionally (IL), and is considered to be a safe and effective drug. IL administration is used in single lesions smaller than 3–4 cm and IM administration is reserved for multiple lesions, complicated lesions, or cases with signs of lymphatic dissemination.<sup>1,3,4</sup> The recommended IM dosage is between 10 and 20 mg/kg/d of antimony (75 mg/kg/d of MA) in 10-day cycles.<sup>3,5–7</sup> For IL administration, much lower doses of between 0.2 and 1 mL/lesion are used, in variable dosage regimens, every 0.5–1–2 weeks.<sup>1,3,8</sup> It is well known that systemic use of the drug may cause electrocardiographic abnormalities.<sup>3</sup>

An 82-year-old woman visited our department with an erythematous–edematous infiltrated lesion measuring 3.5 cm, with no ulceration or scab, located on the forehead; the lesion was persistent and had appeared some months earlier (Fig. 1). The patient had a past history of rheumatoid arthritis treated with etanercept and prednisone, osteoporosis, scoliosis, mild anemia, seborrheic dermatitis treated with topical corticosteroids, and severe underweight (BMI, 15 kg/m<sup>2</sup>). A skin biopsy of the lesion revealed granulomatous dermatitis with amastigotes and a diagnosis of leishmaniasis was therefore established. The patient had not traveled outside Spain. It was decided to treat the patient with oral itraconazole for 6 weeks, with



**Figure 1** Erythematous–edematous infiltrated plaque measuring 3.5 cm, located on the forehead, corresponding to a lesion due to *Leishmania*.

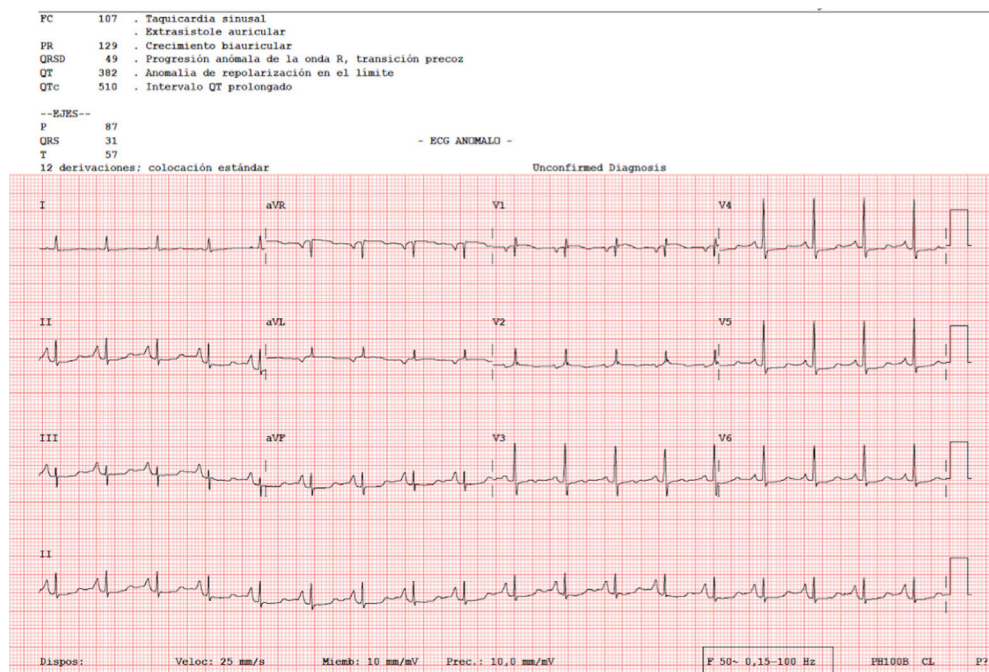
good clinical and analytical tolerance but without improvement. A week later, intralesional MA was administered at a dose of 0.6–1 mL on days 0, 7, and 21, following administration of lidocaine/prilocaine. The topical corticosteroids and etanercept were withdrawn from the moment of diagnosis. An electrocardiogram (ECG) performed after the 3rd dose detected a prolonged QT interval (QTc, 510 ms), non-significant ST segment depression, and increased P wave axis (Fig. 2), and treatment was therefore suspended. The patient reported no episodes of syncope. A follow-up ECG, performed by the cardiology department 3 weeks later, was within the normal range. The cutaneous signs and symptoms resolved with the 3 doses that had already been administered.

Multiple adverse effects of systemic MA have been reported, including myalgia, arthralgia, gastrointestinal disorders (nausea, abdominal pain), headache, elevated hepatic and pancreatic enzymes, leukopenia, abnormal ECG, and severe arrhythmia.<sup>3,5</sup> Because it involves lower and more widely spaced doses, intralesional use of MA produces mild and generally local adverse effects (pain, edema, pruritus, and transitory erythema at the injection site).<sup>2,4,5,7–10</sup> Systemic adverse effects associated with this route of administration have also been described, such as nausea, vomiting, dyspnea, dizziness, rash, myalgia, arthralgia, headache, and even anaphylactic shock.<sup>10</sup> Cardiotoxicity due to systemic antimonials is a well-known adverse effect that, according to the product information sheet, may present when used at high daily doses over long periods of time. It may produce a prolonged QT interval in

DOI of original article:  
<https://doi.org/10.1016/j.ad.2021.04.012>

<https://doi.org/10.1016/j.ad.2022.06.011>

0001-7310/© 2022 Published by Elsevier España, S.L.U. on behalf of AEDV. This is an open access article under the CC BY-NC-ND license (<http://creativecommons.org/licenses/by-nc-nd/4.0/>).



**Figure 2** Electrocardiogram (ECG) showing a prolonged QT interval (QTc, 510 ms), nonsignificant ST segment depression, and increased P wave axis.

the ECG, with potential development of severe arrhythmia, which may result in death. Changes in the ECG are generally dose-dependent and are usually reversible. In most cases, abnormalities such as T wave inversion and prolonged QT interval precede onset and are a warning sign of potential severe arrhythmia. A baseline ECG should be performed with a follow-up ECG every 7–10 days, and treatment should be suspended if the QTc interval exceeds 450 ms.<sup>5,6,9</sup> Ribeiro et al. also demonstrated changes in the ECG (prolonged QT) with systemic IM therapy at low doses (10 mg/kg) and in short treatment durations (10 days) with potential severe implications, which make monitoring these patients using ECG recommendable.<sup>6</sup> With regard to intralesional therapy, a recent clinical study in Brazil in 53 patients who underwent a weekly ECG found a prolonged QT interval with no clinical repercussions in 25% of cases.<sup>10</sup> This effect was found to be associated with smoking.<sup>10</sup> It is, however, a poorly documented adverse effect, as ECGs are not usually performed in the clinical follow-up of intralesional therapy. In that study, the weekly doses used were much higher than those in our study. The fact that we detected this abnormality in a patient with no cardiologic risk criteria in treatment with low-dose intralesional MA leads us to believe that it is also useful to monitor the ECG in these patients.

In conclusion, before instating therapy with antimonials in any form, the patient should be questioned regarding personal history of cardiac disease (heart attack, bradycardia, palpitations, syncope, etc.) and a family history of sudden death. Factors that may favor prolonged QT, such as electrolyte imbalance, should be monitored and corrected and association with other drugs that may also cause prolonged QT ([www.qtdrugs.org](http://www.qtdrugs.org)) (antiarrhythmics, tricyclic antidepressants, erythromycin, tetracyclines, trimethoprim/sulfamethoxazole, antipsychotics, etc.) should be

avoided.<sup>6</sup> We recommend monitoring high-risk patients and watching for the appearance of a prolonged QT interval.

## Conflicts of Interest

The authors declare that they have no conflicts of interest.

## References

1. Aguado M, Espinosa P, Romero-Maté A, Tardío JC, Córdoba S, Borbujo J. Outbreak of cutaneous leishmaniasis in Fuenlabrada, Madrid. *Actas Dermosifiliogr.* 2013;104:334–42.
2. Brito NC, Rabello A, Cota GF. Efficacy of pentavalent antimoniate intralesional infiltration therapy for cutaneous leishmaniasis: a systematic review. *PLOS ONE.* 2017;12:e0184777.
3. García-Almagro D. Leishmaniasis cutánea. *Actas Dermosifiliogr.* 2005;96:1–24.
4. Giavedoni P, Iranzo P, Fuertes I, Estrach T, Alsina Gibert M. Cutaneous leishmaniasis: 20 years' experience in a Spanish tertiary care hospital. *Actas Dermosifiliogr.* 2015;106:310–6.
5. Oliveira LF, Schubach AO, Martins MM, Passos SL, Oliveira RV, Marchi MC, et al. Systematic review of the adverse effects of cutaneous leishmaniasis treatment in the New World. *Acta Trop.* 2011;118:87–96.
6. Ribeiro AL, Drummond JB, Volpini AC, Andrade AC, Passos VM. Electrocardiographic changes during low-dose, short-term therapy of cutaneous leishmaniasis with the pentavalent antimonial meglumine. *Braz J Med Biol Res.* 1999;32:297–301.
7. da Silva RE, Toledo Júnior A, Senna MC, Rabello A, Cota G. Intralesional meglumine antimoniate for the treatment of localised cutaneous leishmaniasis: a retrospective review of a Brazilian referral centre. *Mem Inst Oswaldo Cruz.* 2016;111:512–6.
8. Uzun S, Durdu M, Culha G, Allahverdiyev AM, Memisoglu HR. Clinical features, epidemiology, and efficacy and safety of

intralesional antimony treatment of cutaneous leishmaniasis: recent experience in Turkey. *J Parasitol.* 2004;90:853–9.

9. Esfandiarpour I, Farajzadeh S, Rahnama Z, Fathabadi EA, Heshmatkhah A. Adverse effects of intralesional meglumine antimoniate and its influence on clinical laboratory parameters in the treatment of cutaneous leishmaniasis: adverse effects of intralesional meglumine antimoniate in cutaneous leishmaniasis. *Int J Dermatol.* 2012;51:1221–5.
10. Fernandes HJ, da Silva RE, Ramalho DB, Aguiar MG, Silveira JN, Cota G. Safety profile of meglumine antimoniate intralesional infiltration for cutaneous leishmaniasis. *Expert Rev Anti Infect Ther.* 2020;18:381–7.

B. García Bracamonte\*, S. Burillo Martínez,  
C. Morales Raya, P. Ortiz Romero

*Hospital Universitario 12 de Octubre, Madrid, Spain*

\* Corresponding author.

*E-mail address:* [beagarcia50@hotmail.com](mailto:beagarcia50@hotmail.com)

(B. García Bracamonte).