

PRACTICAL DERMOSCOPY

[Translated article] Hair Casts: Trichoscopic Clues[☆]



Vainas peripilares: claves tricoscópicas

A 51-year-old Colombian woman visited our department with predominantly frontal and bitemporal capillary hypodensity that had begun 10 years earlier (Figs. 1 and 2).

Trichoscopy revealed miniaturization of the follicles, a fine pigmented reticulum, and hair casts (Fig. 3).

What is your Diagnosis?

Traction alopecia

Traction alopecia (TA) is caused by the direct mechanical damage done by hairstyles involving considerable traction¹. It is more frequent in women and has been reported in up to a third of African-American women, although it can affect all phenotypes². It is associated with the use of pony tails, plaits, extensions, chemical hair-shaft relaxers, turbans, and headbands^{3,4}. The condition is a reversible alopecia in

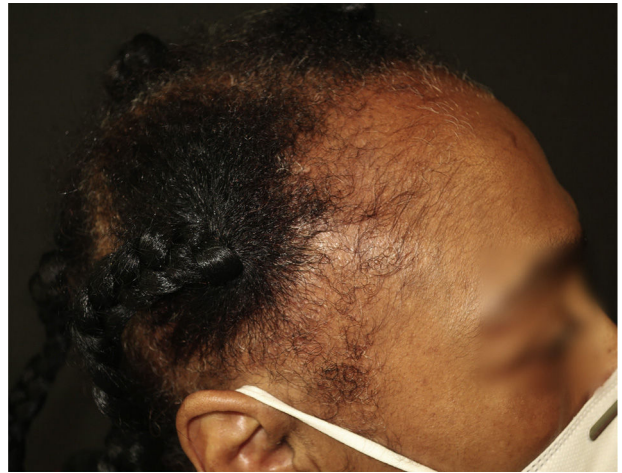

Figure 2 Temporal capillary hypodensity associated with a high-traction hairstyle.

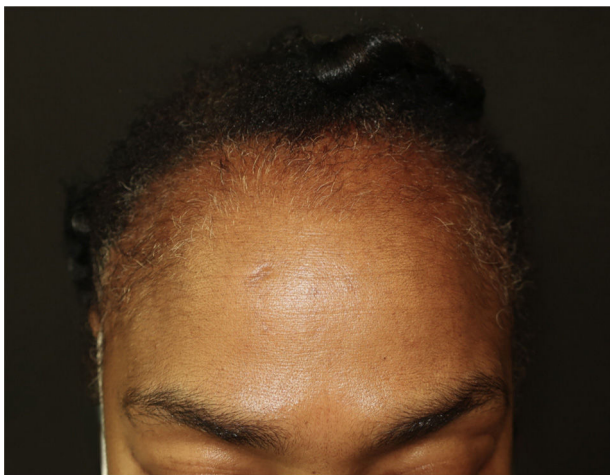

Figure 1 Frontal capillary hypodensity.

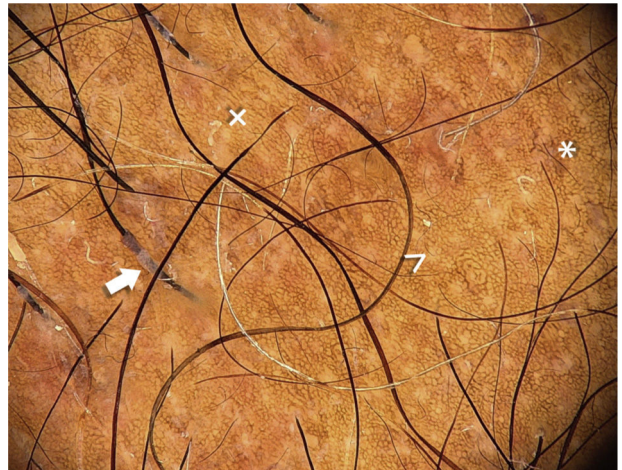


Figure 3 Hair casts in the region proximal to the shaft (arrow). Multiple empty follicular orifices (>) and fine hairs (*). Some dystrophic hairs (x). A fine pigmented reticulum can be observed on the interfollicular skin; this sign is present in dark phototypes.

DOI of original article:

<https://doi.org/10.1016/j.ad.2020.11.027>

[☆] Please cite this article as: Giacaman A, del Pozo Hernando LJ, Martín-Santiago A. Vainas peripilares: claves tricoscópicas. *Actas Dermosifiliogr.* 2022;113:176–177.

<https://doi.org/10.1016/j.ad.2022.01.016>

0001-7310/© 2022 Published by Elsevier España, S.L.U. on behalf of AEDV. This is an open access article under the CC BY-NC-ND license (<http://creativecommons.org/licenses/by-nc-nd/4.0/>).

the initial stages but progresses to permanent alopecia if the triggering factors are not corrected². Physical examination reveals the band sign that corresponds to an area immedi-

ately anterior to the area of alopecia, with shorter terminal hairs. The eyebrows, eyelashes, nails, and body hair are not involved.

In the initial stages of TA, trichoscopy reveals miniaturization of the follicles and hair casts (HCs). Papules and/or pustules may also be observed, together with perifollicular erythema, black spots and the recently described flame or torch sign, which is more frequent in more pigmented phototypes, corresponding to white areas at the base of the terminal hairs.⁵ In advanced stages, signs of cicatricial alopecia are observed^{2,5}.

The HCs tend to be found on the periphery of the alopecia plaque. They are present in more than 80% of cases of TA and correspond to grayish-white mobile cylindrical structures, located in the region proximal to the hair shaft, coinciding with the areas of maximum tension. Their presence indicates permanent traction, and they may, therefore, help to monitor cessation of this factor by the patient. HCs are not a specific sign. They can also be observed in seborrheic dermatitis and psoriasis of the scalp, and it is important to distinguish them from nits in order to avoid unnecessary treatments⁶.

The differential diagnosis of TA includes other entities that may mimic or even coexist the condition, such as fibrosing frontal alopecia, androgenetic alopecia, alopecia areata, and trichotillomania, which do not present HCs^{1,2}. Biopsy should only be performed if the diagnosis is in doubt⁵.

Treatment is based on avoiding traction. Topical or intralesional corticosteroids, antibiotics, and minoxidil may

be used in the initial stages. In advanced stages, camouflaging techniques and hair transplant may be considered^{1–6}.

References

1. Tosti A, Miteva M, Torres F, Vincenzi C, Romanelli P. Hair casts are a dermoscopic clue for the diagnosis of traction alopecia. *Br J Dermatol*. 2010;163:1353–5.
2. Billero V, Miteva M. Traction alopecia: The root of the problem. *Clin Cosmet Investig Dermatol*. 2018;11:149–59.
3. Munoz Moreno-Arrones O, Vano-Galvan S. Bitemporal hair loss related to traction alopecia. *Dermatol Online J*. 2016;22, 13030/qt2nd0n0rm.
4. Ézsöl-Lendvai Z, Iñiguez-de Onzoño L, Pérez-García L. Alopecic plaques in a cook. Placas alopécicas en una cocinera. *Actas Dermosifiliogr*. 2016;107:339–40.
5. Agrawal S, Daruwalla SB, Dhurat RS. The flambeau sign — A new dermoscopy finding in a case of marginal traction alopecia. *Australas J Dermatol*. 2020;61:49–50.
6. Campos-Munoz L, Fueyo-Casado A, Carranza-Romero C, Gonzalez-Guerra E, Lopez-Bran E. Peripilar hair casts. *J Am Acad Dermatol*. 2017;76:53–4.

A. Giacaman*, L.J. del Pozo Hernando, A. Martín-Santiago
Departamento de Dermatología, Hospital Universitari Son Espases, Palma de Mallorca, Spain

*Corresponding author.

E-mail address: anizagiacaman@gmail.com (A. Giacaman).