



ACTAS Derma-Sifiliográficas

Full English text available at
www.actasdermo.org



CARTAS CIENTÍFICO-CLÍNICAS

Neutrophilic figurate erythema of infancy associated with juvenile myelomonocytic leukemia



Eritema figurado neutrofílico de la infancia asociado a Leucemia Mielomonocítica Juvenil

A 2-year-old girl presented with a 3-month history of asymptomatic annular erythematous skin eruptions. Each plaque began as a small erythematous papule that enlarged, acquiring an annular configuration with central clearing. During this time some lesions spontaneously disappeared, leaving hyperpigmentation. The patient did not present constitutional symptoms. At the age of 1, she had been diagnosed with Disseminated Juvenile Xanthogranuloma, without neurologic, ophthalmologic or other visceral involvement. She was otherwise healthy, had neither allergies nor a significant family history. There was no history of insect bites or exposure to animals and she had not received any medications previous to the eruption.

Physical examination revealed multiple annular and polycyclic erythematous plaques, with indurated borders and petechiae on the rims. The plaques were devoid of vesicles, crusts, erosions or desquamation (Fig. 1) and were distributed on her upper chest, abdomen and upper back. There was no hepatosplenomegaly, lymphadenopathy, or arthritis.

Laboratory studies disclosed a normal white cell count with normal differential. Immunoglobulin G titers were slightly elevated; IgM, IgA, IgE, antistreptolysin O titers; serum levels of C3 and C4 were normal. Anti-SS-A (Ro) and anti-SS-B (La) antibodies were negative. A stool examination for parasites and serologic tests for *Toxocara*, *Bartonella henselae*, Epstein–Barr virus and hepatitis B virus infection were negative.

Histological examination of an annular plaque revealed superficial and deep perivascular and interstitial mixed-cell dermatitis. The deep dermal infiltrate was composed predominantly of neutrophils with abundant nuclear dust. Other vasculitis signs were absent (Fig. 2). Clinical and histopathological features were consistent with Neutrophilic Figurate Erythema of Infancy (NFEI).

Two months after the consultation, the patient presented clinical and laboratory findings suggestive of mononucleosis syndrome due to Epstein–Barr virus. During the infection, the lesions increased in size and number. No improvement was seen during febrile periods.

Ten months after the beginning of plaques, a complete blood count was performed, which showed leukocytosis: 28,600 WBC/mm³ with 22% monocytes and blast cells. A myelogram showed hypercellularity and 12% blast cells with monocyte-like appearance. The immunophenotype showed 17% immature monocytoid cells. Her fetal hemoglobin concentration was 24%. The translocation study (t9:22, t8:1 and t15:17) was negative. Therefore, juvenile myelomonocytic leukemia (JMML) was diagnosed. She began oral chemotherapy with hydroxyurea, observing an important improvement in the cutaneous lesions.

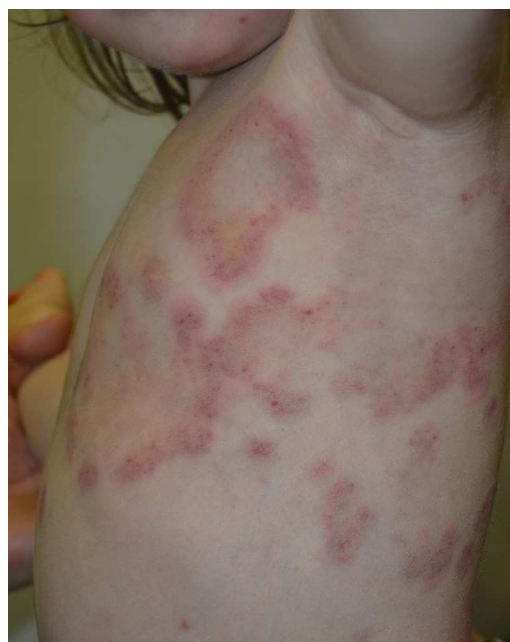

Figure 1 Multiple annular and polycyclic erythematous plaques with purpuric macules and indurated borders devoid of crusts, vesicles or desquamation distributed along her left chest and axillae.

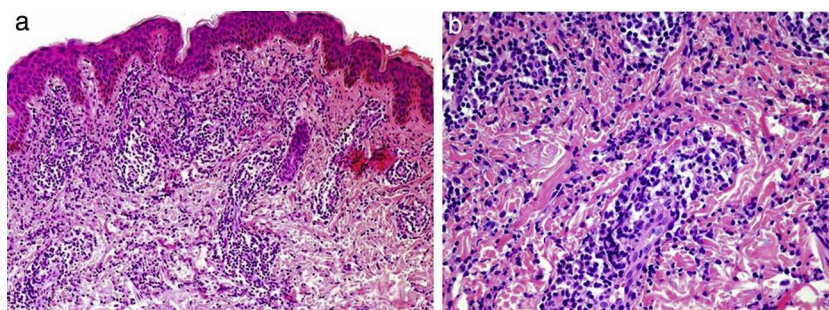


Figure 2 Histological examination of a biopsy specimen taken from an indurated border of one plaque, hematoxylin–eosin stain (a) superficial and deep perivascular and interstitial infiltrate, without epidermal changes (Hematoxilina-Eosina 80X). (b) The deep dermal infiltrate was composed predominantly of neutrophils, with abundant nuclear dust, without other signs of vasculitis (Hematoxilina-Eosina 100X).

Discussion

Annular or figurate erythemas of infancy (AEI) are characterized by a primary annular, circinate, arcuate or polycyclic pattern of cutaneous lesions.^{1,2} The lesions may be due to a known cause (rheumatic margined erythema, neonatal lupus, erythema chronicum migrans) or may be idiopathic³ and may present with a localized or broad distribution.^{2,3}

NFEI belongs to those figurate erythemas of unknown etiology.³ It is characterized by papular erythematous eruptions with rapid centrifugal enlargement to annular or polycyclic asymptomatic plaques with indurated borders devoid of vesicles, crusts or desquamation.^{4,5} Frequently, the eruptions begin on the face and then spread centrifugally to the limbs. The patches tend to disappear within 2–4 weeks, but the disease course is chronic.^{1,3}

Histologically, NFEI is characterized by a superficial and deep, perivascular and interstitial infiltrate of neutrophils associated with leukocytoclasia but without other signs of vasculitis.^{1,2,4,5}

Differential diagnosis of NFEI includes annular erythemas of infancy and dermatoses with a prominent neutrophilic infiltrate such as Sweet syndrome (SS) and pyoderma gangrenosum, urticarial lesions of dermatitis herpetiformis or linear IgA dermatosis, early lesions of bullous lupus erythematosus, Still disease, Sjögren's syndrome and early leukocytoclastic vasculitis.²

Sweet syndrome (SS) was very important in our differential diagnosis, considering the association with JMML presented in this case. However, our patient lacked typical manifestations of SS, as the lesions were asymptomatic and neither fever nor neutrophilia were present.² Furthermore, paraneoplastic SS in children usually presents mucosal involvement, anemia and thrombocytopenia, and the neoplasm is concomitant with skin eruptions.^{7,8} Finally, SS histological findings differ from NFEI, as SS is characterized by a dense nodular or diffuse dermal infiltrate of neutrophils with nuclear dust with a variable amount of lymphocytes, histocytes, extravasated erythrocytes and a Grenz zone,^{2,7,8} findings not found in NFEI descriptions or in this patient.

Some authors have described cases of recurrent annular neutrophilic dermatosis in adulthood⁹ and have included this condition in the spectrum of neutrophilic dermatoses.

Although NFEI has been considered a benign chronic condition, only three pediatric cases have been reported.^{2,4,6} The association with a hematological neoplasm and its response to its treatment in our patient suggest that NFEI may be among the group of neutrophilic dermatoses. Cytokines and other biochemical mediators produced by blast cells could be involved in the development or maintenance of the skin lesions.

A standard treatment for NFEI has not been established. Previous reported treatments include topical steroids, systemic corticosteroids, hydroxychloroquine and colchicine, with poor responses.^{1,5}

We present the first case of NFEI associated with JMML. Histological findings and the association with a hematological neoplasm suggest that NFEI may be in the spectrum of neutrophilic dermatoses. Therefore, after a diagnosis of NFEI an exhaustive study to exclude inflammatory diseases and neoplasms is warranted.

References

- Ríos-Martín JJ, Ferrándiz-Pulido L, Moreno-Ramírez D. Approaches to the dermatopathologic diagnosis of figurate lesions. *Acta Dermosifiliogr.* 2011;102:316–24.
- Annessi G, Signoretti S, Angelo C, Paradisi M, Puddu P. Neutrophilic figurate erythema of infancy. *Am J Dermatopathol.* 1997;19:403–6.
- Toledo-Alberola F, Betloch-Mas I. Annular erythema of infancy. *Acta Dermosifiliogr.* 2010;101:473–84.
- Patrizi A, Savoia F, Varotti E, Gaspari V, Gaspari V, Passarini B, et al. Neutrophilic figurate erythema of infancy. *Pediatr Dermatol.* 2008;25:255–60.
- Ozdemir M, Engin B, Toy H, Demirkesen C. Neutrophilic figurate erythema. *Int J Dermatol.* 2008;47:262–4.
- Cox NH, McQueen A, Evans TJ, et al. An annular erythema of infancy. *Arch Dermatol.* 1987;123:510–3.
- Uihlein LC, Brandling-Bennett HA, Lio PA, Liang MG. Sweet syndrome in children. *Pediatr Dermatol.* 2012;29:38–44.
- Hospach T, von den Driesch P, Dannecker GE. Acute febrile neutrophilic dermatosis (Sweet's syndrome) in childhood and adolescence: two new patients and review of the literature on associated diseases. *Eur J Pediatr.* 2009;168:1–9.
- Cabanillas M, Suárez-Amor O, Sánchez-Aguilar D, Pereiro MM, Toribio J. Chronic recurrent neutrophilic dermatosis: a possible variant in the spectrum of neutrophilic dermatoses. *Acta Dermosifiliogr.* 2008;99:61–3.

C. del Puerto Troncoso^{a,*}, M. Curi Tuma^b,
S. González Bombardiere^c, S. Silva-Valenzuela^a

^a Department of Dermatology, Faculty of Medicine,
Pontificia Universidad Católica de Chile, Chile

^b Chilean Safety Association [Asociación Chilena de
Seguridad], Santiago, Chile

^c Department of Pathology, Faculty of Medicine, Pontificia
Universidad Católica de Chile, Chile

* Corresponding author.

E-mail addresses: mcdelpue@uc.cl,
conildelpuerto@gmail.com (C. del Puerto Troncoso).

<http://dx.doi.org/10.1016/j.ad.2014.09.013>

Osificación bilateral del cartílago auricular



Bilateral Ossification of the Auricular Cartilage

Presentamos un varón de 45 años, ingresado por hiponatremia de etiología indeterminada, que nos fue remitido por parte de medicina interna para valoración al observar que presentaba induración de los pabellones auriculares. A la exploración se observaron unas orejas de aspecto normal, sin afectación cutánea visible, y a la palpación se hizo evidente la rigidez de la porción auricular cartilaginosa de las mismas, con afectación bilateral y difusa, respetando los lóbulos (fig. 1 A). El paciente manifestó la instauración progresiva y asintomática de estos

cambios en los últimos 2 años. En la ecografía cutánea se observó una zona hipocogénica correspondiente al cartílago auricular normal y sobre esta, una imagen en banda hiperecogénica sugestiva de transformación del cartílago por mineralización (fig. 1 B). En la radiografía de cráneo se observó un aumento de la densidad de los pabellones auriculares de forma difusa y homogénea, con densidad comparable a la del hueso (fig. 1 C). El estudio histopatológico de la piel y del cartílago auricular demostró una epidermis y una dermis sin alteraciones significativas y fragmentos de cartílago elástico con focos de osificación, con formación de trabéculas óseas maduras (fig. 2 A y B).

En la analítica se encontraron cifras de cortisol basal casi indetectables $<0,4 \mu\text{g/dl}$ (4,3-22,4), con un nivel de ACTH en el rango bajo de la normalidad: $9,5 \text{ pg/ml}$

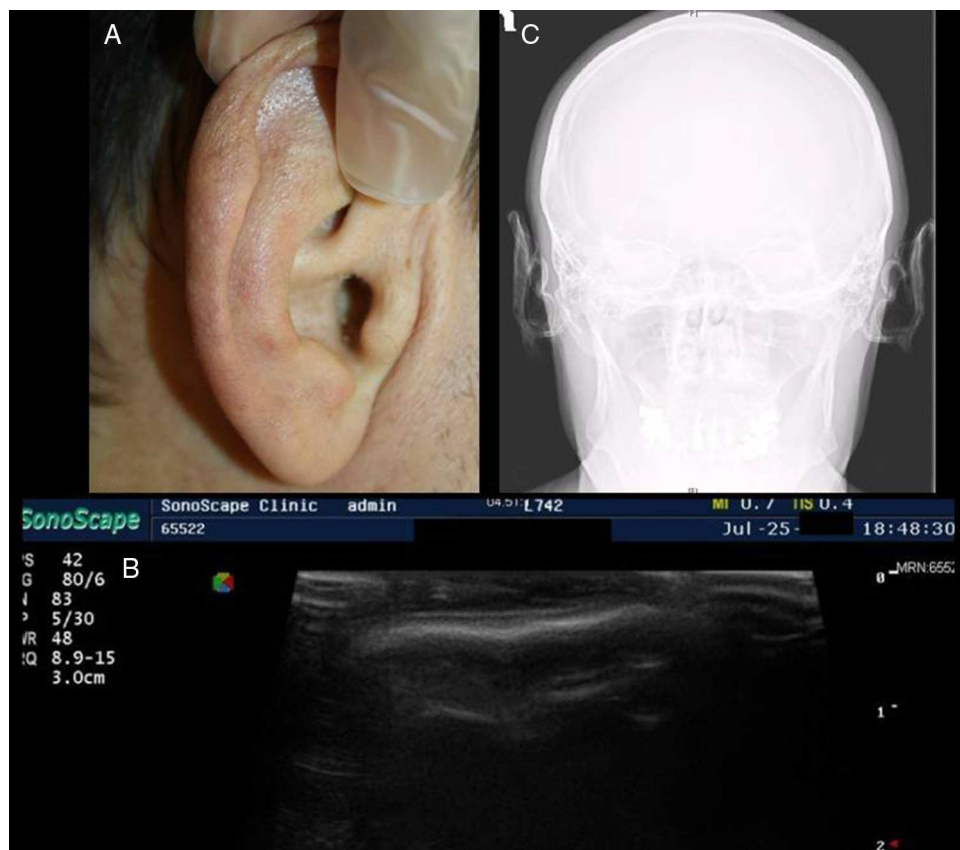


Figura 1 A. Orejas de aspecto aparentemente normal, de consistencia rígida a la palpación. B. Ecografía cutánea con una imagen hiperecogénica en banda sobre el cartílago auricular normalmente hipocogénico. C. Radiografía de cráneo con aumento de densidad tipo hueso de los pabellones auriculares.