

## CASE AND RESEARCH LETTERS

### Granulomatous Dactylitis: An Unusual Finding in Sarcoidosis<sup>☆</sup>



### Dactilitis granulomatosa como manifestación inusual de la sarcoidosis

To the Editor:

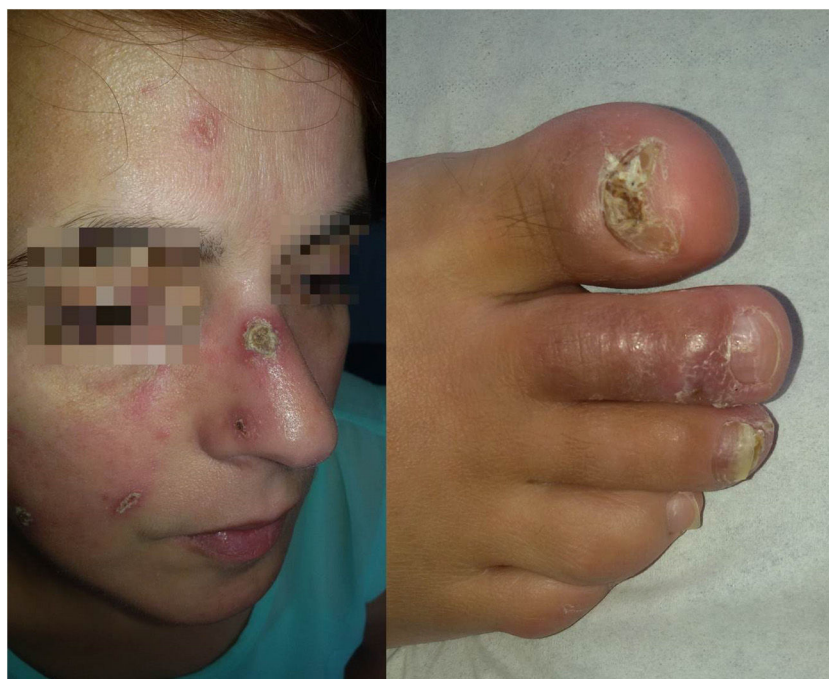Sarcoid dactylitis is a rare manifestation, observed in 0.2% of cases of sarcoidosis. It usually courses with swelling of the fingers or toes, mainly affecting the middle phalanges and, less often, the distal phalanges.<sup>1</sup>

A 38-year-old woman visited our department with inflammation and pain in the toes of the right foot, accompanied by abnormal nails, which had appeared 3 months earlier. The patient presented erythematous, lupoid facial lesions that

had appeared a year earlier and were associated with bilateral enlarged cervical lymph nodes. Examination revealed erythema with edema and swelling in the first 3 toes of the right foot, associated with dystrophic toenails, and erythematous lesions with adhered crusts on the nose, forehead, and cheeks (Fig. 1).

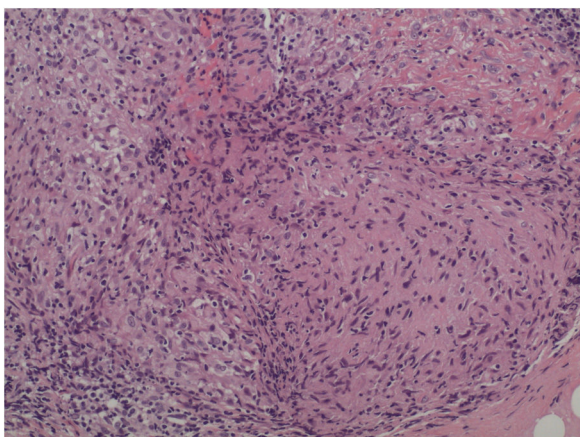
The biopsy of the cervical lymph nodes revealed a sarcoid granulomatous lymphadenitis, with negative staining for Ziehl-Neelsen, Grocott, and PAS. Blood cultures and urine tests were negative for aerobes, anaerobes, and *Mycobacterium* species were negative. The histologic study of the skin lesions on the face and right foot revealed the existence of naked granulomas, with no central necrosis or lymphocytic corona, in the deep and middle dermis (Fig. 2).

Blood tests showed increased levels of angiotensin-converting enzyme and acute phase reactants, and serology for syphilis was negative.



**Figure 1** Erythematous lupus pernio lesions on the face with crusts on the surface. Dactylitis in 3 toes of the right foot associated with nail disease.

<sup>☆</sup> Please cite this article as: García Morales I, Sánchez García E, Crespo Cruz A, Escudero J. Dactilitis granulomatosa como manifestación inusual de la sarcoidosis. *Actas Dermosifiliogr.* 2021;112:851–853.



**Figure 2** Histologic study of the facial skin lesions with granulomas in the middle and deep dermis, with no central necrosis or lymphocytic corona.

The x-ray study revealed destruction of the distal phalanx of the first toe, with signs of bone resorption and tendinitis.

The CT scan showed a small number of enlarged hilar, subcarinal mediastinal, and retroperitoneal lymph nodes associated with bilateral micronodules in the upper third of the lung fields.

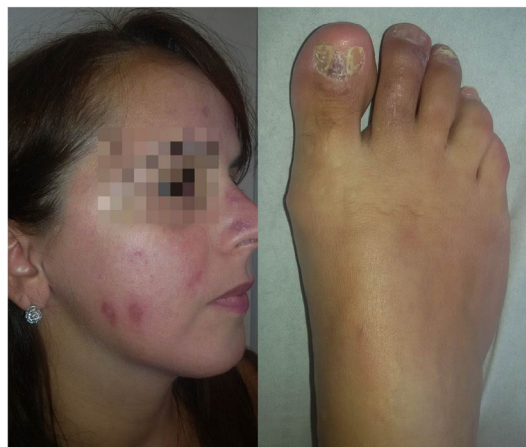A diagnosis of sarcoid dactylitis in the context of systemic sarcoidosis was made and treatment was initiated with oral corticosteroids associated with hydroxychloroquine; a slight improvement was achieved and this treatment was therefore suspended. Treatment was begun with 150 mg/d of azathioprine. After 6 months of treatment, the swelling of the toes had been reduced and the crusts of the facial lesions had disappeared (Fig. 3). After a year of treatment only the erythematous lesions persist, with no crust or swelling.

Bone involvement in sarcoidosis usually manifests in the form of joint pain, whereas deforming arthritis is rare.<sup>2</sup> Two patterns of appearance of sarcoid joint disease exist: an early form of presentation that occurs in the first 6 months and is usually observed in Löfgren syndrome, and a late-onset form that affects multiple joints, generally those of the small bones of the hands and feet and which appears after 6 months.<sup>3</sup> They are often associated with nail disorders, acropachy with racket nails, or acrosclerosis.

Radiologically, sarcoid dactylitis is characterized by trabecular abnormalities with a honeycomb or barred pattern, which may be associated with cystic formations and a periosteal reaction.<sup>4</sup>

Histologically, in bone lesions, noncaseating granulomas are found that invade the phalanges and the surrounding soft tissue. This granulomatous dactylitis is associated with a worse outcome and greater risk of systemic involvement and of lupus pernio in chronic sarcoidosis.<sup>5</sup>

Lupus pernio is one of the most characteristic lesions of sarcoidosis, which is more frequent in Caucasian women with long-term disease, as in our case.<sup>1</sup> It is characterized by pink or violaceous papular lesions on the nose, cheeks, ears, lips, or scalp. It tends to be associated with chronic sarcoidosis and involvement of the upper respiratory apparatus. If the lupus pernio lesions are located on the fingers or toes, cystic bone lesions on the phalanges of the affected members are often observed.<sup>6</sup>



**Figure 3** Favorable clinical course after 3 months of systemic treatment with prednisone associated with hydroxychloroquine.

Bone involvement tends to be associated with a four-fold higher mortality; however, patients do not usually have symptoms, despite the presence of abnormal radiologic findings.<sup>2</sup>

Treatment of sarcoid dactylitis requires the use of high-dose corticosteroids associated with antimalarial drugs and methotrexate. In our patient, we ruled out the use of methotrexate owing to the patient's stated desire to have children and we therefore used azathioprine for some time, and we even considered the use of adalimumab, but this was refused by the patient. The use of anti-TNF- $\alpha$  agents, infliximab, or adalimumab is considered third-line treatment in sarcoidosis, and is useful in refractory cases or cases with ocular or systemic involvement.<sup>7</sup>

## Conflicts of Interest

The authors declare that they have no conflicts of interest.

## References

1. Mori T, Yamamoto T. Dactylitis in sarcoidosis. *J Dermatol*. 2017;44:e340-1.
2. Yayoi N, Naoya I, Osamu I. Lupus pernio with multiples bone cysts in the fingers. *J Dermatol*. 2010;37:812-4.
3. Barnard J, Newman LS. Sarcoidosis: immunology, rheumatic involvement, and therapeutics. *Curr Opin Rheumatol*. 2001;13:84-91.
4. Alaya Z, Mzabi A. [Lytic lesion involving the first phalanx: sarcoidosis should be suspected]. *Pan Afr Med J*. 2017;26:210.
5. Pitt P, Hamilton EB, Innes EH, Morley KD, Monk BE, Hughes GR. Sarcoid dactylitis. *Ann Rheum Dis*. 1983;42:634-9.
6. Zisman DA, Shorr AF, Lynch JP. Sarcoidosis involving the musculoskeletal system. *Semin Respir Crit Care Med*. 2002;23:555-70.
7. Crommelin HA, Van der Burg LM, Vorselaars AD. Efficacy of adalimumab in sarcoidosis patients who developed intolerance to infliximab. *Respir Med*. 2016;115:72-7.

I. García Morales,<sup>a,\*</sup> E. Sánchez García,<sup>b</sup> A. Crespo Cruz,<sup>c</sup> J. Escudero<sup>c</sup>

<sup>a</sup> Unidad de Gestión Clínica de Dermatología, Hospital Universitario Virgen Macarena, Sevilla, Spain

<sup>b</sup> Servicio de Medicina Interna, Hospital Universitario Nuestra Señora de Valme, Sevilla, Spain

<sup>c</sup> Unidad de Gestión Clínica de Dermatología, Hospital Universitario Nuestra Señora de Valme, Sevilla, Spain

\* Corresponding author.

E-mail address: [irenegmorales@gmail.com](mailto:irenegmorales@gmail.com)

(I. García Morales).

1578-2190/ © 2021 Published by Elsevier España, S.L.U. on behalf of AEDV. This is an open access article under the CC BY-NC-ND license (<http://creativecommons.org/licenses/by-nc-nd/4.0/>).

## Pityriasis Rosea-like Eruption Induced by Imatinib in a Patient With a Gastrointestinal Stromal Tumor<sup>☆</sup>



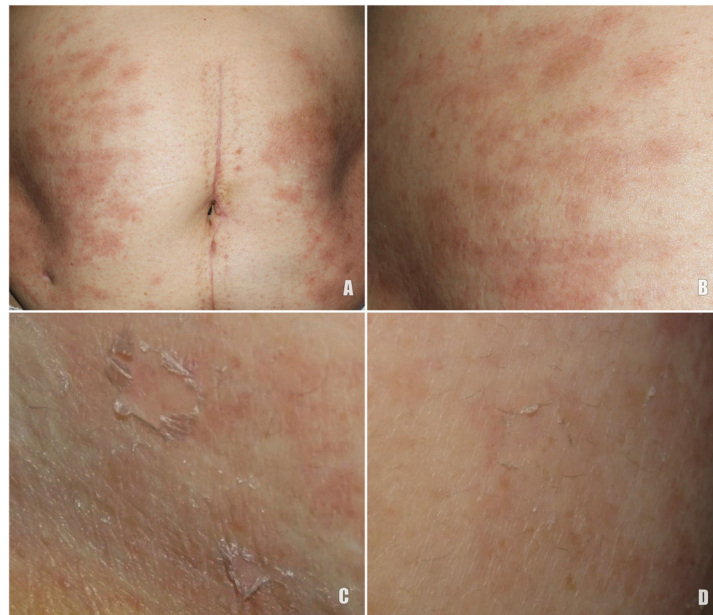### Erupción pitiriasis rosada-like inducida por imatinib en paciente con tumor del estroma gastrointestinal

To the Editor,

Imatinib is a tyrosine kinase inhibitor used to treat chronic myeloid leukemia (CML), gastrointestinal stromal tumors (GISTs), and metastatic dermatofibrosarcoma protuberans.<sup>1-5</sup> It works by competitively inhibiting the adenosine triphosphate binding site, preventing phosphorylation of the proteins BCR-ABL and c-kit and platelet-derived growth factor receptor (PDGFR).<sup>1,5-8</sup>

A 78-year-old woman with a metastatic GIST under treatment with imatinib 400 mg/d for a month and a half presented with a slightly pruritic abdominal skin rash of 1 week's duration. Physical examination showed oval pink macules with collarette scaling symmetrically distributed on both flanks (Fig. 1). The laboratory work-up was normal, including negative serology for treponema. Histology showed spongiotic dermatitis with a predominantly lymphocytic perivascular infiltrate with occasional eosinophils and focal parakeratosis; these findings were consistent with pityriasis rosea (Fig. 2). Considering the histologic findings and recent history of imatinib initiation, the patient was diagnosed with pityriasis rosea-like drug eruption induced by imatinib.

Imatinib was discontinued and treatment started with topical betamethasone and oral loratadine 20 mg every 12 hours. The lesions resolved completely within 2 weeks. Considering the favorable outcome, the patient was restarted on imatinib at a dosage of 100 mg every 12 hours,



**Figure 1** A, Multiple oval pink macules with collarette scaling, symmetrically distributed on both flanks. B, Detail of lesions on right flanks. C and D, Detail of collarette scaling observed in several lesions.

<sup>☆</sup> Please cite this article as: Valenzuela-Ubiña S, Villegas-Romero I, Jiménez-Gallo D, Linares-Barrios M. Erupción pitiriasis rosada-like inducida por imatinib en paciente con tumor del estroma gastrointestinal. Actas Dermosifiliogr. 2021;112:853–856.