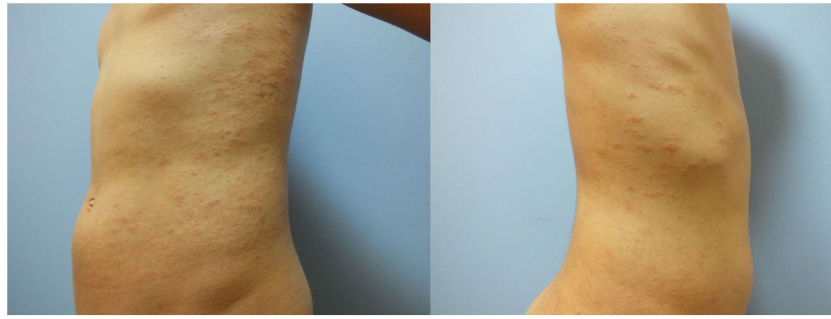

**Figure 2** Focal mounds of parakeratosis, mild exocytosis of lymphocytes, mild perivascular mononuclear inflammatory cells and some extravasated erythrocytes (Hematoxylin & eosin,  $\times 200$ ).

2. Veraldi S, Romagnuolo M, Benzecry V. Pityriasis rosea-like eruption revealing COVID-19. *Australas J Dermatol.* 2020;10:1111.
3. Drago F, Ciccarese G, Rebora A, Parodi A. Human herpesvirus-6, -7, and Epstein-Barr virus reactivation in pityriasis rosea during COVID-19. *J Med Virol.* 2020;24(10):1002.
4. Veraldi S, Spigariolo CB. Pityriasis rosea and COVID-19. *J Med Virol.* 2020;18(10):1002.
5. Johansen M, Chisolm SS, Aspey LD, Brahmbhatt M. Pityriasis rosea in otherwise asymptomatic confirmed COVID-19-positive patients: a report of 2 cases. *JAAD Case Rep.* 2021;7:93–4.

I.N.S. Öncü,<sup>a,\*</sup> D. Güler,<sup>a</sup> G. Gürel,<sup>a</sup> G.Ş. Yalçın<sup>b</sup>

<sup>a</sup> *Departamento de Dermatología, Facultad de Medicina, Afyonkarahisar Health Sciences University, Afyonkarahisar, Turkey*

<sup>b</sup> *Departamento de Patología, Facultad de Medicina, Afyonkarahisar Health Sciences University, Afyonkarahisar, Turkey*

\* Corresponding author.

E-mail address: [oncuisin@gmail.com](mailto:oncuisin@gmail.com) (I.N.S. Öncü).

<https://doi.org/10.1016/j.adengl.2021.07.006>  
1578-2190/ © 2021 Published by Elsevier España, S.L.U. on behalf of AEDV. This is an open access article under the CC BY-NC-ND license (<http://creativecommons.org/licenses/by-nc-nd/4.0/>).

## Plaque psoriasis in a patient with sarcoidosis<sup>☆</sup>



### Psoriasis en placa en un paciente con sarcoidosis

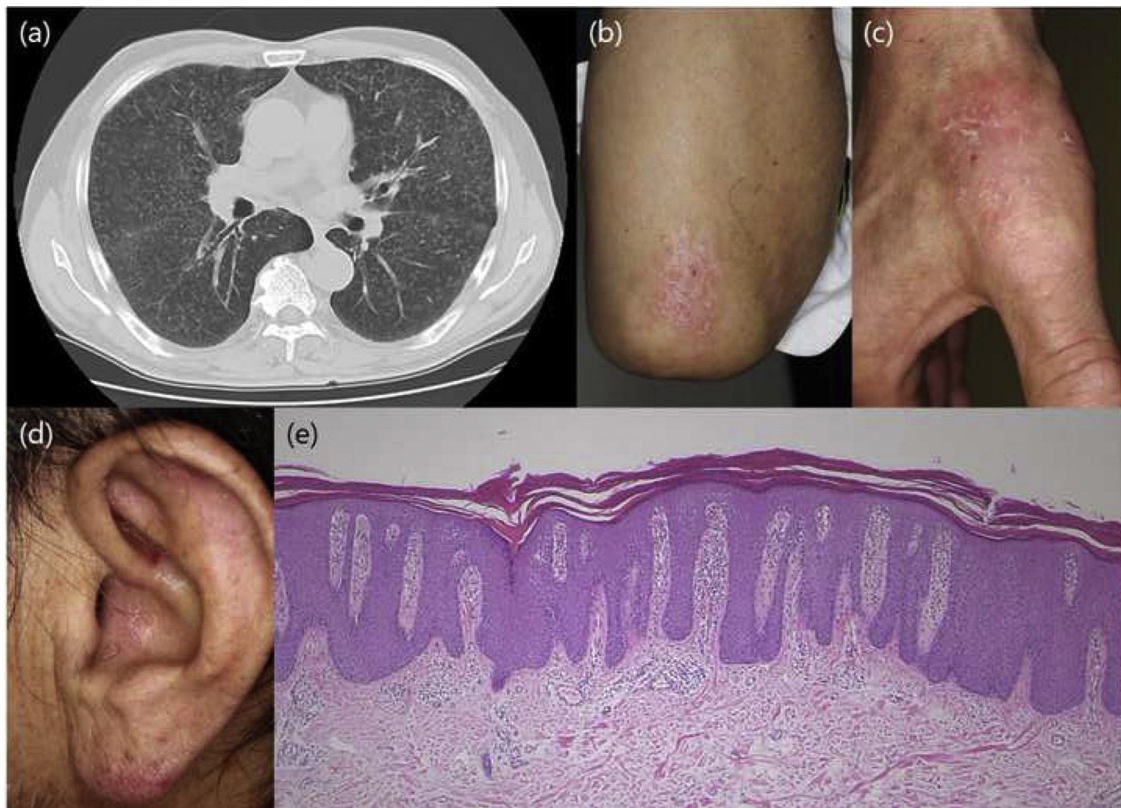
Dear Editor,

A 65-year-old man was admitted to the respiratory department of our hospital, for the detail investigation of bilateral hilar lymphadenopathy. Examination by lung computed tomography revealed lymph node adenopathy (Fig. 1) and bronchoscopic lung biopsy revealed non-caseating epithelioid granulomas, and thus he was diagnosed with sarcoidosis. Also, he was suffering from diabetes mellitus for five years previously. During admission, he was referred to our department complaining of itchy eruptions of the upper limbs and ears. He stated that he was diagnosed with psoriasis eight years previously and treated with topical corticosteroids but without sufficient effects. On physical examination, scaly erythematous plaques were scattered on the knees, elbows, fingers and ears. Nail involvement was

not observed, and he had no arthritis. Skin lesions suggestive of sarcoidosis were not seen on the scalp, trunk and extremities including the knee. Results of laboratory examination elevated serum angiotensin converting enzyme (34.0 U/ml, normal; 8.3-21.4), sIL-2R (1850 U/ml,<sup>1-4</sup> normal; 121-613) and negative tuberculin reaction. Neither ocular nor cardiac sarcoidosis was detected in detailed examination. Histological examination from the knee lesion showed regular epidermal proliferation, intraepidermal neutrophil infiltration, parakeratosis, dilated vessels in the dermal papilla, and perivascular cellular infiltrates. CD4<sup>+</sup> and CD8<sup>+</sup> T-cells were detected in the epidermis and upper dermis. Sarcoid granulomas were not observed in the dermis or subcutis. The patient was treated with topical corticosteroid ointment.

The present patient first developed psoriasis, and five years later the diagnosis of sarcoidosis was made. He had been treated with topical therapy only, therefore it is unexpected that sarcoidosis was induced by medications for psoriasis. He had ocular and lung sarcoidosis, whereas cutaneous sarcoid lesions were not observed, at least at the initial visit to our department. To date, several cases of co-existence of psoriasis and sarcoidosis have been reported<sup>1</sup>. Those cases usually present both cutaneous psoriatic and sarcoid skin lesion, whereas our patient did not exhibit cutaneous sarcoidosis. T helper(Th)1 type cytokines are favored in the initial phase of sarcoidosis. In particular, tumor necrosis factor (TNF)- $\alpha$  is important in the formation of sarcoid granuloma<sup>2</sup>. A shared TNF- $\alpha$ -mediated patho-

<sup>☆</sup> Please cite this article as: Ishikawa M, Yamamoto T. Psoriasis en placa en un paciente con sarcoidosis. *Actas Dermosifiliogr.* 2021;112:865–866.



**Figure 1** Examination by lung computed tomography revealed lymph node adenopathy.

genesis between psoriasis and sarcoidosis may exist. TNF- $\alpha$  activates Th17 cells to lead Interleukin (IL)-17 production, and IL-17 inflammatory pathway has been suggested to be important in psoriasis. Also, recent studies have suggested an important role of IL-17 in sarcoidosis, and enhanced expression of IL-17A<sup>+</sup> interferon- $\gamma$ <sup>+</sup> and IL-17A<sup>+</sup> IL-4<sup>+</sup> memory T cells was shown in sarcoidal lungs<sup>3</sup>. Thus, Th17 profile has been implicated to play a role in sarcoidosis, possibly by inducing granuloma formation *via* suppression of regulatory T cells<sup>3</sup>. Another study showed upregulation of IL-23 and IL-21 in the lesions of cutaneous sarcoidosis<sup>4</sup>. In addition, pso p27 is a protein detected in mast cells in psoriatic lesions and extractable from psoriatic scales. Pso p27 is abundantly expressed in psoriatic lesional skin, and also expression of pso p27 is increased in the lungs of pulmonary sarcoidosis **Figure 1**<sup>5</sup>. Role of pso p27 in sarcoidosis needs further studies.

## References

1. Wanat KA, Schaffer A, Richardson V, Van Voorhees A, Rosenbach M. Sarcoidosis and psoriasis: a case series and review of the literature exploring co-incidence vs coincidence. *JAMA Dermatol.* 2013;149:848–52.
2. Amber KT, Bloom R, Mrowietz U, Hertl M. TNF- $\alpha$ : a treatment target or cause of sarcoidosis? *J Eur Acad Dermatol Venereol.* 2015;29:2104–11.
3. Ten Berge B, Paats MS, Bergen IM, van den Blink B, Hoogsteden HC, Lambrecht BN, et al. Increased IL-17A expression in granulomas and in circulating memory T cells in sarcoidosis. *Rheumatology.* 2012;51:37–46.
4. Judson MA, Marchell RM, Mascelli M, Piantone A, Barnathan ES, Petty KJ, et al. Molecular profiling and gene expression analysis in cutaneous sarcoidosis: the role of interleukin-12, interleukin-23, and the T-helper 17 pathway. *J Am Acad Dermatol.* 2012;66:901–10.
5. Jacobsen T, Lie BA, Lysvand H, Wiig M, Pettersen HB, Iversen OJ. Detection of psoriasis-associated antigen pso p27 in sarcoidosis bronchoalveolar lavage fluid using monoclonal antibodies. *Clin Immunol Immunopathol.* 1996;81:82–7.

M. Ishikawa,\* T. Yamamoto

*Departamento de Dermatología, Fukushima Medical University, Fukushima, Japan*

\*Corresponding author.

E-mail address: [ishimasa@fmu.ac.jp](mailto:ishimasa@fmu.ac.jp) (M. Ishikawa).

11 December 2019 10 February 2020

<https://doi.org/10.1016/j.adengl.2021.07.016>  
1578-2190/ © 2021 Published by Elsevier España, S.L.U. on behalf of AEDV. This is an open access article under the CC BY-NC-ND license (<http://creativecommons.org/licenses/by-nc-nd/4.0/>).