

Conclusion

Although the reading man flap was initially described to cover circular defects on the cheek, and indeed it is a good option for this site, we believe that the advantages mentioned with respect to other local plasties make it a particularly useful option in regions submitted to high tension such as large defects on the trunk or those in body areas with movements of flexion and tension, such as the wrist in the case of our patient. In these regions of flexion and tension in particular, other reconstructive options such as grafts or Limberg plasties can generate more traction with a greater risk of functional deficit.

Conflicts of Interest

The authors declare that they have no conflicts of interest.

References

1. Mutaf M, Sunay M, Bulut O. The "reading man" procedure: a new technique for the closure of circular skin defects. *Ann Plast Surg.* 2008;60:420–5.
2. Mutaf M, Günel E, Temel M. Closure of defects of the malar region. *J Craniofac Surg.* 2011;22:631–4.
3. Cecchi R, Fancelli L, Troiano M. Letter: the "reading man" flap in facial reconstruction: report of 12 cases. *Dermatol Online J.* 2012;18:16.
4. Mutaf M, Temel M, Günel E. The reading man flap for closure of large meningomyelocele defects. *J Plast Reconstr Aesthet Surg.* 2012;65:578–83.

5. Sapountzis S, Park HJ, Kim JH, Chantes A, Beak RM, Heo CY. The "reading man flap" for pressure sore reconstruction. *Indian J Plast Surg.* 2011;44:448–52.
6. Wagner JA, Simon JC, Wetzig T, Kendler M. Outcomes of wound closure with the reading man flap technique. *J Cutan Med Surg.* 2013;17:384–6.
7. Blázquez-Sánchez N, Repiso-Jiménez JB, García-Harana C, de Troya-Martín N. El colgajo del lector en cirugía dermatológica. *Piel (Barc).* 2019;34:116–8.
8. Seyhan T, Caglar B. Reading man flap design for reconstruction of circular infraorbital and malar skin defects. *Dermatol Surg.* 2008;34:1536–43.
9. Jovic TH, Jessop ZM, Slade R, Dobbs T, Whitaker IS. The use of keystone flaps in periarthicular wound closure: a case series. *Front Surg.* 2017;4:68.
10. Pichler M, Deluca J, Tappeiner L, Eisendle K. Reconstruction of large rectangular infraorbital and malar skin defects in elderly patients with a modified "reading man flap" using local tumescent anesthesia. *Int J Dermatol.* 2014;53:1520–5.

Í. Martínez de Espronceda Ezquerro*, M. Azcona Rodríguez, J. Sarriguarte Aldecoa-Otalora, M.E. Iglesias Zamora *Servicio de Dermatología, Complejo Hospitalario de Navarra, Pamplona*

* Corresponding author.

E-mail address: martinezespronceda@gmail.com (Í. Martínez de Espronceda Ezquerro).

<https://doi.org/10.1016/j.adengl.2021.03.005>
1578-2190/ © 2020 AEDV. Published by Elsevier España, S.L.U. This is an open access article under the CC BY-NC-ND license (<http://creativecommons.org/licenses/by-nc-nd/4.0/>).

Erythrodermic Lichen Planus[☆]



Liquen plano eritrodérmico

To the Editor:

A 51-year-old man with a history of morbid obesity and smoking, who reported having recently taken medication, visited the emergency department with a highly pruritic rash that had appeared 2 months earlier and had spread to practically the entire body area. Physical examination revealed erythroderma consisting of the convergence of multiple erythematous-violaceous papules, some with a lichenoid sheen, accompanied by palmoplantar keratoderma (Fig. 1). The facial area was spared, together with some areas of skin on the lower part of the abdomen. Several fingernails showed trachyonychia and onychorrhexis. No abnormalities were observed in the oral or genital mucosa. The patient's general condition was good, with no symptoms in other organs or systems, no enlarged lymph nodes, and no fever. Due to the intense pruritus, the patient had received treatment in primary care with 5% topical permethrin and

methylprednisolone at low doses, with no improvement. No other family members suffered from pruritus.

A punch biopsy was performed, and histology revealed intense lichenoid interface dermatitis, with lymphocyte infiltrate with no eosinophils or plasma cells, with apoptotic Civatte bodies in the basement layer and absence of parakeratosis (Fig. 2). A general analysis was ordered (blood count, biochemistry, renal function, liver function, and lipid profile) with normal results. Serology for HVB, HVC, HIV, and syphilis, and antinuclear antibody determination, anti-SSA-Ro, and anti-SSB-La were negative.

Given the results of the general analysis and while waiting for the other additional tests, treatment with cyclosporin (400 mg/24 h) was instated, as its use was not contraindicated and covered other potential causes of erythroderma, such as atopic dermatitis and psoriasis. After a week, the patient reported notable improvement of the lesions, with complete disappearance of the pruritus. A month later, only residual hyperpigmentation was observable (Fig. 3). It was possible to suspend medication and the patient remained without signs of recurrence after 6 months of follow-up.

Because the patient stated that he had not previously taken or applied drugs or been exposed to toxins, and based on the clinical and pathology findings, a diagnosis was made of erythrodermic lichen planus, a very rare variety of both lichen planus and erythroderma.

[☆] Please cite this article as: P.J. Gómez Arias, F. Leiva Cepas, M. Galán Gutiérrez, Vélez García-Nieto AJ. Liquen plano eritrodérmico. *Actas Dermosifiliogr.* 2021;112:565–567.

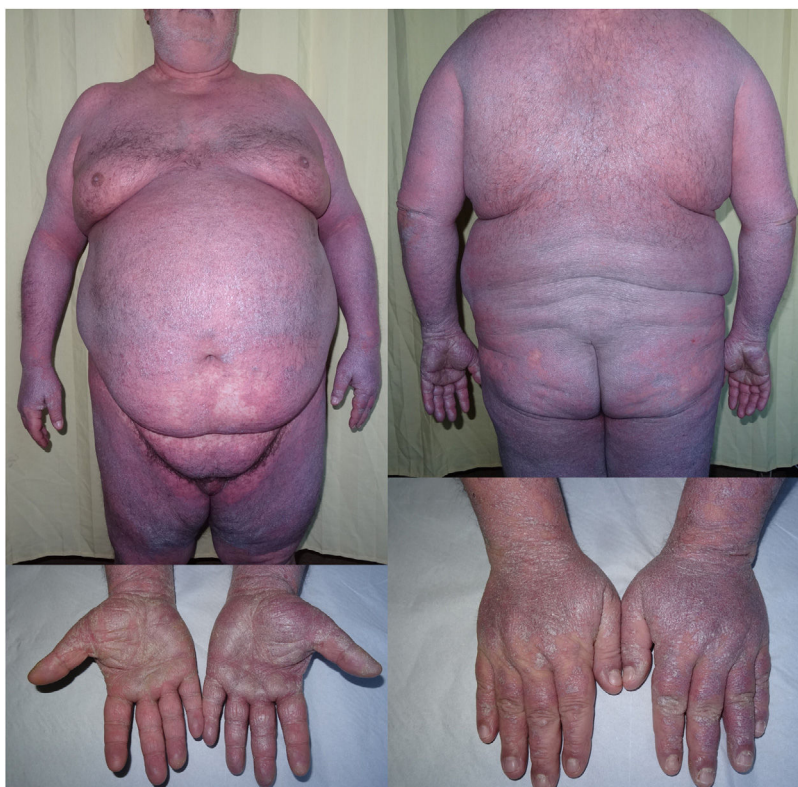

Figure 1 Top left and right, Extensive erythematous-violaceous Dermatitis with lichenoid sheen. Bottom right, Erythematous-violaceous papules with a lichenoid sheen on the backs of the hands and fingers. Bottom left, Shiny palmar keratoderma.

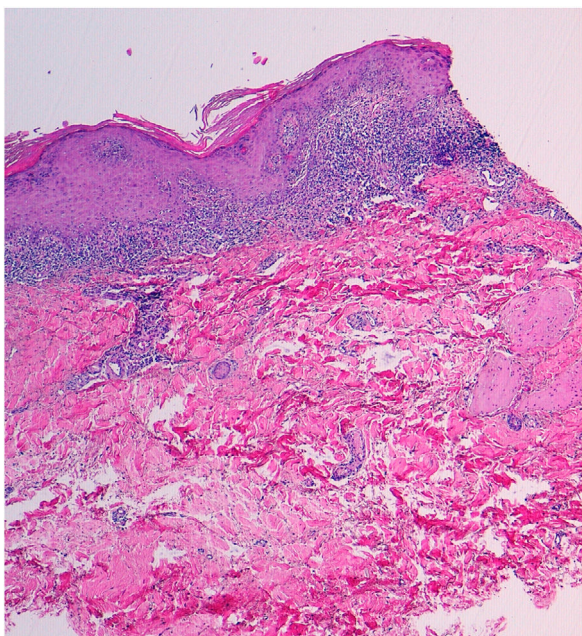


Figure 2 Hematoxylin-eosin, $\times 40$. Intense lichenoid interface dermatitis.

Lichen planus or an extensive lichenoid drug reaction must be taken into account in the differential diagnosis of erythroderma.¹⁻³ The presence of lesions with a lichenoid sheen in the habitual locations (wrists and/or ankles) and

the blue-violaceous color can provide clinical guidance that the erythroderma is due to a lichen planus.⁴

The distinction between an extensive lichenoid drug reaction (ELDR) and an erythrodermic lichen planus (ELP) may be difficult to establish. ELDR is secondary to the use of drugs and it is therefore important when taking the patient's history to inquire about previous ingested or topical drugs or other substances. These signs and symptoms appear mainly on the torso, do not usually involve the ankles and wrists (at least initially), and may present an eczematous or psoriasiform appearance, with a photosensitive or symmetrical pattern. Histology may reveal eosinophils and plasma cells, which are much less common in cases of ELP, together with parakeratosis and cytoid bodies in the upper layers of the epidermis, which are also rare in ELP. ELDR does not usually present Wickham striae when examined using dermoscopy. ELP, however, tends to initially appear in the typical areas, is not distributed in areas exposed to sunlight, and more frequently involves the mucosa. Lichenoid reactions have been reported after use of nonsteroidal anti-inflammatory drugs, antihypertensive drugs (angiotensin-converting enzyme inhibitors), antifungal agents (ketoconazole), antiretroviral drugs, antibiotics (tetracyclines), beta-blockers (propranolol), antimalarials, cytostatic drugs, tuberculostatic agents (ethambutol), diuretics (thiazides), anticonvulsives (carbamazepine), gold and lithium salts, heavy metals, hypouricemic agents (allopurinol), hypoglycemic agents (sulfonylureas), tyrosine kinase inhibitors, anti-TNF drugs, and others (methyldopa, penicillamine, diltiazem, chlorpromazine, etc).⁵

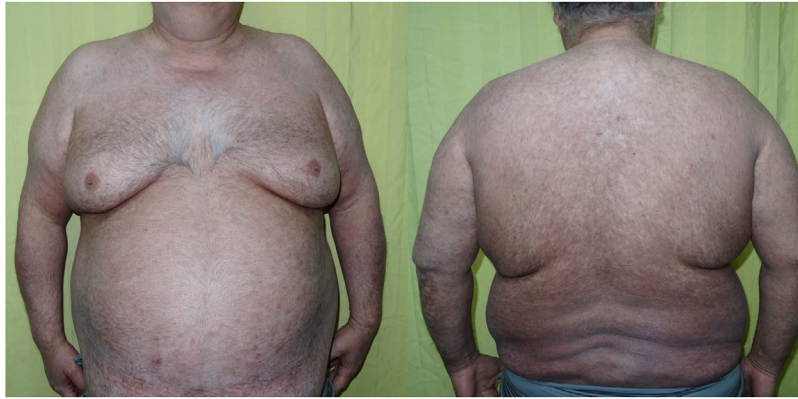

Figure 3 Resolution of the erythroderma after administration of 400 mg/24 h of cyclosporin A for 30 days. Residual hyperpigmentation.

In the case of our patient, no drugs prior to the rash were identified. Moreover, the response to cyclosporin was excellent, with no relapse when the drug was suspended. This drug has been used sporadically and successfully in lichen planus⁶ and its use may be considered to achieve rapid control of symptoms when lesions are very extensive.

Conflicts of Interest

The authors declare that they have no conflicts of interest.

References

1. Wagner G, Rose C, Sachse MM. Clinical variants of lichen planus. *J Dtsch Dermatol Ges.* 2013;11:309–19.
2. Rose AE, Patel U, Chu J, Patel R, Meehan S, Latkowski JA. Erythrodermic lichen planus. *Dermatol Online J.* 2011;17:26.
3. Gupta LK, Garg A, Khare AK, Mittal A. Lichen planus presenting as erythroderma. *Indian J Dermatol Venereol Leprol.* 2012;78:409.
4. Cuellar Barboza A, Ocampo Candiani J, Herz Ruelas ME. Eritrodermia en el adulto: un enfoque práctico para el diagnóstico y tratamiento. *Actas Dermosifiliogr.* 2018;109:777–90.
5. Tziotzios C, Lee JYW, Brier T, Saito R, Hsu CK, Bhargava K, et al. Lichen planus and lichenoid dermatoses: Clinical overview and molecular basis. *J Am Acad Dermatol.* 2018;79:789–804.

6. Ho VC, Gupta AK, Ellis CN, Nickoloff BJ, Voorhees JJ. Treatment of severe lichen planus with cyclosporine. *J Am Acad Dermatol.* 1990;22:64–8.

P.J. Gómez Arias*

UGC de Dermatología Médico-Quirúrgica y Venereología, Hospital Universitario Reina Sofía, Córdoba, Spain

F. Leiva Cepas

UGC de Anatomía Patológica, Hospital Universitario Reina Sofía, Córdoba, Spain

M. Galán Gutiérrez, A.J. Vélez García-Nieto

UGC de Dermatología Médico-Quirúrgica y Venereología, Hospital Universitario Reina Sofía, Córdoba, Spain

* Corresponding author.

E-mail address: pjga10@hotmail.com (P.J. Gómez Arias).

<https://doi.org/10.1016/j.adengl.2021.03.015>
1578-2190/ © 2020 AEDV. Published by Elsevier España, S.L.U. This is an open access article under the CC BY-NC-ND license (<http://creativecommons.org/licenses/by-nc-nd/4.0/>).