

Eruptions of sebaceous adenomas and carcinomas induced by tacrolimus[☆]



Adenomas sebáceos y carcinoma sebáceo eruptivos inducidos por tacrolimus

To the Editor:

Sebaceous adenoma (SA) and sebaceous carcinoma (SC) are uncommon adnexal tumors with sebaceous differentiation. SA is a benign lesion, whereas SC is a malignant neoplasm. Both can appear in isolation or in the context of Muir-Torre syndrome (MTS).¹

A 60-year-old man consulted for the gradual appearance of asymptomatic facial tumors over the previous 8 years. The patient had received a lung transplant 15 years earlier and was therefore receiving immunosuppressive treatment with tacrolimus and oral corticosteroids, as well as everolimus (last 3 years). The skin lesions stabilized with the introduction of everolimus. The patient had no personal or family history of malignancy of intestinal polyposis.

Physical examination revealed multiple umbilicated tumors on the face. These were pinkish in color, measured 5–25 mm, and were found mainly on the nasal dorsum, forehead, and cheeks. Dermoscopy revealed the presence of pale yellowish globules on an erythematous background accompanied by branching and tortuous vessels (Fig. 1). Dermatopathology revealed a well-circumscribed tumor formed by sebaceous lobules separated by septa of connective tissue. Each lobule was composed of basaloid cells on the periphery and mature sebaceous cells in the center. Of note was the presence of more disordered maturation than in healthy sebaceous glands, with scant mitotic figures and no necrosis. These findings were consistent with a diagnosis of SA (Fig. 2). Immunohistochemical staining for MLH1, MSH2, MSH6, and PMS2 ruled out microsatellite instability, thus making a diagnosis of associated MTS unlikely (Fig. 2B).

Several lesions were removed at successive check-ups for diagnostic and therapeutic purposes. All of the lesions were reported to be SA, except for a lesion that had first appeared on the area of the maxilla 2 months earlier and was diagnosed as SC. Dermatopathology of this lesion revealed an ulcerated tumor with a lobular pattern composed of non-differentiated cells with large nuclei, prominent nucleoli,

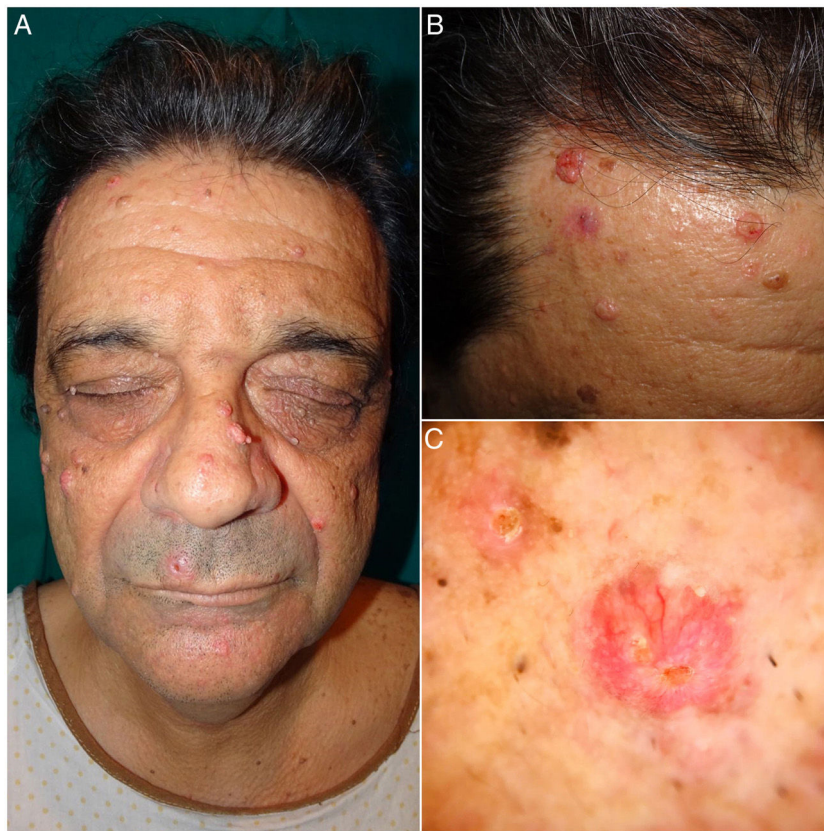

Figure 1 A and B, Clinical images of sebaceous adenoma. Multiple pink tumors on the face measuring 5 to 25 mm. C, Dermoscopic image of sebaceous adenoma. Note the pale yellowish globules over an erythematous base, together with branching tortuous vessels.

[☆] Please cite this article as: Navarro-Navarro I, Jiménez-Gallo D, Tello-Collantes K, Linares-Barríos M. Adenomas sebáceos y carcinoma sebáceo eruptivos inducidos por tacrolimus. *Actas Dermosifiliogr.* 2021;112:378–381.

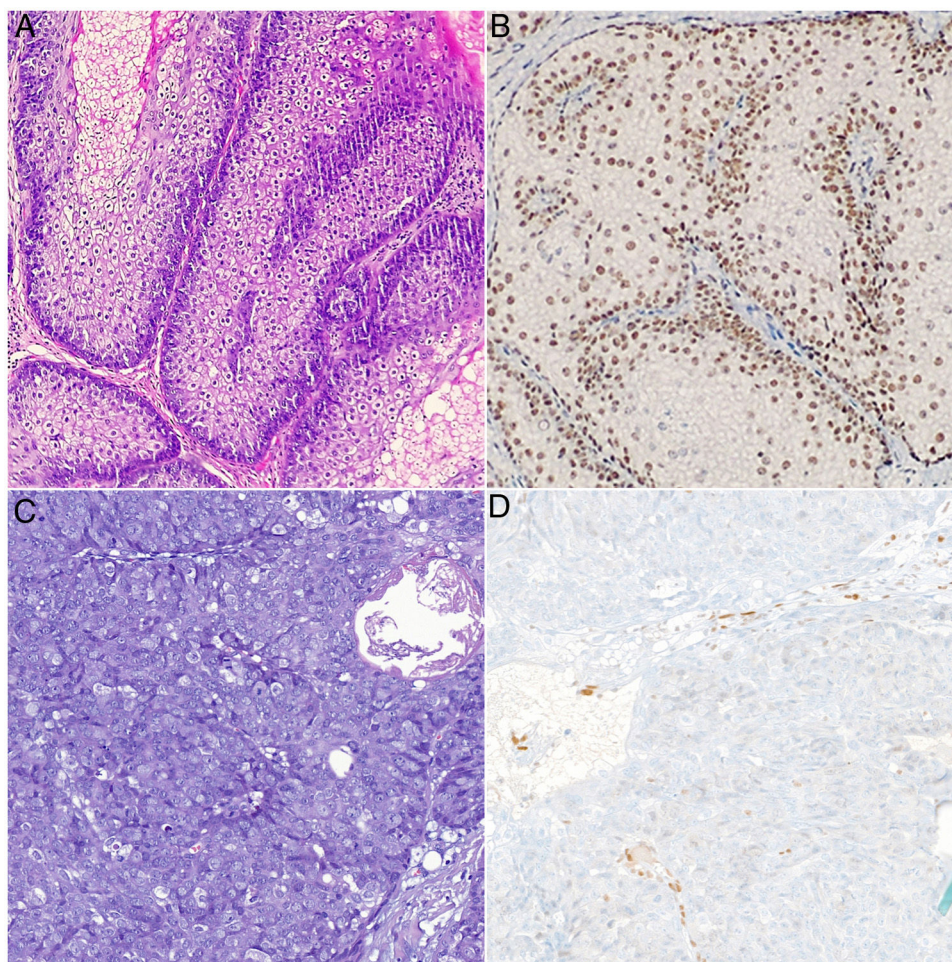


Figure 2 A and B) Histologic images of sebaceous adenoma. Note the sebaceous lobules composed of basaloid cells on the periphery and mature sebaceous cells in the center. These are separated by septa of connective tissue. Intact nuclear positivity for MSH6: A, hematoxylin-eosin, $\times 20$. B, Immunohistochemistry staining for MSH6, $\times 20$. C and D, Histology images of sebaceous carcinoma. Nondifferentiated cells with large nuclei, prominent nucleoli, abundant mitotic figures, and areas of necrosis. Note the loss of nuclear positivity for MSH6 in the tumor cells (C), hematoxylin-eosin, original magnification, $\times 20$; (D) immunohistochemistry staining for MSH6, $\times 20$.

and abundant mitotic figures. The tumor penetrated deeply and showed broad areas of necrosis (Fig. 2C). Immunohistochemistry for detection of DNA replication error repair proteins revealed a loss of nuclear positivity in the tumor cells exclusively for MSH6 (Fig. 2D). Amplification of the margins of the SC was negative, as was cervical and parotid ultrasound, thus making it possible to rule out locoregional involvement. The only finding in colonoscopy for screening of colorectal cancer was an isolated hyperplastic polyp in the area of the rectum. The patient continues to undergo twice-yearly clinical and radiological check-ups.

Solid organ recipients receiving immunosuppressive treatment have a greater risk of developing cutaneous adnexal tumors, including sebaceous tumors. Calcineurin inhibitors such as ciclosporin and tacrolimus lead to their development via interaction with transforming growth factor (TGF) β , overexpression of TGF- $\beta 1$ and vascular endothelial growth factor C, thus enabling them to interfere in the differentiation and growth of the sebaceous glands.

Onset of malignancies and proliferations with sebaceous differentiation in patients taking calcineurin inhibitors is very uncommon. It has been reported sporadically and in association with MTS (Table 1).³⁻¹⁰

In the present case, the time sequence suggests that tacrolimus was probably the drug responsible for the pathogenesis of the sebaceous neoplasms. Everolimus does not seem to be associated with the development of these sebaceous neoplasms, given its administration when the lesions had already developed, stabilization of the lesion after initiation, the absence of associated cases in the literature, and its antiproliferative tumor effect via the mTOR pathway. The loss of nuclear positivity for MSH6 in SC is probably a consequence of a sporadic somatic mutation of the malignant cells, given the absence of intestinal polyposis and intact nuclear positivity in immunohistochemistry staining for diagnosis of cutaneous SAs.

Table 1 Case Reports of Sebaceous Neoplasms in Transplant Recipients Treated With Calcineurin Inhibitors.

	Type of neoplasm or proliferation	Transplant	Calcineurin inhibitor	Muir-Torre syndrome
3. Jung HY, <i>Ann Dermatol.</i> 2016	Sebaceous hyperplasia	Kidney	Ciclosporin + tacrolimus	No
4. Boschnakow A, <i>Br J Dermatol.</i> 2003	Sebaceous hyperplasia (×2 patients)	Kidney (×2)	Ciclosporin (×2)	No (×2)
5. Levandoski KA, <i>Dermatol Online J.</i> 2017	Sebaceous hyperplasia	Kidney	Tacrolimus	No
6. Seo BF, <i>Ann Dermatol.</i> 2014	Sebaceous carcinoma	Liver	Tacrolimus	No
7. Kaminska ECN, <i>J Cutan Pathol.</i> 2013	Borderline sebaceous neoplasm	Kidney	Tacrolimus	No
8. Donati M, <i>Exp Clin Transplant.</i> 2017	Multiple sebaceous adenomas	Kidney	Tacrolimus	Doubtful. Mutation in MSH6- <i>eson 1</i> (c116G > A)
9. Landis MN, <i>J Am Acad Dermatol.</i> 2011	Multiple sebaceous adenomas, sebaceoma, sebaceous carcinomas	Kidney	Tacrolimus	Yes
10. Levi Z, <i>Am J Transplant.</i> 2007	Multiple sebaceous adenomas, sebaceous carcinomas	Lung	Tacrolimus	Yes
Present case	Multiple sebaceous adenomas and sebaceous carcinoma	Lung	Tacrolimus	No

Conflicts of interest

The authors declare that they have no conflicts of interest.

References

- Flux K. Sebaceous neoplasms. *Surg Pathol Clin.* 2017;10:367–82, <http://dx.doi.org/10.1016/j.path.2017.01.009>.
- Jung Hy, Kim M, Cho Bk, Park HJ. A case of cyclosporine-induced sebaceous hyperplasia in a renal transplant patient successfully treated with isotretinoin. *Ann Dermatol.* 2016;28:271, <http://dx.doi.org/10.5021/ad.2016.28.2.271>.
- Boschnakow A, May T, Assaf C, Tebbe B, Zouboulis CC. Ciclosporin A-induced sebaceous gland hyperplasia. *Br J Dermatol.* 2003;149:198–200, <http://dx.doi.org/10.1046/j.1365-2133.2003.05397.x>.
- Levandoski KA, Girardi NA, Loss MJ. Eruptive sebaceous hyperplasia as a side effect of oral tacrolimus in a renal transplant recipient. *Dermatol Online J.* 2017;23. Available from: <http://www.ncbi.nlm.nih.gov/pubmed/28537866> [Accessed 14 July 2018].
- Seo BF, Jung HW, Choi IK, Rhie JW. Sebaceous carcinoma of the suprapubic area in a liver transplant recipient. *Ann Dermatol.* 2014;26:395–8, <http://dx.doi.org/10.5021/ad.2014.26.3.395>.
- Kaminska ECN, Iyengar V, Tsoukas M, Shea Cr. Borderline sebaceous neoplasm in a renal transplant patient without Muir-Torre syndrome. *J Cutan Pathol.* 2013;40:336–40, <http://dx.doi.org/10.1111/cup.12046>.
- Donati M, Paolino G, Muscardin L, Panetta C, Donati P. Resolution of benign and malignant sebaceous neoplasms, in a renal transplant patient treated with everolimus. *Exp Clin Transplant.* 2017;15:100–2, <http://dx.doi.org/10.6002/ect.2014.0208>.
- Landis MN, Davis CL, Bellus GA, Wolverton SE. Immunosuppression and sebaceous tumors: a confirmed diagnosis of Muir-Torre syndrome unmasked by immunosuppressive therapy. *J Am Acad Dermatol.* 2011;65, <http://dx.doi.org/10.1016/j.jaad.2010.08.003>, 1054.e1–8.e1.
- Levi Z, Hazazi R, Kedar-Barnes I, Hodak E, Gal E, Mor E, et al. Switching from tacrolimus to sirolimus halts the appearance of new sebaceous neoplasms in Muir-Torre syndrome. *Am J Transplant.* 2007;7:476–9, <http://dx.doi.org/10.1111/j.1600-6143.2006.01648.x>.

I. Navarro-Navarro^{a,*}, D. Jiménez-Gallo^a, K. Tello-Collantes^b, M. Linares-Barrios^a

^a *Unidad de Gestión Clínica de Dermatología Médico-Quirúrgica y Venereología, Hospital Universitario Puerta del Mar, Cádiz, Spain*

^b *Unidad de Gestión Clínica de Anatomía Patológica, Hospital Universitario Puerta del Mar, Cádiz, Spain*

* Corresponding author.

E-mail address: irenen.navarro@gmail.com

(I. Navarro-Navarro).

10 August 2019 4 November 2019

<https://doi.org/10.1016/j.adengl.2021.01.030>
1578-2190/ © 2020 AEDV. Published by Elsevier España, S.L.U. This is an open access article under the CC BY-NC-ND license (<http://creativecommons.org/licenses/by-nc-nd/4.0/>).