

5. Langendonk JG, Balwani M, Anderson KE, Bonkovsky HL, Anstey AV, Bissell DM, et al. Afamelanotide for Erythropoietic Protoporphyrin. *N Engl J Med.* 2015;373:48–59.
6. Elder G, Harper P, Badminton M, Sandberg S, Deybach J. The incidence of inherited porphyrias in Europe. *J Inher Metab Dis.* 2013;36:849–57.
7. Mykletun M, Aaesand AK, Støle E, Haugen J, Tollånes MC, Baravelli C, et al. Porphyrias in Norway. *Tidsskr Nor Lægeforen.* 2014;134:831–6.
8. Jaramillo-Calle DA, Acevedo D. Acute Hepatic Porphyrias in Colombia: An Analysis of 101 Patients. *JIMD Rep.* 2019;44:65–72.

D.A. Jaramillo-Calle

*Centro de Investigación de las Porfirias en Colombia (PorfiCol), Universidad de Antioquia, Medellín, Colombia*  
 E-mail address: [Daniel.jaramillo2@udea.edu.co](mailto:Daniel.jaramillo2@udea.edu.co).

<https://doi.org/10.1016/j.adengl.2019.04.023>  
 1578-2190/ © 2020 AEDV. Published by Elsevier España, S.L.U. This is an open access article under the CC BY-NC-ND license (<http://creativecommons.org/licenses/by-nc-nd/4.0/>).

## Double Nail of the Fifth Toe<sup>☆</sup>



### Doble uña del quinto dedo del pie

To the Editor:

A 44-year-old man visited our department with prominences on both sides of the fifth toe, which had appeared following a walk, on which he had worn tight footwear. The patient complained of discomfort only when pressure was applied to this area. Physical examination revealed external rotation of the fifth toe and increased width of the nail plate on both small toes. Each of these nails was also covered by cuticle, divided by a longitudinal cleft, and the nail plate showed lateral thickening (Fig. 1A and Fig. 2A). Dermoscopy confirmed that the nail consisted of 2 clearly demarcated parts (Fig. 1, Fig. 2, and Fig. 2B). The patient was not aware of this abnormality in any family member. A simple anteroposterior and lateral x-ray of both feet was requested and ruled out the presence of accessory phalanges or other bone abnormalities (Fig. 3). No treatment was indicated, other than reduction of the direct trauma.

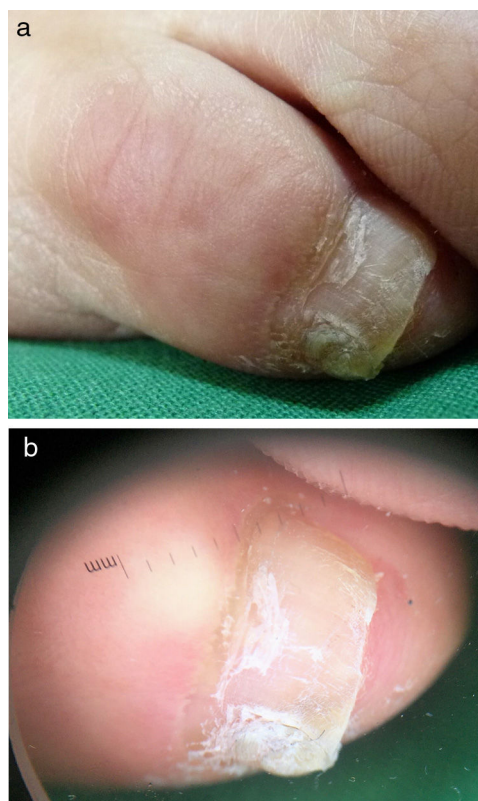
The double nail of the fifth toe (DNFT) or accessory nail of the fifth toe was described in 1969 by Huindeker and is an apparently common entity, although few published cases exist.<sup>1–4</sup>

The most common clinical presentation is the appearance of a wider-than-normal nail divided by a longitudinal cleft, fold, or depression, and the part corresponding to the accessory nail is smaller. A cuticle covers both nail plates in the proximal area of the nail. DNFT may be unilateral or bilateral, and when both toes are affected there tends to exist considerable symmetry.<sup>3,4</sup> Clinical or aesthetic problems due to the size of the nail occur only occasionally.<sup>3,4</sup>

It is rare to find abnormalities in the x-ray of the fifth toe. Of 10 x-rays performed in 1 series, only 3 patients presented a lazy Y on the tip of the distal phalanx, and another patient presented a thorn-like bony excrescence.<sup>4</sup> A Y-shaped tip of the terminal phalangeal bone was identified during surgery in 2 patients.<sup>4</sup> DNFT was initially thought to be a hereditary process limited to the Han ethnic group, the largest ethnic group in China.<sup>3</sup> Haneke, however, found that the entity showed no racial or ethnic predilection.<sup>4</sup> Autosomal dominant heredity with variable expression has been proposed.<sup>4</sup>

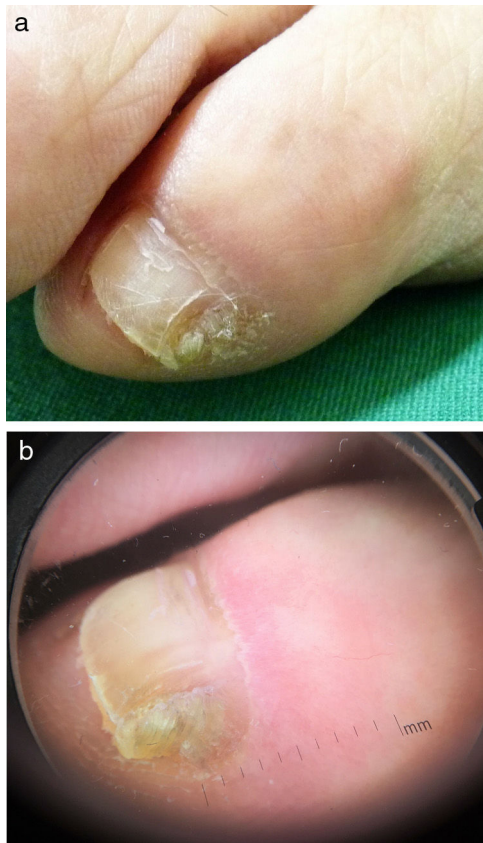
Familial cases show no clear predisposition by sex, although women consult more for this abnormality.<sup>5,6</sup> DNFT may represent an initial form of hexadactyly, which would give rise to a rudimentary nail.<sup>4</sup> Acute trauma may act on the onychodermis which, as specialized nail mesenchyma, would lead to nail formation and growth. The onychodermis is made up of onychofibroblasts and takes part in nail formation and growth.<sup>7</sup>

The histology of excised accessory nails varies from a depression like a sack of skin with hyperkeratosis like a nail plate, to a small nail with a matrix, proximal fold, nail bed, and hyponychium.<sup>5,6</sup>



**Fig. 1** Clinical image of the fifth toe. A, right toe. B, left toe presenting external rotation and increased nail size, with a longitudinal fissure dividing the nail plate.

<sup>☆</sup> Please cite this article as: Navarro Campoamor L. Doble uña del quinto dedo del pie. *Actas Dermosifiliogr.* 2021;112:188–190.

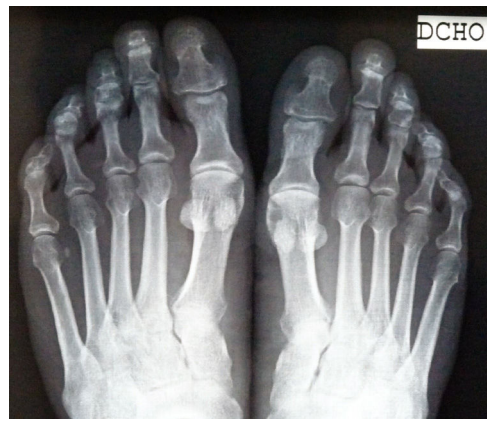

**Fig. 2** Dermatoscopy of the fifth toe. A, right toe. B, left toe.

The differential diagnosis is established with ectopic nail, postoperative spiculated nail, onychophosis, or callus of the fifth toe. Ectopic nail or onychoheterotopia refers to growth of a nail outside the nail bed. It may be congenital or be associated with other diseases, and it is most frequent on the palmar region of the fingers. The acquired form is located on the dorsal region of the fingers and toes. Ectopic nails must have a matrix and nail plate but do not require a nail bed.<sup>8</sup> Onychophosis is a hyperkeratosis of the lateral folds of the nail triggered by frequent trauma to that area, which causes hypertrophy and thickening of the skin surrounding the nail. Calluses or corns on the external surface of the fifth toe consist of hyperkeratosis caused by repeated rubbing of footwear and are usually accompanied by intense pain.

DNFT does not usually require treatment. If desired, phenolization of the accessory matrix or surgical excision of the accessory nail may be performed. Excision of DNFT allows for a better view and excision of the matrix, facilitates repair of the defect remaining after removing the accessory nail, and faster recovery than with other treatments. Curettage and electrocoagulation are not recommended because of the prolonged scarring process and the intense postoperative pain.<sup>3</sup>

In conclusion, we present a case of bilateral double nail of the fifth toe, which developed following acute trauma.



**Fig. 3** Simple anteroposterior x-ray with no abnormal bone findings.

This entity is considered to be common, not rare, and tends to go unnoticed. Further studies are required to determine the etiology of the entity.

### Conflicts of Interest

The author declares that he has no conflicts of interest.

### Acknowledgments

The author would like to thank Dr. Eckart Haneke for the clinical assessment of the presented case.

### References

1. Hundeiker M. Hereditäre Nageldysplasie der 5. Zehe. *Hautarzt*. 1969;20:281–2.
2. Haneke E. Therapie von Nagelfehlbildungen. In: Landthaler M, Hohenleutner U, editors. *Fortschritte der operativen Dermatologie*, 12. Berlin/Wien: Blackwell Wissenschafts-Verlag; 1997. p. 180–7.
3. Chi CC, Wang SH. Inherited accessory nail of the fifth toe cured by surgical matricectomy. *Dermatol Surg*. 2004;30:1177–9, <http://dx.doi.org/10.1111/j.1524-4725.2004.30351.x>.
4. Haneke E. Double nail of the little toe. *Skin Appendage Disord*. 2015;1:163–7, <http://dx.doi.org/10.1159/000443378>.
5. Haneke E. *Histopathology of the nail*. 1st ed India: Taylor & Francis Group; 2017. p. 156–7.
6. Baran R. Nail contour variations. In: Baran R, Hadj-Rabia S, Silverman R, editors. *Pediatric nail disorders*. 1st ed India: Taylor & Francis Group; 2017. p. 27–8.
7. Park JH, Lee DY, Ha SY, Jang KT, Kwon GY, Lee KH, et al. The Concept of Onychodermis (Specialized Nail Mesenchyme) Is Applicable in Normal Adult Nail Unit. *Ann Dermatol*. 2017;29:2346, <http://dx.doi.org/10.5021/ad.2017.29.2.2346>.

8. Riaz F, Rashid RM, Khachemoune A. Onychoheterotopia: pathogenesis, presentation, and management of ectopic nail. *J Am Acad Dermatol.* 2011;64:161–6, <http://dx.doi.org/10.1016/j.jaad.2009.11.018>.

L. Navarro Campoamor\*

*Servicio de Dermatología, Hospital Beata María Ana, Madrid, Spain*

\*Corresponding author.

*E-mail address:* [lournacam@gmail.com](mailto:lournacam@gmail.com)

27 March 2019 9 April 2019

<https://doi.org/10.1016/j.adengl.2020.12.026>  
1578-2190/ © 2020 AEDV. Published by Elsevier España, S.L.U. This is an open access article under the CC BY-NC-ND license (<http://creativecommons.org/licenses/by-nc-nd/4.0/>).

## Photoinduced Granuloma Annulare Confirmed by Experimental Exposure to UVA Light<sup>☆</sup>



### Granuloma anular fotoinducido demostrado experimentalmente mediante fotoprovocación UVA

*To the Editor:*

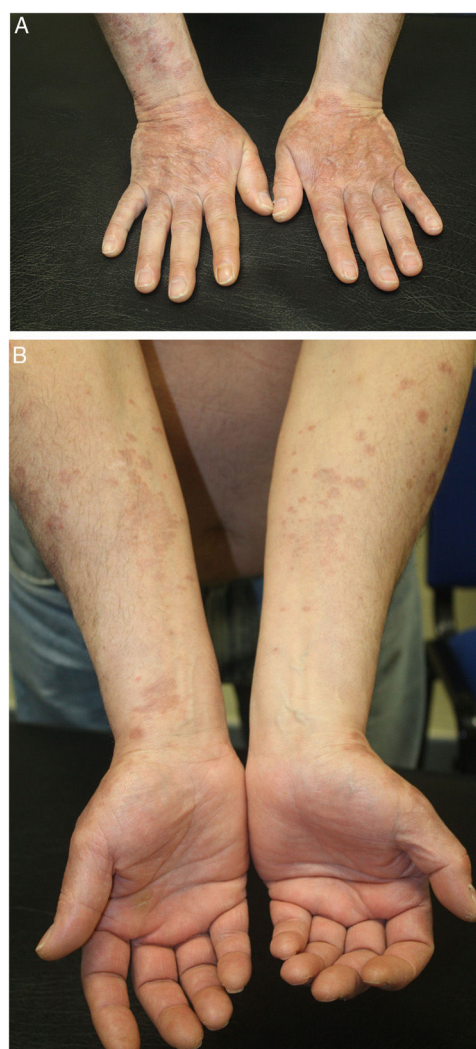A 59-year-old man with type 2 diabetes mellitus who had experienced myocardial infarction 2 years earlier was seen for asymptomatic, generalized, somewhat photodistributed skin lesions that had appeared 1 year earlier and had not responded to topical corticosteroids. The patient was a nonsmoker and was taking daily fenofibrate, aspirin, acenocoumarol, metformin, pantoprazole, folic acid, and bisoprolol. He ruled out any connection between the dermatosis and his work, as the lesions persisted after he left his job as a plasterer.

The dermatological examination revealed annular erythematous and violaceous papules with raised borders that clustered to form plaques on the back of the hands (Fig. 1A).

Smaller, isolated, light pink annular lesions (approximately 3–4 mm) were present on both arms (Fig. 1B).

A phototest was performed using different light sources. A reading was taken immediately to determine the minimum urticarial dose and again after 24 hours to determine the minimum erythematous dose. Photoprovocation and photopatch tests were also performed. The immediate phototest reading revealed a normal response to both ultraviolet (UV) A and UVB light. After 24 hours the values obtained for the minimum erythematous dose were as expected for the patient's phototype (31 mJ/cm<sup>2</sup>), and the response to UVA was normal. Double reading of photopatch tests (non-irradiated and UVA-irradiated [13.32 J/cm<sup>2</sup>] patches) after exposure to the standard battery, together with the drugs that the patient took habitually, revealed no reaction indicative of exogenous skin photosensitivity at either 24 or 48 hours after irradiation (Fig. 2A).

In a photoprovocation test, UVB irradiation of the back and shoulder had no effect, while UVA irradiation (24.42 J/cm<sup>2</sup>; Fig. 2B) resulted in the appearance of some micropapules and erythema after 48 hours. The lesions reappeared on the following days of the photoprovocation test, up until day 6 (cumulative dose, 97.71 J/cm<sup>2</sup>). Based on this



**Figure 1** Clinical presentation of the patient. A, Brownish, arciform, erythematous plaques with a tendency to coalesce on the backs of the hands and the dorsal aspect of the forearms. The lesions were mildly infiltrated and lacked an appreciable epidermal component. B, The lesions extended to the volar aspect of the forearms, where they were milder and coalesced less.

<sup>☆</sup> Please cite this article as: Fonda-Pascual P, de Gálvez MV, Aguilera J, Herrera-Ceballos E. Granuloma anular fotoinducido demostrado experimentalmente mediante fotoprovocación UVA. *Actas Dermosifiliogr.* 2021;112:190–192.