

acts as a neuromodulator, reducing the density of skin nerve fibers and levels of neural growth factors,¹⁰ in addition to its well-established immunomodulatory effect.

Treatment of AP is difficult. We have reported a new case of treatment with UVA/NB-UVB CT, without clinical response, and long-term follow-up of a female patient treated for more than 5 years (4 cycles of UVA/NB-UVB CT) with complete remission of symptoms. Cycles of UVA/NB-UVB CT once a year may be a good alternative for long-term management of some patients with refractory AP.

Funding

This study did not receive any funding.

Conflicts of interest

The authors declare that they have no conflicts of interest.

References

1. Salami TA, Samuel SO, Eze KC, Irekpita E, Oziegbe E, Momoh MO. Prevalence and characteristics of aquagenic pruritus in a young African population. *BMC Dermatol.* 2009;9:4.
2. Heitkemper T, Hofmann T, Phan NQ, Ständer S. Aquagenic pruritus: associated diseases and clinical pruritus characteristics. *J Dtsch Dermatol Ges.* 2010;8:797–804.
3. Nosbaum A, Pecquet C, Bayrou O, Amsler E, Nicolas JF, Bérard F, et al. Treatment with propranolol of 6 patients with idiopathic aquagenic pruritus. *J Allergy Clin Immunol.* 2011;128:1113.
4. Xifra A, Carrascosa JM, Ferrándiz C. Narrow-band ultraviolet B in aquagenic pruritus. *Br J Dermatol.* 2005;153:1233–4.
5. Koh MJA, Chong WS. Aquagenic pruritus responding to combined ultraviolet A/narrowband ultraviolet B therapy. *Photodermatol Photoimmunol Photomed.* 2009;25:169–70.
6. Morgado-Carrasco D, Riera-Monroig J, Fustà-Novell X, Podlipnik S, Aguilera P. Resolution of aquagenic pruritus with intermittent UVA/NB-UVB combined therapy. *Photodermatol Photoimmunol Photomed.* 2017.
7. Cao T, Yong AA, Tan KB, Tey HL. Idiopathic aquagenic pruritus: pathogenesis and effective treatment with atenolol. *Dermatol Ther.* 2015;28:118–21.
8. Murphy B, Duffin M, Tolland J. Aquagenic pruritus successfully treated with omalizumab. *Clin Exp Dermatol.* 2018;43:858–9.
9. Steinman HK, Greaves MW. Aquagenic pruritus. *J Am Acad Dermatol.* 1985;13:91–6.
10. Wallengren J, Sundler F. Phototherapy reduces the number of epidermal and CGRP-positive dermal nerve fibres. *Acta Derm Venereol.* 2004;84:111–5.

D. Morgado-Carrasco,* J. Riera-Monroig, H. Feola, P. Aguilera

Dermatology Department, Hospital Clínic de Barcelona, Universitat de Barcelona, Spain

* Corresponding author.

E-mail address: morgadodaniel8@gmail.com

(D. Morgado-Carrasco).

4 February 2019 17 February 2019

<https://doi.org/10.1016/j.adengl.2019.02.027>

1578-2190/ © 2020 AEDV. Published by Elsevier España, S.L.U. This is an open access article under the CC BY-NC-ND license (<http://creativecommons.org/licenses/by-nc-nd/4.0/>).

Whitish Dots Provide the Key to Diagnosing Condyloma Lata: A Report of 5 Cases[☆]



Puntos blanquecinos como clave diagnóstica de condilomas planos: reporte de 5 casos

To the Editor:

Syphilis, traditionally known as the *great imitator* remains among us and requires maintaining a high level of diagnostic suspicion. As well as its usual forms of clinical presentation, extremely rare skin manifestations may appear that sometimes make diagnosing this entity difficult.¹ Condyloma latum (CL) is a classic, though rare, cutaneous manifestation of secondary syphilis.² The increased incidence of syphilis may lead to an increase in the number of cases with atypical presentation,¹ such as those we describe below.

In this study, we collected all the cases of CL diagnosed in the STI unit of the dermatology department of Hospi-

tal General de Valencia, Valencia, Spain, between January 2015 and January 2019. In this period, a total of 95 cases were diagnosed, 49.5% of which (47 cases) were secondary syphilis. Of these, 11 cases (23.4%) showed CL in the anogenital region. We found CL with white spots on the surface in only 5 patients diagnosed with syphilis in this time. The characteristics of these patients are shown in [Table 1](#).

In the physical examination, the 5 patients presented a notable lesion in the perianal region ([Fig. 1](#)). This lesion was raised, with pink fleshy edges surrounding a friable erythematous center with characteristic white spots on the surface. Dermoscopy revealed a lesion with milky-red areas in the center and well-defined pearly globules in the center ([Fig. 2A](#)). In Case 1, this lesion was the patient's only clinical sign. In Cases 3 and 4, this lesion was accompanied by perianal condylomata acuminata (CA).

Biopsies were performed in 2 of the cases to confirm the diagnosis of CL. The characteristics of both samples are very similar, with a psoriasiform hyperplasia of the epidermis with marked exocytosis and formation of spongiform pustules, accompanied by a dense lymphoplasmacytic dermal infiltrate ([Fig. 2B-D](#)). Immune staining with anti-*Treponema pallidum* antibodies was positive in both patients.

In the 2 patients with suspected coinfection with the human papillomavirus (HPV), samples were taken for histopathology and genotyping of the virus. One of the patients developed epidermoid carcinoma of the anal canal.

[☆] Please cite this article as: Magdaleno-Tapiál J, Hernández-Bel P, Valenzuela-Oñate C, Alegre-de Miquel V. Puntos blanquecinos como clave diagnóstica de condilomas planos: reporte de 5 casos. *Actas Dermosifiliogr.* 2020;111:892–895.

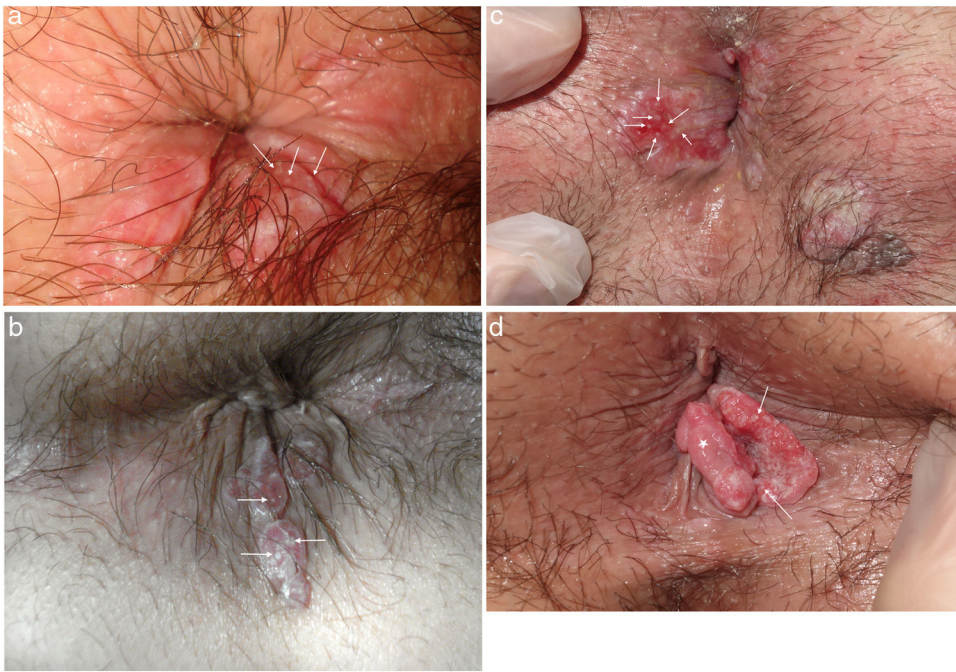


Figure 1 Condylomata lata of the 4 patients who showed white spots in the central area of the lesion.

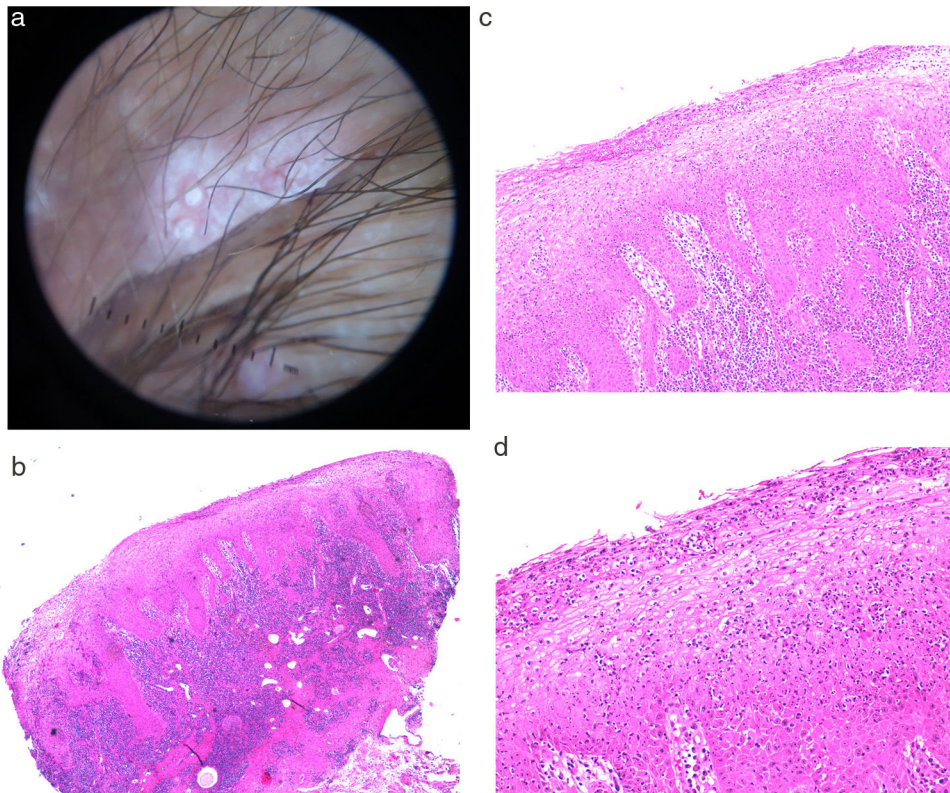


Figure 2 A, Dermoscopy of the condyloma latum lesion of Case 5, showing 2 rounded white spots with well-defined edges, on a milky-red central area. B, Histology of a condyloma latum lesion showing a psoriasiform hyperplasia of the epidermis with marked exocytosis and formation of neutrophilic spongiform pustules, accompanied by a dense lymphoplasmacytic dermal infiltrate.

Another patient developed perianal CA after a year of follow-up.

CL is a rare pseudotumoral manifestation of secondary syphilis, with an incidence of between 5% and 22%, depend-

ing on the series.³ In our series, the incidence of CL was 23% of patients diagnosed with secondary syphilis, in relation to studies published in the literature. In other series, prevalence may reach 50%.⁴ These lesions are typically defined as

Table 1 Clinical and Epidemiologic Characteristics of the Study Patients.

Patient	Age, Y/Sex	Previous Diagnosis	Sexual Orientation	Previous STIs	Associated Clinical Presentation	RPR on Diagnosis	TP PCR	HPV Genotypes	Treatment	Clinical Course
1 (Fig. 1A).	27/male	CA	MSM	—	—	1/8	Not performed	—	Penicillin G benzathine 2.4 × 10 ⁶ IU	RPR 1/1. Clinical cure
2 (Fig. 1B).	24/male	CA	MSM	—	Evanescent maculopapular rash, depapillated tongue, swollen lymph nodes in the groin	1/32	Positive	HPV 6 in anal swab (after 1 year of follow-up, patient developed perianal condylomata acuminata)	Penicillin G benzathine 2.4 × 10 ⁶ IU	RPR negative. Clinical cure
3 (Fig. 1C).	36/male	CA	MSM	HIV, condylomata acuminata	Perianal CA	1/64	Positive	HPV 6 (in condyloma acuminatum lesion)	Penicillin G benzathine 2.4 × 10 ⁶ IU/3 doses	RPR negative. Clinical cure
4 (Fig. 1D).	39/male	CA	MSM	HIV	CA, papillomatous tumor in anal canal	1/64	Positive	HPV 16, 62, 72, 81 (epidermoid carcinoma of anal canal)	Penicillin G benzathine 2.4 × 10 ⁶ IU/3 doses	RPR negative. Clinical cure
5	29/male	Perianal genital herpes	MSM	HIV, condylomata acuminata	Maculopapular rash	1/128	Positive (also in pharyngeal exudate)	—	Penicillin G benzathine 2.4 × 10 ⁶ IU/3 doses	RPR negative. Clinical cure

Abbreviations: CA indicates condyloma acuminatum; MSM, man who has sex with men; STIs, sexually transmitted infections; PCR, polymerase chain reaction; RPR, rapid plasma reagin test; TP, *Treponema pallidum*; HIV, human immunodeficiency virus; HPV, human papillomavirus.

plaques or nodules in the anogenital region, with a smooth, flat, or papillary moist surface.⁵ Location outside the genital region has rarely been reported.^{6,7} These lesions may be verrucous or pediculated, thus mimicking other diagnoses, such as CA, Bowen disease, anal epidermoid carcinoma, hemorrhoids, or lymphogranuloma venereum.⁸

The pathogenesis of these lesions is unknown, although their location in moist areas subject to constant friction may be responsible for the transformation of syphilitic papules to CL.⁹

Our series of 5 patients is characterized by flat, raised lesions with an erythematous friable center with clinically visible disperse white spots. These spots are more evident under dermoscopy and appear pearly, rounded, and with clearly defined edges. We have found no other cases of CL that present such clinically characteristic findings. Dermoscopy of CL, however, has been described and reveals multiple small, whiteish, rounded structures in the center of the lesions.⁶

Histopathology of 2 of these lesions showed a psoriasiform hyperplasia of the epidermis with marked exocytosis and formation of spongiform pustules, accompanied by a dense lymphoplasmacytic dermal infiltrate. This is similar to cases reported in the literature.^{6,10} However, we have found no reports showing spongiform pustules in CL lesions.

Furthermore, coinfection with HPV was found in 3 of the 5 patients, 2 of them with clinical lesions of CA that even masked the CP lesion. This coinfection may be a pathogenic factor in the development of these lesions.

The statement of Sir William Osler notwithstanding, we believe that syphilis is not the only disease one needs to understand in order to become an expert dermatologist.¹ However, the fact that it can simulate any disease forces us to be cautious and to keep this diagnosis in mind, even when it begins with clinically rare manifestations. CL may occasionally be the only manifestation of the disease, and it is therefore important to retain a high degree of suspicion. In conclusion, we present the whiteish spots of syphilitic CL as a novel important clinical finding for being able to make an accurate diagnosis and prescribe appropriate treatment.

Conflicts of interest

The authors declare that they have no conflicts of interest.

References

- Hernández-Bel P, López J, Sánchez JL, Alegre V. Nodular secondary syphilis. *Actas Dermosifiliogr*. 2009;100:520–2.
- Freitas DMM, Azevedo A, Pinheiro G, Ribeiro R. Psoriasiform papules, condyloma lata, lung nodules and hepatitis: the enormous variability of secondary syphilis manifestations. *BMJ Case Rep*. 2017;5:2017.
- Mullooly C, Higgins SP. Secondary syphilis: the classical triad of skin rash, mucosal ulceration and lymphadenopathy. *Int J STD AIDS*. 2010;21:537–45. <http://dx.doi.org/10.1258/ijsa.2010.010243>.
- Sanchez MR. Syphilis. In: Fitzpatrick TB, Eisen AZ, Wolff K, editors. *Dermatology in General Medicine*. 5th ed. New York: McGraw-Hill; 1999. p. 2551–81.
- Pinto-Gouveia M, Pinho A, Reis JP. Condylomata Lata Mimicking Buschke-Löwenstein Tumor. *Acta Med Port*. 2016;29:231. <http://dx.doi.org/10.20344/amp.7101>.
- Ikeda E, Goto A, Suzaki R, Sawada M, Dekio I, Ishizaki S, et al. Condylomata lata on the ankle: an unusual location. *Dermatol Pract Concept*. 2016;6:49–51.
- Liu Z, Wang L, Zhang G, Long H. Warty mucosal lesions: Oral condyloma lata of secondary syphilis. *Indian J Dermatol Venereol Leprol*. 2017;83:277. <http://dx.doi.org/10.4103/0378-6323.191129>.
- Tayal S, Shaban F, Dasgupta K, Tabaqchali MA. A case of syphilitic anal condylomata lata mimicking malignancy. *Int J Surg Case Rep*. 2015;17:69–71. <http://dx.doi.org/10.1016/j.ijscr.2015.10.035>.
- De la Bretèque MA, Sigal ML, Bilan P, Wann AR, Mahé E. Condyloma lata] *Presse Med*. 2015;44:853–4. <http://dx.doi.org/10.1016/j.lpm.2015.04.024>.
- Deshpande DJ, Nayak CS, Mishra SN, Dhurat RS. Verrucous condyloma lata mimicking condyloma acuminata: An unusual presentation. *Indian J Sex Transm Dis*. 2009;30:100–2.

J. Magdaleno-Tapial, P. Hernández-Bel,* C. Valenzuela-Oñate, V. Alegre-de Miquel

Servicio de Dermatología, Hospital General Universitario de Valencia, Valencia, Spain

*Corresponding author.

E-mail address: pablohernandezbel@hotmail.com

(P. Hernández-Bel).

6 February 2019 24 February 2019

<https://doi.org/10.1016/j.adengl.2020.10.028>

1578-2190/ © 2020 Published by Elsevier España, S.L.U. on behalf of AEDV. This is an open access article under the CC BY-NC-ND license (<http://creativecommons.org/licenses/by-nc-nd/4.0/>).