




# ACTAS Derma-Sifiliográficas

Full English text available at  
www.actasdermo.org



## CASE AND RESEARCH LETTERS

### Cutaneous Plasmacytosis: A Rare Diagnosis to Bear in Mind<sup>☆</sup>



#### Plasmacitosis cutánea: una infrecuente enfermedad cutánea a tener en cuenta

To the Editor:

A 62-year-old man presented with asymptomatic skin lesions that were located exclusively on the thorax and had appeared more than 15 years earlier. The patient had no relevant medical or surgical history and was not taking regular medication. Physical examination revealed erythematous-brownish plaques without scaling or infiltration (Fig. 1A). The palms of the hands, soles of the feet, and the mucous membranes were free of any lesions. Darier sign was negative and neither lymphadenopathy nor organomegaly were evident on palpation.

Although clinically the patient's lesions could be considered compatible with mastocytosis, the duration of the lesions and the absence of Darier sign were striking. The clinical stability of the lesions over several years and the absence of palmoplantar involvement decreased the likelihood of secondary syphilis.

Results of laboratory tests revealed a normal biochemical profile and a normal complete blood count. The only findings of interest were polyclonal hypergammaglobulinemia with a slight increase in immunoglobulin (Ig) G and IgA, and an increase in acute phase reactants (erythrocyte sedimentation rate [ESR] and C-reactive protein [CRP]). Autoimmunity markers were negative and no alterations in urine sediment were observed.

A punch biopsy of one of the chest lesions showed superficial and deep infiltrate with perivascular and periadnexal involvement (Fig. 2A), as well as perineural involvement (Fig. 2B). Observation at higher magnification revealed that the infiltrate consisted of plasma cells (Fig. 2C). Immunohistochemistry showed positive staining for  $\kappa$  and  $\lambda$  Ig light chains (Fig. 3), with no light chain restriction. Based on these observations, the differential diagnosis included other entities characterized by plasma-cell-rich infiltrate including infectious diseases (e.g. syphilis, leishmaniasis), autoimmune diseases (e.g. lupus), and neoplastic diseases (e.g. plasmacytoma). Syphilis serology was neg-

ative. The hematology department performed peripheral blood tests, which showed no alterations in white blood cells or in the proteinogram. In the absence of any clinicopathologic correlation or signs of hematological disease, and given the negative syphilis serology and the presence of plasma-cell-rich infiltrate, a diagnosis of cutaneous plasmacytosis was established based on the pathological findings. In accordance with the recommendations of the hematology department, no extension study was carried out owing to the duration of the lesions and the absence of systemic signs, lymphadenopathy, organomegaly, or laboratory abnormalities.

### Discussion

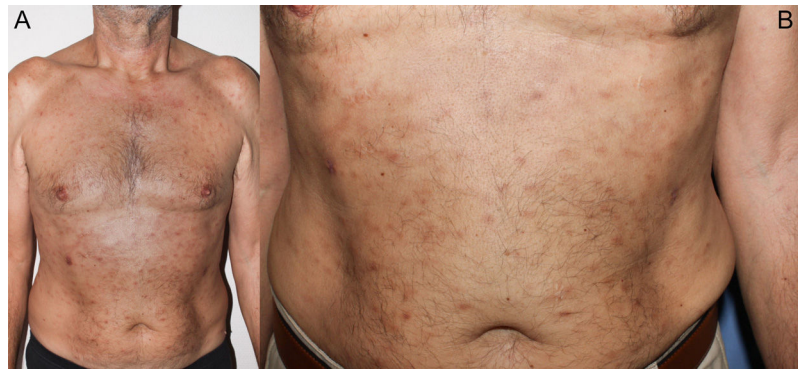Cutaneous plasmacytosis is extremely rare and usually appears in middle-aged adults, predominantly affecting Asian (mainly Japanese) patients and rarely white patients.<sup>1,2</sup> This disease is rarely reported in the literature, and may be underdiagnosed due to differences in nomenclature; it was not until 1980<sup>3</sup> that the term cutaneous plasmacytosis was coined. Some authors prefer the term systemic cutaneous plasmacytosis, as lymphadenopathy and/or organomegaly have been reported in some patients, and even in patients without such alterations plasmacytic infiltrate has been detected in biopsies of apparently clinically normal lymph nodes.<sup>1-4</sup>

Laboratory analyses typically reveal polyclonal hypergammaglobulinemia, which is usually, as in the present case, due to alterations in IgG and IgA, as well as increased levels of acute phase reactants such as ESR and CRP, with no alterations in biochemical parameters or in the complete blood count.

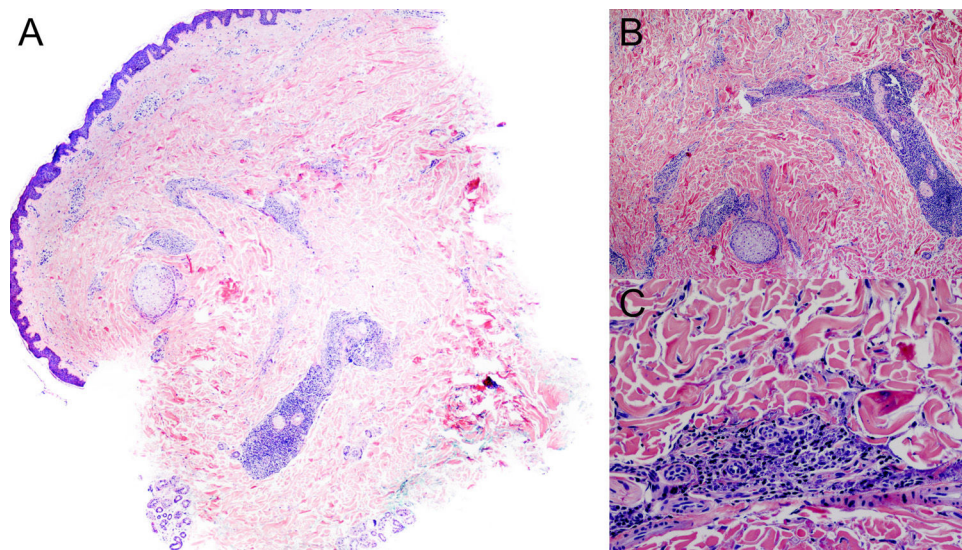
Histology shows superficial and deep perivascular and periadnexal plasma cell infiltrate, without light chain restriction (i.e. expressing  $\kappa$  and  $\lambda$  light chains), which indicates a polyclonal process.<sup>5</sup> Characteristic perineural involvement has also been described in some cases, including in our patient.<sup>6</sup>

As also proposed for other hematological processes, some authors have suggested a relationship between cutaneous plasmacytosis and Epstein Barr virus or *Borrelia* infection, although this has not been demonstrated in the few series published to date.<sup>1,5,6</sup>

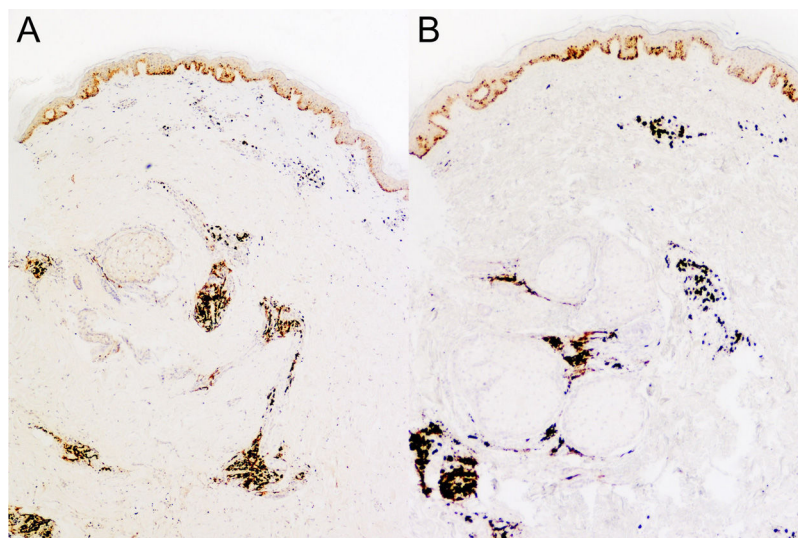
<sup>☆</sup> Please cite this article as: Álvarez-Chinchilla PJ, Scheneller-Pavelescu L, Niveiro M, Devesa P. Plasmacitosis cutánea: una infrecuente enfermedad cutánea a tener en cuenta. Actas Dermosifiliogr. 2020;111:877–879.



**Figure 1** Clinical image. Erythematous and brown papules on both sides of the patient's trunk.



**Figure 2** Pathology images. A, Panoramic image showing superficial and deep perivascular and periadnexal infiltrate (hematoxylin-eosin [HE], original magnification  $\times 20$ ). B, Higher magnification image showing perineural infiltrate (HE, original magnification  $\times 40$ ). C, Detail of the inflammatory infiltrate, which consists of plasma cells.



**Figure 3** Immunohistochemistry images showing positive staining for  $\kappa$  (A) and  $\lambda$  (B) immunoglobulin light chains.

There is also some controversy as to whether this process is associated with hematologic neoplasms or other reactive plasmacytic processes, such as Castleman disease, although current knowledge suggests that these processes are independent.<sup>5</sup>

Owing to the rare nature of this condition, there are neither guidelines nor consensus on the treatment of affected patients. Of the several treatments tested, most have been only partially effective, including oral and topical corticosteroids, topical calcineurin inhibitors, melphalan, immunoglobulins, rituximab and thalidomine, and phototherapy (psoralen and ultraviolet [UV] A and narrowband UVB therapy).<sup>1,6,7</sup>

In conclusion, cutaneous plasmacytosis is uncommon in white individuals, and usually has a chronic and benign long-term course. Nonetheless, follow-up of these patients is recommended owing to the scarcity of information about this pathological process.<sup>6</sup>

### Conflicts of interest

The authors declare that they have no conflicts of interest.

### References

1. Honda R, Cerroni L, Tanikawa A, Ebihara T, Amagai M, Ishiko A. Cutaneous plasmacytosis: Report of 6 cases with or without systemic involvement. *J Am Acad Dermatol*. 2013;68:978–85.
2. López-Gómez A, Salas-García T, Ramírez-Andreo A, Poblet-Martínez E. Cutaneous plasmacytosis in a white man. *Actas Dermosifiliogr*. 2015;106:520–2.
3. Kitamura K, Tamura N, Hatano H, Toyama K, Mikata A, Watanabe S. A case of plasmacytosis with multiple peculiar eruptions. *J Dermatol*. 1980;7:341–9.
4. Watanabe S, Ohara K, Kukita A, Mori S. Systemic plasmacytosis. A syndrome of peculiar multiple skin eruptions, generalized lymphadenopathy, and polyclonal hypergammaglobulinemia. *Arch Dermatol*. 1986;122:1314–20.
5. Wagner G, Rose C, Klapper W, Sachse MM. Cutaneous and systemic plasmacytosis. *J Dtsch Dermatol Ges*. 2013;11:1161–7.
6. Han XD, Lee SSJ, Tan SH, Chong WS, Ng SK, Ooi MGM, et al. Cutaneous plasmacytosis: A clinicopathologic study of a series of cases and their treatment outcomes. *Am J Dermatopathol*. 2018;40:36–42.
7. Yanaba K, Kajii T, Matsuzaki H, Umezawa Y, Nakagawa H. Cutaneous plasmacytosis successfully treated with narrowband ultraviolet B irradiation therapy. *J Dermatol*. 2016;43:229–30.

P.J. Álvarez-Chinchilla,<sup>a,\*</sup> L. Scheneller-Pavelescu,<sup>a</sup>  
M. Niveiro,<sup>b</sup> P. Devesa<sup>a</sup>

<sup>a</sup> Servicio de Dermatología, Hospital General Universitario de Alicante, Alicante, Spain

<sup>b</sup> Servicio de Anatomía Patológica, Hospital General Universitario de Alicante, Alicante, Spain

\*Corresponding author.

E-mail address: [pedroalvarezchinchilla@gmail.com](mailto:pedroalvarezchinchilla@gmail.com)

(P.J. Álvarez-Chinchilla).

<https://doi.org/10.1016/j.adengl.2020.10.020>

1578-2190/ © 2020 AEDV. Published by Elsevier España, S.L.U. This is an open access article under the CC BY-NC-ND license (<http://creativecommons.org/licenses/by-nc-nd/4.0/>).

## Systemic steroids in the management of moderate-to-severe hidradenitis suppurativa<sup>☆</sup>



### Uso de los corticoides sistémicos en el tratamiento de la hidradenitis supurativa moderada-grave

To the Editor:

Hidradenitis Suppurativa (HS) is a debilitating chronic inflammatory disease of the apocrine gland-bearing skin, for which effective medical treatment remains elusive. Sev-

eral immunological derangements are now identified in the disease.<sup>1</sup> Adalimumab is so far the sole European Medicines Agency approved drug. It shows encouraging, albeit suboptimal results.<sup>2</sup> More immunosuppressants are in the pipeline. Despite this shift towards anti-inflammatory therapies in HS, evidence is scarce regarding the use of systemic steroids (SS), with only a limited number of case reports<sup>3–5</sup> and series<sup>6,7</sup> available. We aimed to evaluate SS as adjuncts to other medical therapies in HS.

A retrospective cohort study was conducted. The setting was an Adnexal Skin Diseases Clinic in a tertiary Dermatology department in Lisbon. Data was captured by searching the electronic and written medical records of the clinic. Patients were eligible if they had moderate or severe HS, as defined by the International HS Severity Score (IHS4), treated with SS at least in one occasion. Primary endpoint was a clinical response as defined by the HS Clinical Response Score (HiSCR).<sup>8</sup> Changes in patient-reported outcomes (Dermatology Life Quality index – DLQI and pain Numeric Rating Scale - NRS) were also evaluated. For statistical analysis, a Wilcoxon signed-rank test at a level of significance of 0.05 was used with STATA/IC 15.1 (STATA Corp., Texas, USA).

<sup>☆</sup> Please cite this article as: Duarte B, Cunha N, Lencastre A, Cabete J. Uso de los corticoides sistémicos en el tratamiento de la hidradenitis supurativa moderada-grave. *Actas Dermosifiliogr*. 2020;111:879–883.