

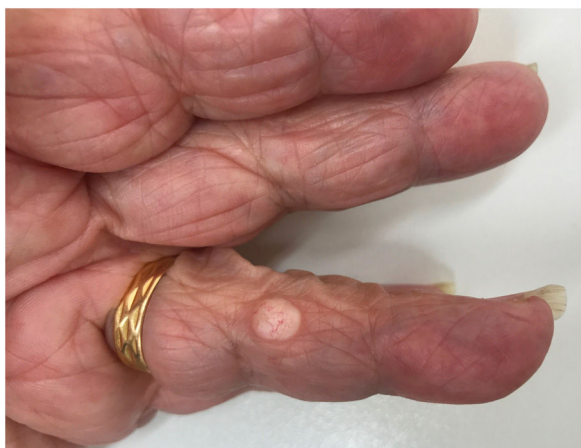## PRACTICAL DERMOSCOPY

### Solitary Sclerotic Fibroma: Dermoscopic Features<sup>☆</sup>

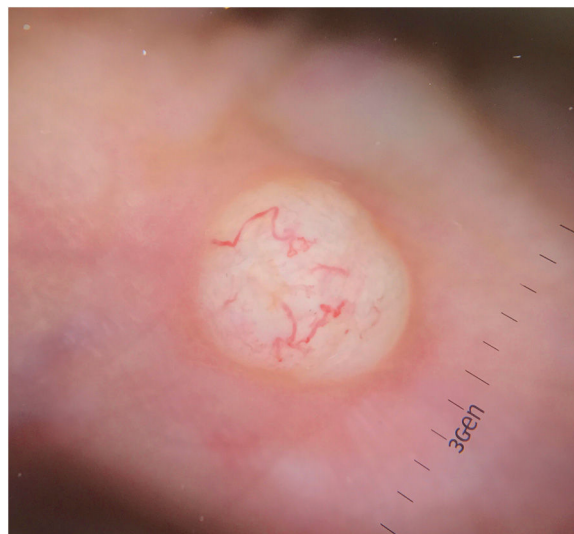

#### Fibroma esclerótico solitario: características dermatoscópicas

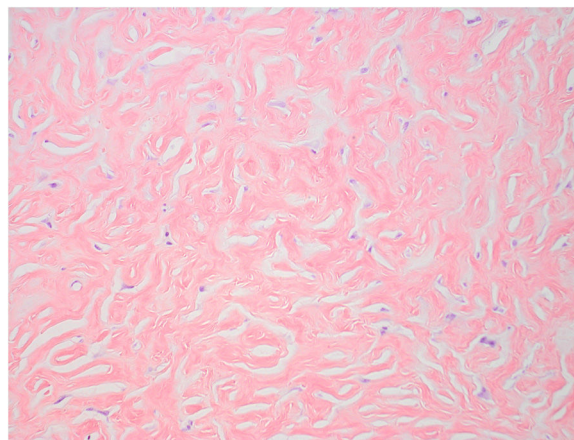
An 89-year-old woman presented with an indurated whitish nodule with superficial vascularization on the fourth finger of her left hand (Fig. 1). The lesion had been present for several years. Dermoscopy (Fig. 2) showed peripheral arborizing vessels against a whitish background and an erythematous halo around the lesion. The lesion was excised and sent for pathologic examination (Fig. 3).



**Fig. 1** Well-demarcated nodule measuring 7 × 5.7 mm with superficial vascularization.



**Fig. 2** Homogeneous white lesion with perilesional erythema and peripheral arborizing vessels.



**Fig. 3** Abundant hypocellular hyalinized bands of collagen and clefts forming a storiform pattern.

[[?]] What Is Your Diagnosis?

### Diagnosis

Solitary sclerotic fibroma.

<sup>☆</sup> Please cite this article as: Setó-Torrent N, Melé-Ninot G, Quintana-Codina M, Ballester-Victoria R. Fibroma esclerótico solitario: características dermatoscópicas. Actas Dermosifiliogr. 2020;111:774–775.

## Comment

Sclerotic fibroma (SF), also known as storiform collagenoma, is an uncommon benign tumor. It clinically manifests as a firm, solitary, well-circumscribed, whitish or flesh-colored papule or nodule and typically affects young adults.<sup>1</sup> It is preferentially located on the face and extremities, but has also been described on the trunk, scalp, oral mucosa, and nail bed.<sup>2</sup> Multiple SFs are considered to be a cutaneous marker of Cowden syndrome,<sup>1</sup> unlike solitary lesions, which are not usually observed in this hereditary skin condition. Histopathologic examination shows a well-circumscribed, nonencapsulated, dermal tumor composed of thick hypocellular hyalinized collagen bands separated by numerous clefts and scarce fibroblasts interspersed among the collagen bands. The clefts are randomly arranged and form a storiform pattern at low magnification.<sup>1</sup>

Two theories have been proposed to explain the etiology and pathogenesis of SF. According to the first theory, SF is a distinct clinical and pathologic entity, which in particular would explain its association with Cowden syndrome. According to the second theory, it would be the end stage of existing lesions, such as dermatofibromas, neurofibromas, angiofibromas, folliculitis, erythema elevatum diutinum, lipomas, fibroma of the tendon sheath, melanocytic nevi, and giant cell collagenomas. The most commonly associated entity is dermatofibroma.<sup>3,4</sup>

A recent dermoscopic study of SF, the first of its kind, described a homogeneous lesion against a white background with peripheral arborizing vessels and a perilesional erythematous halo.<sup>2</sup> Our findings were very similar. The following conditions should be contemplated in the differential diagnosis: atypical dermatofibroma, late-stage sclerotic dermatofibroma, basal cell carcinoma, hypomelanotic or amelanotic blue nevus, and amelanotic melanoma.<sup>2</sup> Unlike SF, atypical and late-stage sclerotic dermatofibromas usually have a delicate peripheral pigment network.<sup>5</sup> Additional dermoscopic features observed in basal cell carcinoma include cartwheel structures, maple leaf-like areas, ulceration, multiple globules, and blue-gray ovoid nests. Blue nevus and amelanotic melanoma do not always exhibit a residual blue-brownish pigment,<sup>6</sup> making them more difficult to distinguish from SF.

We have presented a new case of SF with very similar dermoscopic findings to those recently described. Although dermoscopy can provide important diagnostic clues, a diagnosis of SF must be histologically confirmed.

## Conflicts of Interest

The authors declare that they have no conflicts of interest.

## References

1. Izquierdo MJ, Pastor MA, Carrasco L, Requena C, Soguero ML, Moreno C, et al. Fibroma esclerótico con células gigantes multinucleadas. *Actas Dermosifiliogr*. 2001;92:419–21.
2. Ebadian M, Citarella L, Collins D, Lewisham and Greenwich NHS Trust, et al. Dermoscopy of a solitary storiform collagenoma. *Dermatol Pract Concept*. 2018;8:120–2.
3. High WA, Stewart D, Essary LR, Kageyama NP, Hoang MP, Cockerell CJ. Sclerotic fibroma-like change in various neoplastic and inflammatory skin lesions: is sclerotic fibroma a distinct entity? *J Cutan Pathol*. 2004;31:373–8.
4. Abbas O, Ghosn S, Bahhady R, Salman S. Solitary sclerotic fibroma on the scalp of a young girl: reactive sclerosis pattern? *J Dermatol*. 2010;37:575–7.
5. Coelho de Sousa V, Oliveira A. Nodular lesion with polymorphous vascular pattern. *Dermatol Pract Concept*. 2017;7:81–3.
6. Ma C, Chambers CJ, Kiuru M, Marsee DK, Silverstein M. Amelanotic blue nevus. *JAAD Case Reports*. 2017;3:93–4.

N. Setó-Torrent,<sup>a,\*</sup> G. Melé-Ninot,<sup>a</sup> M. Quintana-Codina,<sup>a</sup> R. Ballester-Victoria<sup>b</sup>

<sup>a</sup> *Servicio de Dermatología, Hospital Universitari Sagrat Cor, Barcelona, Spain*

<sup>b</sup> *Servicio de Anatomía Patológica, Hospital Universitari Sagrat Cor, Barcelona, Spain*

\* Corresponding author.

E-mail address: [nurisetorrent@gmail.com](mailto:nurisetorrent@gmail.com) (N. Setó-Torrent).

6 July 2019 21 May 2020