




ACTAS Derma-Sifiliográficas

Full English text available at
www.actasdermo.org



REVIEW

Recurrent Aphthous Stomatitis[☆]

J. Sánchez,^a C. Conejero,^b R. Conejero^{c,*}



^a Servicio de Dermatología, Hospital Clínico Universitario Lozano Blesa, Zaragoza, Spain

^b Unidad de Dermatología, Centro Médico Millenium, Zaragoza, Spain

^c Departamento de Dermatología, Hospital Royo Villanova, Zaragoza, Spain

Received 12 May 2019; accepted 25 September 2019

Available online 15 July 2020

KEYWORDS

Recurrent aphthous stomatitis;
Aphthae;
Oral ulcers;
Periodic fever syndrome

Abstract Recurrent aphthous stomatitis is a chronic inflammatory disease of the oral mucosa. It is characterized by painful mouth ulcers that cannot be explained by an underlying disease. Recurrent oral mucosal ulcers require a proper differential diagnosis to rule out other possible causes before recurrent aphthous stomatitis is diagnosed. The condition is common, with prevalence rates ranging from 5% to 60% in different series. Its pathogenesis is unknown, but multiple factors are considered to play a part. There are no standardized treatments for this condition and none of the treatments are curative. The goal of any treatment should be to alleviate pain, reduce the duration of ulcers, and prevent recurrence.

© 2020 AEDV. Published by Elsevier España, S.L.U. This is an open access article under the CC BY-NC-ND license (<http://creativecommons.org/licenses/by-nc-nd/4.0/>).

PALABRAS CLAVE

Aftosis oral recidivante;
Afta;
Úlceras orales;
Síndrome periódico;
Mucosa oral

Aftosis oral recidivante

Resumen La aftosis oral recidivante es una enfermedad inflamatoria crónica de la mucosa oral. Se caracteriza por presentar úlceras dolorosas en la cavidad oral sin que se encuentre una enfermedad subyacente que lo justifique. Ante la aparición de úlceras recidivantes en la mucosa oral habrá que realizar un correcto diagnóstico diferencial y descartar otras causas antes de llegar al diagnóstico de aftosis oral recidivante. Se trata de una enfermedad frecuente, según la población estudiada se han documentado prevalencias entre el 5 hasta el 60%. Su patogenia es desconocida pero se considera multifactorial. El tratamiento no está estandarizado, y no hay un tratamiento curativo, se pretende disminuir el dolor durante el brote, acortar la duración del mismo y evitar la aparición de nuevas lesiones.

© 2020 AEDV. Publicado por Elsevier España, S.L.U. Este es un artículo Open Access bajo la licencia CC BY-NC-ND (<http://creativecommons.org/licenses/by-nc-nd/4.0/>).

[☆] Please cite this article as: Sánchez J, Conejero C, Conejero R. Aftosis oral recidivante. Actas Dermosifiliogr. 2020;111:471–480.

* Corresponding author.

E-mail addresses: raquel.conejero@hotmail.com, rconejero@salud.aragon.es (R. Conejero).

Introduction

Recurrent aphthous stomatitis (RAS) is characterized by the appearance of painful, round, well-defined ulcers with erythematous borders and a grayish-yellow pseudomembranous base in the oral cavity of otherwise healthy patients. A burning sensation may precede the appearance of the ulcers by 2 to 48 hours.¹

Epidemiology

RAS is the most frequent cause of ulcers on the oral mucosa. It affects 5% to 25% of the general population,² although prevalence may vary from 5% to 60%³ depending on the study and on the population assessed, the diagnostic criteria applied, and environmental factors.

The peak age for onset of RAS is between 10 and 19 years, and although the condition is less frequent in adults, it may persist throughout a person's life. No sex differences in prevalence have been recorded.⁴

Pathogenesis

RAS belongs to the family of chronic inflammatory diseases of the oral mucosa. Its etiology and pathogenesis are unknown, although it is considered a multifactorial disease, and various triggers have been reported (Fig. 1). In genetically predisposed patients, the effect of specific factors is thought to initiate a proinflammatory cytokine cascade targeting specific areas of the oral mucosa.⁵

- **Genetic factors:** Heredity plays a key role in the development of RAS. The probability of having RAS increases if one or both parents have had the disease; in 24%-46% of cases, patients have a family history.^{6,7} Moreover, patients with a family history experience recurrences much more often and have a more severe clinical picture.⁸⁻¹⁰

The incidence of human leukocyte antigen (HLA) A33, HLA-B35, HLA-B81, HLA-B12, HLA-B51, HLA-DR7, and HLA-DR5 is greater in patients with RAS than in healthy controls.⁵

Genetic risk factors also modify a person's susceptibility to RAS. These include various DNA polymorphisms throughout the human genome, especially those associated with the

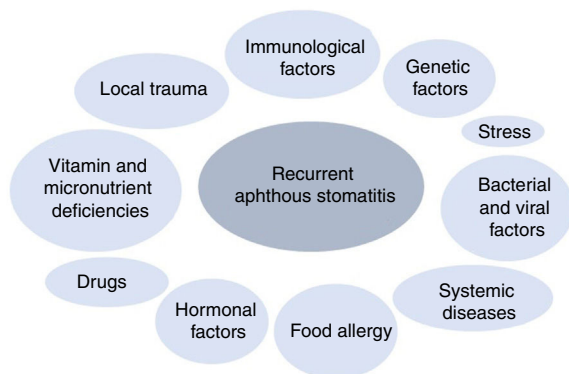


Figure 1 Factors affecting the pathogenesis of recurrent aphthous stomatitis.

metabolism of interleukins (IL) (e.g., IL- β , IL-2, IL-4, IL-5, IL-6, IL-10, and IL-12), interferon γ , and tumor necrosis factor (TNF) α .¹¹⁻²⁰

- **Local injury:** Local injury is considered a causal agent in genetically predisposed individuals^{21,22} and predisposes to RAS, with early cellular inflammation and edema, as well as increased viscosity of the extracellular matrix of the oral submucosa.²³ Not all local injuries lead to RAS, since persons who wear dentures are not at an increased risk.²⁴ Smoking has been reported to act as a protective factor with respect to RAS.^{25,26}
- **Bacterial and viral factors:** Various reports have attempted to establish an association between RAS and different microorganisms, including bacteria of the genus *Streptococcus*, especially *Streptococcus sanguinis* 2A,²⁷ *Helicobacter pylori*,²⁸ *Lactobacillus*,²⁹ and Epstein-Barr virus.³⁰ However, the results to date have not shown a clear causal relationship.
- **Stress:** Stressful life events may trigger new lesions in predisposed patients. One study concluded that mental stressors were more associated with RAS than physical stressors and that stressful life events were more associated with the onset of episodes than with the duration of the episodes.²¹ Similarly, there have been cases of diseases, such as Behçet disease, that progress with aphthous ulcers and that worsen after considerable emotional stress.³¹
- **Food allergy:** Allergy is thought to be a cause of RAS. Hypersensitivity to specific substances, oral microorganisms such as *S sanguinis*, and heat shock proteins have been proposed as causal factors, although there is no evidence to date that these are a key cause of the disease.^{32,33}
- **Vitamin and micronutrient deficiencies:** Low levels of iron, folic acid, zinc, and vitamins B₁, B₂, B₆, and B₁₂ have been reported.³⁴ Sometimes, these deficiencies are associated with underlying diseases, such as malabsorption and gluten enteropathy.
- **Immunologic factors:** In patients with RAS, the functioning of the immune system is modified in response to an as yet unknown trigger (e.g., bacterial/viral antigens and stress). Both the innate and acquired immune responses (humoral and cellular) are altered in patients with RAS. Many authors believe that the type 1 helper T (T_H1) response plays the most important role in the development of the disease.^{15,35}
- **Underlying systemic diseases:** RAS appears more frequently in patients with inflammatory bowel disease (Crohn disease and ulcerative colitis) and in celiac disease.^{6,36,37} This association could result from nutritional deficiency, which is a frequent complication of these diseases. RAS is also more frequent in patients infected with the human immunodeficiency virus, probably in association with an abnormal CD4⁺/CD8⁺ ratio and a reduced neutrophil count.^{38,39}
- **Hormonal factors:** An association has been reported between the appearance of aphthous ulcers and the menstrual cycle. Ulcers are more frequent during the luteal phase or in the menopause and less frequent during pregnancy and in women taking hormonal contraceptives.⁴⁰

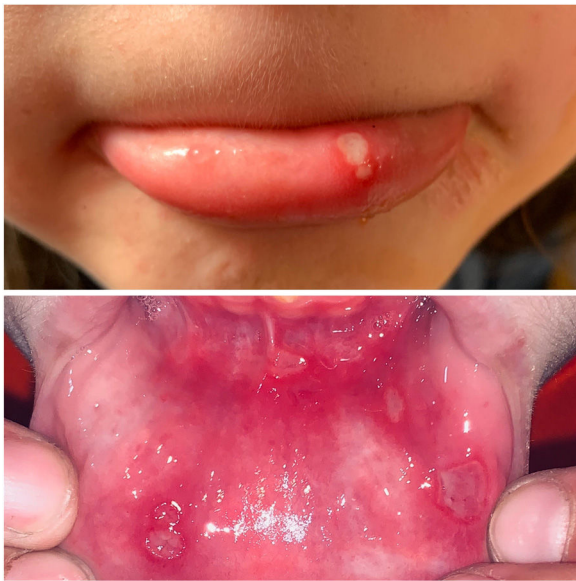

Figure 2 Image of minor ulcers on the lip and mucous membrane of the lower lip.

- **Drugs:** There are reports of oral aphthous ulcers triggered by drugs. One case-control study associated an increased risk of RAS with medication, especially nonsteroidal antiinflammatory drugs and β -blockers.⁴² Nicorandil, calcineurin, and mTOR inhibitors have also been associated with severe oral ulcers.⁴³⁻⁴⁵

Symptoms

The 3 clinical forms of RAS—major, minor, and herpetiform—differ in their morphology, distribution, severity, and prognosis. Table 1 summarizes the main differences. Despite these differences, all 3 types of RAS have a significant impact on patients’ quality of life and interfere with activities of daily living.⁴⁶ Minor RAS (Fig. 2) is the most common presentation, affecting 80% of patients. It progresses without scarring, unlike major RAS (Fig. 3), in which ulcers take longer to heal and which progresses with scarring and even residual synechiae. Herpetiform RAS is

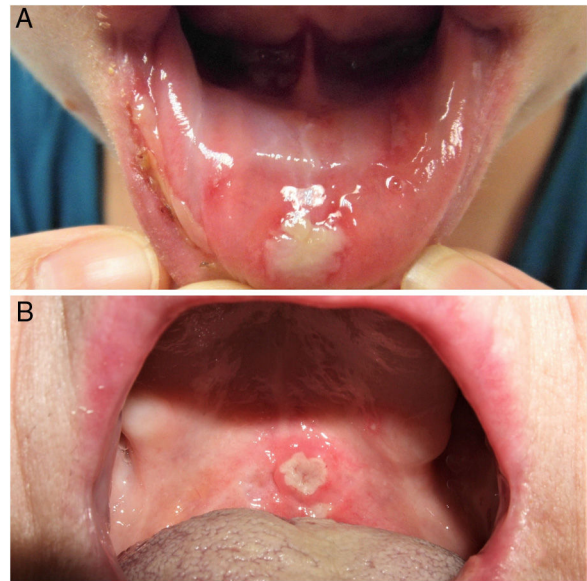


Figure 3 A, Major ulcers on the mucous membrane of the lower lip. B, Ulcer on the soft palate.

the least common type. In this case, there could be up to 100 ulcers that can coalesce, leading to larger ulcers with irregular borders.

Differential Diagnosis

Table 2 shows the main causes of acute and chronic ulcers in the oral mucosa.

Given the complex differential diagnosis of RAS, a meticulous history must be taken to correctly guide the diagnosis. Before confirming a diagnosis, we must rule out other clinical pictures in which ulcers are one of the most frequent signs (Fig. 4).

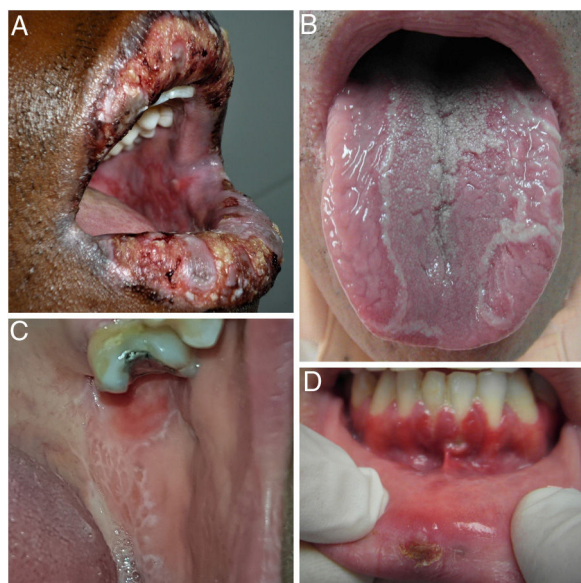
Diagnosis

Diagnosis of RAS is based on the clinical history and a physical examination. However, we must always rule out an under-

Table 1 Clinical Classification.

	Minor RAS	Major RAS	Herpetiform RAS
Gender predilection	Same in men and women	Same in men and women	More frequent in women
Size	< 10 mm	> 10 mm	2-3 mm
Number of ulcers	1-5	1-10	10-100
Morphology	Round or oval	Round or oval, crateriform	Small, deep ulcers that converge, with irregular contours
	Grayish-white pseudomembrane Erythematous halo	Grayish-white pseudomembrane Erythematous halo	
Localization	Nonkeratinized mucosa: lips, cheeks, floor of the mouth	Nonkeratinized mucosa: lips, soft palate, pharynx	Lips, cheeks, floor of the mouth, gums
Healing	Ulcers heal in 4-14 d	Heal in > 6 wk	Heal in < 30 d

Abbreviation: RAS, recurrent aphthous stomatitis.

Table 2 Differential diagnosis of acute and chronic oral ulcers.**Recurrent aphthous stomatitis***Injury: Braces, necrotizing sialometaplasia**Nutritional deficiency: iron, folic acid, zinc, B₁, B₂, B₆, and B₁₂***Infections***Viral: herpes simplex virus, Coxsackie A, herpes zoster virus, cytomegalovirus, Epstein-Barr, HIV**Bacterial: tuberculosis, syphilis**Fungal: Coccidioides immitis, Cryptococcus neoformans, Blastomyces dermatitidis**Pharmacological: fixed drug eruption, linear IgA dermatosis, drug-induced bullous pemphigoid, erythema multiforme, Stevens-Johnson syndrome, toxic epidermal necrolysis**Autoimmune diseases: Crohn disease, Behçet disease, celiac disease, systemic lupus erythematosus, erosive lichen planus, Wegener granulomatosis**Hematological: anemia, neutropenia, hypereosinophilic syndrome**Fever-associated syndrome: cyclic neutropenia, fever, Sweet syndrome, familial Mediterranean fever, hyperimmunoglobulinemia D syndrome, and periodic fever, aphthous stomatitis, pharyngitis, and adenitis (PFAPA) syndrome**Blistering diseases: pemphigus vulgaris, linear IgA disease**Hereditary diseases: bullous epidermolysis, chronic granulomatous disease**Other: mouth and genital ulcers with inflamed cartilage (MAGIC) syndrome, IgG4-related disease, tumors, smoking*Source: Scully et al.⁴¹ and Suárez-Díaz et al.⁴⁷.**Figure 4** A, Erythema multiforme major with involvement of the oral mucosa. B, Geographic tongue. C, Whitish reticular pattern in oral lichen planus. D, Primary herpes infection.

lying systemic cause when ulcers appear for the first time, especially in adults.^{47,48} Fig. 5 shows a diagnostic algorithm for patients with mouth ulcers.

The recommended additional tests include the following:

- **Blood tests:** complete blood count, iron, ferritin, folic acid, zinc, magnesium, and vitamins (B₁, B₂, B₆ y B₁₂). Testing should also include transglutaminase and endomysial antibodies to rule out celiac disease, as well as antinuclear antibodies. Furthermore, some studies have

shown an association between RAS and positive titers for antigastric parietal cell antibody, and antithyroglobulin antibody, and antithyroid microsomal antibody.⁴⁹

- **Microbiological tests:** Tzanck smear test or polymerase chain reaction assay for herpes virus and culture of fungi and bacteria.
- **Skin biopsy:** The 3 indications for a skin biopsy are as follows⁵⁰:
 - a Ulcer of unknown origin that persists for more than 2 weeks with no signs of healing.
 - b Ulcer of probable origin (after the corresponding diagnostic tests) that does not respond after 2 weeks of appropriate treatment.
 - c Ulcer brought about by a trigger(s) that does not heal within 2 weeks of these factors being ruled out.

Punch or incisional biopsy: The specimen must be taken from the border of the lesion, including the area of the ulcer and the perilesional mucosa.

Histopathology study of the ulcers: The histopathology image reveals a leukocytic infiltration, which may vary depending on the duration and severity of the disease. In the initial phases, which precede formation of the ulcers, we mainly see an inflammatory infiltrate comprising T lymphocytes and monocytes. We can also see isolated mast cells and plasma cells, which accumulate below the basal layer. More advanced stages are characterized by a predominance of polymorphonuclear leukocytes in the center of the ulcer and mononuclear cells on the periphery.⁵ Consistent with Poulter and Lehner,⁵¹ this type of inflammation is not specific of RAS and can be seen in other ulcers such as erythema multiforme, Behçet disease, lupus erythematosus, and traumatic ulcers.

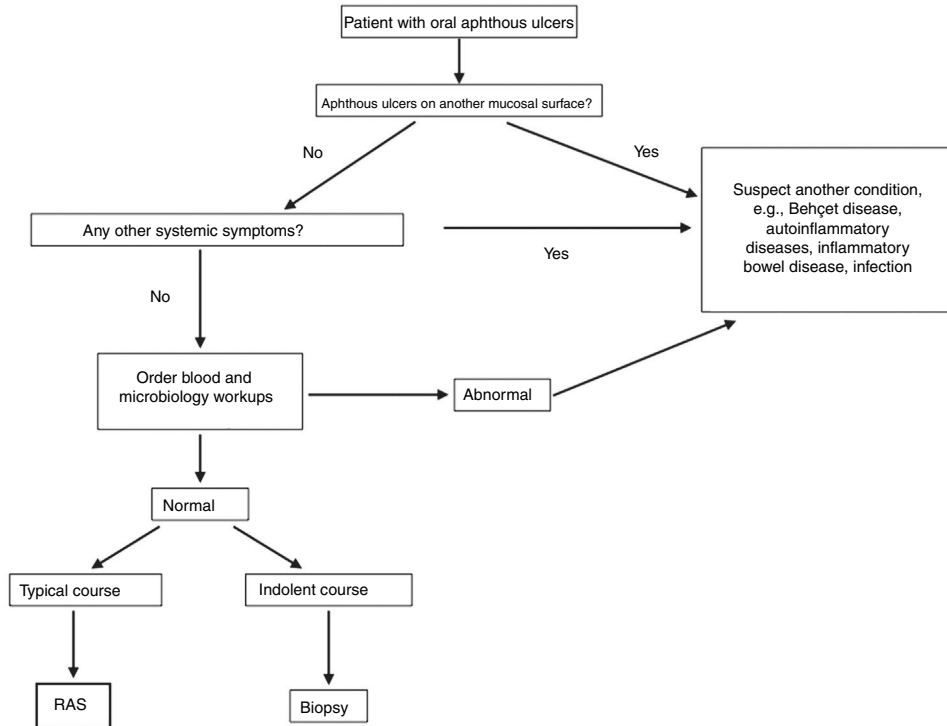


Figure 5 Diagnostic algorithm for the management of patients with aphthous ulcers. RAS indicates recurrent oral stomatitis.

Treatment

No definitive curative treatment for RAS has been established to date. Therefore, the primary objectives of treatment are to relieve pain, accelerate healing, and reduce the frequency and severity of episodes of RAS.⁵²

As mentioned above, recurrent ulcers on the oral mucosa require a correct differential diagnosis. We must also rule out associated systemic diseases and other treatable causes before making a diagnosis of RAS and considering treatment.

The approach to therapy should be based on the severity of symptoms, the frequency and duration of the outbreaks, the clinical history, and the patient’s ability to tolerate medication. Patients with isolated episodes of simple RAS that last only a few days require no more than topical treatments for relief of pain and a series of general measures, mainly good oral hygiene. Systemic therapy is indicated in patients who experience multiple episodes of RAS and/or severe cases that involve intense pain and difficulty eating and do not respond to topical medication.^{52,53}

Despite the frequency of this condition, few high-quality studies have appropriately evaluated treatment of RAS. Therefore, there is no standard therapy.⁵² The multiple topical and systemic treatments used have had varying degrees of success.

General Measures

Oral hygiene: It is important to ensure appropriate oral hygiene and to avoid injury, since this leads to mouth

ulcers.^{31,54} We recommend using a soft toothbrush, toothpaste that does not contain sodium lauryl sulfate (grade of recommendation [GR], A; level of evidence [LE], 1B),^{55,56} and an alcohol-free mouthwash.^{31,55,57}

Eating: No relevant studies have appropriately addressed the role of diet in the management of RAS. In general, we should try to avoid products that are frequently associated with triggering flare-ups, especially if the patient reports an association with the products.^{54,57}

Supplements: It is necessary to rule out nutritional deficiencies (e.g., vitamin B₁₂, folic acid, iron, zinc) in patients with RAS, since in these cases, patients improve when they receive appropriate treatment (GR, C; LE, 4). Furthermore, one study showed that sublingual vitamin B₁₂ at 1000 µg/d for 6 months could reduce the number of flare-ups and relieve pain in all patients with RAS independently of previous levels (GR, B; LE, 2B).^{56–58} Other studies have shown an improvement with ω-3 at 1000 mg/d for 6 months (GR, B; LE, 2B).⁵⁹ In contrast, supplements with other vitamin complexes in patients without nutritional deficiency have not led to an improvement in symptoms or a reduction in the number of lesions (GR, B; LE, 2B).^{52,57,59,60}

Topical Treatments

Topical anesthetics and barrier agents: These agents provide pain relief. They should be applied several times per day, preferably half an hour before meals and before teeth cleaning in order to facilitate their action and at bedtime. They can be used in combination with other treatments such

as topical corticosteroids or amlexanox. The main protective and anesthetic agents include the following:

- Lidocaine cream 1%, gel 2%, and spray: these are applied directly on the surface of the ulcers or in the form of mouthwashes (GR, B; LE, 2A).⁶⁰
- Benzocaine gel 20%: local anesthetic that relieves pain and reduces inflammation (GR, B; LE, 2A).⁶¹
- Sucralfate suspension: a complex of aluminum hydroxide and sucrose sulfate complex that forms a protective barrier against ulcers. Several studies recommend mouth washing with 5 mL for 1-2 minutes 4 times daily (after teeth cleaning and at bedtime). This substance relieves pain, speeds up healing, and lengthens the interval between flare-ups (GR, B; LE, 2A).^{62,63}

Topical antiinflammatory and antiseptic agents: These help to prevent superinfection by bacteria and fungi and improve oral hygiene.

- Triclosan 0.15% in ethanol and zinc sulfate: Administered as 3 mouthwashes per day, this agent reduces the number of ulcers and the intensity of pain and increases the ulcer-free interval (GR, A; LE, 1B).⁶³
- Chlorhexidine 0.12%-0.2% in oral solution: 5 mL in rinses for 1-2 minutes 4 times daily (after teeth cleaning and at bedtime).⁶⁰ Some studies report it to be less efficacious than sucralfate suspension (GR, B; LE, 2B).⁶²
- Diclofenac 3% in hyaluronic acid gel 2.5%: This agent proved superior to lidocaine in gel for reducing pain after 2-6 hours (GR, B; LE, 2A).^{60,63}

Topical corticosteroids: These are the first-line agents for RAS⁶⁰ and can be combined with topical anesthetics, anti-septics, and barrier agents. They provide pain relief and reduce the duration and frequency of flare-ups, although they take several days to exert an effect. They are more effective if used from the onset of the episode and are applied several times per day, preferably after teeth cleaning and at bedtime. The patient should be advised not to eat at least during the following half hour.^{62,64} The available options are as follows:

- Triamcinolone acetonide 0.1% in Orabase: This is applied on the lesions 3-4 times per day. It has proven to be a safe and effective treatment (GR, B; LE, 2B).⁶⁰
- Dexamethasone solution (0.5 mg/5 cc) or ointment: Rinsing every 5 minutes, 3-4 times per day or applying the ointment on the ulcers 3 times per day has proven to be effective and safe (GR, A; LE, 1B).^{59,64}
- Clobetasol 0.05% in gel, ointment, or Orabase: The agent is applied to the lesions 2-3 times per day. As this is the most potent corticosteroid, it is reserved for the most severe cases.⁶⁰

Amlexanox 5%: Topical inflammatory agent that, when applied on the lesions in the form of a 5% paste 4 times per day (after meals and at bedtime) has proven to be effective for the management of pain and for speeding up healing in several studies (GR, B; LE, 2B).^{52,56,61,65} Amlexanox 5% is one

of the most cost-effective topical treatments, together with triamcinolone acetonide.⁶¹

Cauterization: Applied with hydrogen peroxide 0.5% solution or silver nitrate 1%-2%, this approach reduces pain and speeds up healing (GR, B; LE, 2B).^{56,57}

Other topical treatments: Many other topical treatments have been used, including tetracyclines in mouthwash, doxycycline in denture adhesive, nicotine gum, liquid diphenhydramine mouthwash, or camel thorn distillate, most of which have been reported in poor-quality studies, with disparate results and no evidence to recommend their use.^{52,57,66,67}

Systemic Treatments

Patients who experience severe and/or frequent episodes of RAS that are refractory to general care and to topical treatments (see above) should consider adding a systemic treatment. This is selected based on the severity of symptoms, comorbid conditions, and the patient's tolerance and preferences.

First-Line

Oral corticosteroids: Oral corticosteroids have been used effectively in long regimens at lower doses, for example, oral prednisone at 5 mg/d for 3 months (GR, B; LE, 2A),⁶⁷ and in shorter regimens, with doses of 20 to 40 mg/d for 4-7 days, with subsequent gradual reduction of the dose. This leads to relief of pain, faster healing, and a reduction in the number of episodes (GR, B; LE, 2A).^{52,54,56,57}

Second-Line

Alternative systemic agents should be considered in patients who do not respond to intermittent therapy with systemic corticosteroids, patients who require frequent or longer courses of corticosteroids, and patients who cannot undergo treatment with corticosteroids for other reasons.

Colchicine: Colchicine is an antimitotic drug with specific immunomodulatory and antifibrotic effects. It has been used at 0.5 to 2 mg/d, with various results.^{52,56,57} In some publications, it is considered a systemic drug of choice at doses of 1-2 mg/d over long periods, depending on the severity of symptoms and tolerance.^{56,57,68} In contrast, after an analysis of published studies, the 2012 Cochrane review⁵² concluded that this drug was not useful in comparison with oral corticosteroids for the treatment of RAS, since its efficacy rates are equal to or lower than those of corticosteroids, although it has a greater rate of adverse effects (mainly affecting the gastrointestinal tract) (GR, B; LE, 2A).^{52,69,70}

Thalidomide: Thalidomide has been used at 50 to 100 mg/d for several months with good results.^{56,57,70} A study performed in Brazil showed it to be more effective and better tolerated than dapsone, colchicine, and pentoxifyllin.⁷¹ We must remember that this drug is teratogenic and can cause sleepiness, paresthesia, and irreversible peripheral neuropathy. Therefore, patients should be care-

fully selected and informed. It is also advisable to take a history and perform an examination at all follow-up visits to rule out signs of peripheral neuropathy. If this condition is suspected, treatment should be discontinued and an electromyogram ordered (GR, B; LE, 2B).^{56,57,70}

Dapsone: Dapsone reduces the number and size of the ulcers.⁶³ It is usually started at 25-50 mg/d, increasing to a maximum of 150 mg/d depending on the response and on tolerance. Glucose-6-phosphate dehydrogenase should be determined before starting therapy with dapsone (GR, B; LE, 2A).^{60,67}

Montelukast: Montelukast is a leukotriene inhibitor that, in some trials, has been shown to improve pain and accelerate healing of mouth ulcers, as well as reduce the appearance of new lesions with a dose of 10 mg/d for 1 month, followed by 10 mg every 2 days for a further month.⁷² Montelukast is less efficacious than prednisone, although it has fewer adverse effects and is very well tolerated. Therefore, it could prove to be a good option for long-term treatment (GR, B; LE, 2B).^{52,56,72}

Clofazimine: Clofazimine is an antimicrobial agent that has been used at 100 mg/d for 30 days followed by 100 mg every other day for 6 months. In a study with a high risk of bias, it improved symptoms and reduced the number of flare-ups compared with colchicine (GR, B; LE, 2B).^{52,69}

β -Glucans: β -Glucans comprise a group of polysaccharides found in some bacteria, plants, and fungi. They have been used at doses of 10 mg of 1,3-1,6 β -glucan twice daily, with an improvement in the severity of the ulcer compared with placebo.^{52,73} Evidence in favor of or against this approach in RAS is insufficient (GR, B; LE, 2B).⁵²

Pentoxifylline: This nonselective phosphodiesterase inhibitor with hemorheological properties specifically inhibits production of TNF- α and possibly production of some other type 1 helper T cells and proinflammatory cytokines such as IL-1 β , which are thought to play an important role in the development of RAS. Pentoxifylline has been used at 400 mg/8 h, with improvement of the lesions, although these recur when the drug is discontinued. Evidence in favor or against its use is insufficient (GR, B; LE, 2A).^{52,63}

Levamisole: Levamisole is an anthelmintic and immunomodulatory agent.⁶⁰ Results from trials with doses of 50 mg/8 h for 3 to 11 days per flare-up for at least 6 months show disparate efficacy outcomes, with insufficient evidence in favor of or against its use (GR, B; LE, 2A).^{52,62}

Doxycycline: Doxycycline at 20 mg/12 h revealed no differences with respect to placebo in a study with a high risk of bias (GR, B; LE, 2A).⁵²

Biological Treatments

Anti-TNF- α : Data from case series show that anti-TNF α agents (etanercept, adalimumab, infliximab, and golimumab) have been used successfully for treatment of severe and recalcitrant RAS.^{62,74} This seems to be a specific class

effect, with no significant differences between the anti-TNF agents used. Furthermore, it seems that failure with any of these drugs does not imply the lack of a response to other anti-TNF agents (GR, C; LE, 4).^{62,74} These drugs should be chosen based on disease severity, efficacy, potential adverse effects, and costs.

Other Treatments

CO₂, Nd:YAG, and diode laser: Some studies showed that laser therapy had similar or superior efficacy to topical corticosteroids,⁶⁷ with immediate relief of pain and accelerated healing of the ulcers (GR, B; LE, 2A).^{53,57,75}

Apremilast: Apremilast is an oral phosphodiesterase-4 inhibitor. In one published case of major RAS that was refractory to multiple topical and systemic treatments, 6 weeks' treatment with apremilast (loading dose of 10 mg/d increasing progressively to 30 mg/12 h) led to complete resolution of the lesions, with no recurrences after 1 year of treatment (GR, C; LE, 4).⁷⁶

Bee propolis: This resinous material is produced by bees and is obtained from the buds of poplars and conifers. One study with a high risk of bias showed that a daily capsule of 500 mg taken over 6 months led to a reduction in the number of outbreaks. However, evidence was insufficient to recommend or not recommend its use (GR, B; LE, 2A).^{52,77}

Homeopathy: One study with a high risk of bias concluded that homeopathy could improve pain and accelerate the cure of ulcers, without there being sufficient evidence for recommending or not recommending its use (GR, B; LE, 2A).^{52,78}

Traditional Chinese medicine: Some traditional therapies have been used for hundreds of years. A recent review tried to evaluate the scientific aspects of this approach by evaluating several of the treatments used, such as Liuwei Dihuang pills (composed of *Cornus officinalis*, *Rehmannia glutinosa*, *Rhizoma dioscoreae*, *Cortex moutan radicis*, *Poria cocos*, and *Alisma plantago-aquatica*), bergamot, Qing Wei powder, and Yiqing capsules. The authors concluded that some treatments in traditional Chinese medicine may be effective and safe for the treatment of RAS, although high-quality studies would be necessary to confirm these findings. Evidence to recommend their use is insufficient (GR, B; LE, 2B).⁷⁹

Several publications address the drugs used in the treatment of oral aphthous ulcers that manifest in systemic diseases, such as Behçet disease, but not in RAS per se. These include azathioprine, methotrexate, ciclosporin, and interferon- α . Given that neither their efficacy with respect to the etiology and pathogenesis of aphthous ulcers nor their role in RAS has been studied, we decided not to include these drugs in order to avoid confusion.⁸⁰⁻⁸³

Conflicts of interest

The authors declare that they have no conflicts of interest.

References

- Porter SR, Scully C, Pedersen A. Recurrent aphthous stomatitis. *Crit Rev Oral Biol Med*. 1998;9:306–21.
- Slebioda Z, Szponar E, Kowalska A. Recurrent aphthous stomatitis: genetic aspects of etiology. *Postepy Dermatol Alergol*. 2013;30:96–102.
- Jurge S, Kuffer R, Scully C, Porter SR. Mucosal disease series. Number VI. Recurrent aphthous stomatitis. *Oral Diseases*. 2006;12:1–21.
- Ship JA, Chavez EM, Doerr PA, Henson BS, Sarmadi M. Recurrent aphthous stomatitis. *Quintessence Int*. 2000;31:95–112.
- Slebioda Z, Szponar E, Kowalska A. Etiopathogenesis of recurrent aphthous stomatitis and the role of immunologic aspects: literature review. *Arch Immunol Ther Exp*. 2014;62:205–15.
- Scully C, Porter S. Oral mucosal disease: recurrent aphthous stomatitis. *Br J Oral Maxillofac Surg*. 2008;46:198–206.
- Rogers RS 3rd. Recurrent aphthous stomatitis: clinical characteristics and associated systemic disorders. *Semin Cutan Med Surg*. 1997;16:278–83.
- Almoznino G, Zini A, Mizrahi Y. Elevated serum IgE in recurrent aphthous stomatitis and associations with disease characteristics. *Oral Dis*. 2014;20:386–94.
- Lehner T. Immunological aspects of recurrent oral ulceration and Behçet's syndrome. *J Oral Pathol*. 1978;7:424–30.
- Yilmaz S, Cimen KA. Familial Behçet's disease. *Rheumatol Int*. 2010;30:1107–9.
- Akman A, Sallakci N, Coskun M, Bacanlı A, Yavuzer U, Alpsoy E, et al. TNF- α gene 1031 T/C polymorphism in Turkish patients with Behçet's disease. *Br J Dermatol*. 2006;155:350–6.
- Akman A, Ekinci NC, Karcaroğlu H, Yavuzer U, Alpsoy E, Yegin O. Relationship between periodontal findings and specific polymorphisms of interleukin-1 α and -1 β in Turkish patients with Behçet's disease. *Arch Dermatol Res*. 2008;300:19–26.
- Bazrafshani MR, Hajeer AH, Ollier WE, Thornhill MH. IL-1 β and IL-6 gene polymorphisms encode significant risk for the development of recurrent aphthous stomatitis (RAS). *Genes Immun*. 2002;3:302–5.
- Bazrafshani MR, Hajeer AH, Ollier WE, Thornhill MH. Polymorphisms in the IL-10 and IL-12 gene cluster and risk of developing recurrent aphthous stomatitis. *Oral Dis*. 2003;9:287–91.
- Buño IJ, Huff C, Weston WL, Cook DT, Brice SL. Elevated levels of interferon gamma, tumor necrosis factor α , interleukins 2, 4, and 5, but not interleukin 10, are present in recurrent aphthous stomatitis. *Arch Dermatol*. 1998;134:827–31.
- Guimarães AL, de Sá AR, Victória JM, Correia-Silva JF, Pessoa PS, Diniz MG, et al. Association of IL-1 β polymorphism with recurrent aphthous stomatitis in Brazilian individuals. *Oral Dis*. 2006;12:580–3.
- Guimarães AL, Correia-Silva Jde F, Sá AR, Victória JM, Diniz MG, Costa Fde O, et al. Investigation of functional gene polymorphisms IL-1 β , IL-6, IL-10 and TNF- α in individuals with recurrent aphthous stomatitis. *Arch Oral Biol*. 2007;52:268–72.
- Hall MA, McGlenn E, Coakley G, Fisher SA, Boki K, Middleton D, et al. Genetic polymorphism of IL-12 p40 gene in immune-mediated disease. *Genes Immun*. 2000;1:219–24.
- Kalkan G, Yigit S, Karakus N, Baş Y, Seçkin HY. Association between interleukin 4 gene intron 3 VNTR polymorphism and recurrent aphthous stomatitis in a cohort of Turkish patients. *Gene*. 2013;527:207–10.
- Pekiner FN, Aytugan E, Demirel GY, Borahan MO. Interleukin-2, interleukin-6 and T regulatory cells in peripheral blood of patients with Behçet's disease and recurrent aphthous ulcerations. *J Oral Pathol Med*. 2012;41:73–9.
- Huling LB, Baccaglioni L, Choquette L, Feinn RS, Lalla RV. Effect of stressful life events on the onset and duration of recurrent aphthous stomatitis. *J Oral Pathol Med*. 2012;41:149–52.
- Wray D, Graykowski EA, Notkins AL. Role of mucosal injury in initiating recurrent aphthous stomatitis. *Br Med J*. 1981;283:1569–70.
- Stone OJ. Aphthous stomatitis (canker sores): a consequence of high oral submucosal viscosity (the role of extracellular matrix and the possible role of lectins). *Med Hypotheses*. 1991;36:341–4.
- Espinoza I, Rojas R, Aranda W, Gamonal J. Prevalence of oral mucosal lesions in elderly people in Santiago, Chile. *J Oral Pathol Med*. 2003;32:571–5.
- Sawair FA. Does smoking really protect from recurrent aphthous stomatitis? *Ther Clin Risk Manag*. 2010;6:573–7.
- Marakoglu K, Sezer RE, Toker HC, Marakoglu I. The recurrent aphthous stomatitis frequency in the smoking cessation people. *Clin Oral Investig*. 2007;11:149–53.
- Donatsky O, Bendixen G. In vitro demonstration of cellular hypersensitivity to strep 2A in recurrent aphthous stomatitis by means of the leucocyte migration test. *Acta Allergol*. 1972;27:137–44.
- Shimoyama T, Horie N, Kato T, Kaneko T, Komiyama K. *Helicobacter pylori* in oral ulcerations. *J Oral Sci*. 2000;42:225–9.
- Stevenson G. Evidence for a negative correlation of recurrent aphthous ulcers with lactobacillus activity. *J La Dent Assoc*. 1967;25:5–7.
- Sun A, Chang JG, Chu CT, Liu BY, Yuan JH, Chiang CP. Preliminary evidence for an association of Epstein-Barr virus with pre-ulcerative oral lesions in patients with recurrent aphthous ulcers or Behçet's disease. *J Oral Pathol Med*. 1998;27:168–75.
- Miura T, Ohtsuka M, Yamamoto T. Sweet's syndrome-like eruption in association with the exacerbation of Behçet's disease after the Great East Japan Earthquake. *Actas Dermosifiliogr*. 2017;108:70–2.
- Wray D, Vlagopoulos TP, Siraganian RP. Food allergens and basophil histamine release in recurrent aphthous stomatitis. *Oral Surg Oral Med Oral Pathol*. 1982;54:388–95.
- Hasan A, Shinnick T, Mizushima Y, van der Zee R, Lehner T. Defining a T-cell epitope within HSP 65 in recurrent aphthous stomatitis. *Clin Exp Immunol*. 2002;128:318–25.
- Nolan A, McIntosh WB, Allam BF, Lamey PJ. Recurrent aphthous ulceration: vitamin B1, B2 and B6 status and response to replacement therapy. *J Oral Pathol Med*. 1991;20:389–91.
- Albanidou-Farmaki E, Markopoulos AK, Kalogerakou F, Antoniadis DZ. Detection, enumeration and characterization of T helper cells secreting type 1 and type 2 cytokines in patients with recurrent aphthous stomatitis. *Tohoku J Exp Med*. 2007;212:101–5.
- Aydemir S, Tekin NS, Aktunç E, Numanoglu G, Ustundağ Y. Celiac disease in patients having recurrent aphthous stomatitis. *Turk J Gastroenterol*. 2004;15:192–5.
- Olzewska M, Sulej J, Kotowski B. Frequency and prognostic value of IgA and IgG endomysial antibodies in recurrent aphthous stomatitis. *Acta Derm Venereol*. 2006;86:332–4.
- Miziara ID, Filho BCA, Weber R. AIDS and recurrent aphthous stomatitis. *Rev Bras Otorrinolaringol*. 2005;71:517–20.
- Muzyka BC, Glick M. Major aphthous ulcers in patients with HIV disease. *Oral Surg Oral Med Oral Pathol*. 1994;77:116–20.
- Natah SS, Konttinen YT, Enattah NS, Ashammakhi N, Sharkey KA, Häyrynen-Immonen R. Recurrent aphthous ulcers today: a review of growing knowledge. *Int J Oral Maxillofac Surg*. 2004;33:221–34.

41. Scully C, Gorsky M, Lozada-Nur F. The diagnosis and management of recurrent aphthous stomatitis: a consensus approach. *J Am Dent Assoc.* 2003;134:200–7.
42. Boulinguez S, Reix S, Bedane C, Debrock C, Bouyssou-Gauthier ML, Sparsa A, et al. Role of drug exposure in aphthous ulcers: a case-control study. *Br J Dermatol.* 2000;143:1261–5.
43. Terkeltaub RA. Colchicine update: 2008. *Semin Arthritis Rheum.* 2009;38:411–9.
44. Berkenstadt M, Weisz B, Cuckle H, Di-Castro M, Guetta E, Barkai G. Chromosomal abnormalities and birth defects among couples with colchicine treated familial Mediterranean fever. *Am J Obstet Gynecol.* 2005;193:1513–6.
45. Boulinguez S, Sommet A, Bedane C, Viraben R, Bonnetblanc JM. Oral nicorandil-induced lesions are not aphthous ulcers. *J Oral Pathol Med.* 2003;32:482–5.
46. Edgar NR, Saleh D, Miller RA. Recurrent aphthous stomatitis: a review. *J Clin Aesthet Dermatol.* 2017;10:26–36.
47. Suárez-Díaz S, Núñez-Batalla F, Fernández-García MS, Fernández-Llana MB, Yllera-Gutiérrez C, Caminal-Montero L. Aphthous stomatitis and laryngitis, another form of presentation of an IgG4-related disease? *Reumatol Clin.* 2019, in press.
48. Pastore L, De Benedittis M, Petrucci M, Tatò D, Napoli C, Montagna MT, et al. Importance of oral signs in the diagnosis of atypical forms of celiac disease. *Recenti Prog Med.* 2004;95:482–90.
49. Wu YC, Wu YH, Wang YP, Chang JYF, Chen HM, Sun A. Anti-gastric parietal cell and antithyroid autoantibodies in patients with recurrent aphthous stomatitis. *J Formos Med Assoc.* 2017;116:4–9.
50. Muñoz-Corcuera M, Esparza-Gómez G, González-Moles MA, Bascones-Martínez A. Oral ulcers: clinical aspects. A tool for dermatologists. Part II. Chronic ulcers. *Clin Exp Dermatol.* 2009;34:456–61.
51. Poulter LW, Lehner T. Immunohistology of oral lesions from patients with recurrent oral ulcers and Behçet's syndrome. *Clin Exp Immunol.* 1989;78:189–95.
52. Brocklehurst P, Tickle M, Glenny AM, Lewis MA, Pemberton MN, Taylor J, et al. Systemic interventions for recurrent aphthous stomatitis (mouth ulcers). *Cochrane Database Syst Rev.* 2012;12:CD005411.
53. Tarakji B, Gazal G, Al-Maweri SA, Azzeghaiby SN, Alaizari N. Guideline for the diagnosis and treatment of recurrent aphthous stomatitis for dental practitioners. *J Int Oral Health.* 2015;7:74–80.
54. Chiang CP, Yu-Fong Chang J, Wang YP, Wu YH, Wu YC, Sun A. Recurrent aphthous stomatitis - etiology, serum autoantibodies, anemia, hematinic deficiencies, and management. *J Formos Med Assoc.* 2019;118:1279–41289.
55. Alli BY, Erinoso OA, Olawuyi AB. Effect of sodium lauryl sulfate on recurrent aphthous stomatitis: a systematic review. *J Oral Pathol Med.* 2019;00:1–7.
56. Cui RZ, Bruce AJ, Rogers RS 3rd. Recurrent aphthous stomatitis. *Clin Dermatol.* 2016;34:475–81.
57. Altenburg A, El-Haj N, Micheli C, Puttkammer M, Abdel-Naser MB, Zouboulis CC. The treatment of chronic recurrent oral aphthous ulcers. *Dtsch Arztebl Int.* 2014;111:665–73.
58. Volkov I, Rudoy I, Freud T, Sardal G, Naimer S, Peleg R, et al. Effectiveness of vitamin B12 in treating recurrent aphthous stomatitis: a randomized, double-blind, placebo-controlled trial. *J Am Board Fam Med.* 2009;22:9–16.
59. Saikaly SK, Saikaly TS, Saikaly LE. Recurrent aphthous ulceration: a review of potential causes and novel treatments. *J Dermatolog Treat.* 2018;29:542–52.
60. Lalla RV, Choquette LE, Feinn RS, Zawistowski H, Latortue MC, Kelly ET, et al. Multivitamin therapy for recurrent aphthous stomatitis: a randomized, double-masked, placebo-controlled trial. *J Am Dent Assoc.* 2012;143:370–6.
61. Sharma R, Pallagatti S, Aggarwal A, Sheikh S, Singh R, Gupta D. A randomized, double-blind, placebo-controlled trial on clinical efficacy of topical agents in reducing pain and frequency of recurrent aphthous ulcers. *Open Dent J.* 2018;12:700–13.
62. Soylu Özler G, Okuyucu Ş, Akoğlu E. The Efficacy of Sucralfate and Chlorhexidine as an Oral Rinse in Patients with Recurrent Aphthous Stomatitis. *Adv Med.* 2014;2014:986203.
63. Rattan J, Schneider M, Arber N, Gorsky M, Dayan D. Sucralfate suspension as a treatment of recurrent aphthous stomatitis. *J Intern Med.* 1994;236:341–3.
64. Liu C, Zhou Z, Liu G, Wang Q, Chen J, Wang L, et al. Efficacy and safety of dexamethasone ointment on recurrent aphthous ulceration. *Am J Med.* 2012;125:292–301.
65. Bhat S, Sujatha D. A clinical evaluation of 5% amlexanox oral paste in the treatment of minor recurrent aphthous ulcers and comparison with the placebo paste: a randomized, vehicle controlled, parallel, single center clinical trial. *Indian J Dent Res.* 2013;24:593–8.
66. Pourahmad M, Rahiminejad M, Fadaei S, Kashafi H. Effects of camel thorn distillate on recurrent oral aphthous lesions. *J Dtsch Dermatol Ges.* 2010;8:348–52.
67. Altenburg A, Zouboulis CC. Current concepts in the treatment of recurrent aphthous stomatitis. *Skin Therapy Lett.* 2008;13:1–4.
68. Pakfetrat A, Mansourian A, Momen-Heravi F, Delavarian Z, Momen-Beitollahi J, Khalilzadeh O, et al. Comparison of colchicine versus prednisolone in recurrent aphthous stomatitis: A double-blind randomized clinical trial. *Clin Invest Med.* 2010;33:E189–95.
69. De Abreu MA, Hirata CH, Pimentel DR, Weckx LL. Treatment of recurrent aphthous stomatitis with clofazimine. *Oral Surg Oral Med Oral Pathol Oral Radiol Endod.* 2009;108:714–21.
70. Hello M, Barbarot S, Bastuji-Garin S, Revuz J, Chosidow O. Use of thalidomide for severe recurrent aphthous stomatitis: a multicenter cohort analysis. *Medicine (Baltimore).* 2010;89:176–82.
71. Mimura M, Hirota SK, Sugaya NN, Sanches JA Jr, Migliari DA. Systemic treatment in severe cases of recurrent aphthous stomatitis: an open trial. *Clinics (Sao Paulo).* 2009;64:193–8.
72. Femiano F, Buonaiuto C, Gombos F, Lanza A, Cirillo N. Pilot study on recurrent aphthous stomatitis (RAS): a randomized placebo-controlled trial for the comparative therapeutic effects of systemic prednisone and systemic montelukast in subjects unresponsive to topical therapy. *Oral Surg Oral Med Oral Pathol Oral Radiol Endod.* 2010;109:402–7.
73. Koray M, Ak G, Kürklü E, Tanyeri H, Aydin F, Oguz FS, et al. The effect of beta-glucan on recurrent aphthous stomatitis. *J Altern Complement Med.* 2009;15:111–2.
74. Sand FL, Thomsen SF. Efficacy and safety of TNF- α inhibitors in refractory primary complex aphthosis: a patient series and overview of the literature. *J Dermatolog Treat.* 2013;24:444–6.
75. Suter VGA, Sjölund S, Bornstein MM. Effect of laser on pain relief and wound healing of recurrent aphthous stomatitis: a systematic review. *Lasers Med Sci.* 2017;32:953–63.
76. Schibler F, Heidemeyer K, Klötgen HW, Keshavamurthy V, Yawalkar N. Apremilast for treatment of recalcitrant aphthous stomatitis. *JAAD Case Rep.* 2017;30:410–1.
77. Samet N, Laurent C, Susarla SM, Samet-Rubinsteen N. The effect of bee propolis on recurrent aphthous stomatitis: a pilot study. *Clin Oral Investig.* 2007;11:143–7.
78. Mousavi F, Mojaver YN, Asadzadeh M, Mirzazadeh M. Homeopathic treatment of minor aphthous ulcer: a randomized, placebo-controlled clinical trial. *Homeopathy.* 2009;98:137–41.
79. Zhou P, Mao Q, Hua H, Liu X, Yan Z. Efficacy and safety of Chinese patent medicines in the treatment of recurrent aphthous stomatitis: a systematic review. *J Am Dent Assoc.* 2017;148:17–25.

80. Altenburg A, Abdel-Naser MB, Seeber H, Abdallah M, Zouboulis CC. Practical aspects of management of recurrent aphthous stomatitis. *J Eur Acad Dermatol Venereol.* 2007;21:1019–26.
81. Hamuryudan V, Ozyazgan Y, Hizli N, Mat C, Yurdakul S, Tüzün Y, et al. Azathioprine in Behçet's syndrome: effects on long-term prognosis. *Arthritis Rheum.* 1997;40:769–74.
82. Evereklioglu C. Current concepts in etiology and treatment of Behçet's disease. *Surv Ophthalmol.* 2005;50:297–350.
83. Zouboulis Ch C, Orfanos CE. Treatment of Adamantiades- Behçet's disease with systemic interferon alfa. *Arch Dermatol.* 1998;134:1010–6.