

10. Del Pozo Hernando LJ, Giacaman A, Corral-Magaña O, Escudero Góngora MM. Dermatoscopia en las infecciones de la infancia. *Piel*. 2017;32:423–32.
11. Abarzúa A, Cataldo K, Álvarez S. Dermoscopy in tungiasis. *Indian J Dermatol Venereol Leprol*. 2014;80:371–3.

J. Boix-Vilanova,^{a,*} L.J. del Pozo Hernando,^a
H. Rodrigo Lara,^b O. Corral-Magaña^a

^a Servicio de Dermatología, Hospital Universitari Son Espases, Palma de Mallorca, Spain

^b Servicio de Anatomía Patológica, Hospital Universitari Son Espases, Palma de Mallorca, Spain

* Corresponding author.

E-mail address: julian.boix@gmail.com (J. Boix-Vilanova).

<https://doi.org/10.1016/j.adengl.2020.04.001>
1578-2190/ © 2020 Published by Elsevier España, S.L.U. on behalf of AEDV. This is an open access article under the CC BY-NC-ND license (<http://creativecommons.org/licenses/by-nc-nd/4.0/>).

Chondroid Syringoma Mimicking Basal Cell Carcinoma[☆]



Siringoma condroide simulando un carcinoma basocelular

To the Editor:

Chondroid syringoma, also known as a mixed skin tumor, is an infrequent neoplasm that is derived from the sweat glands and forms part of the large group of cutaneous adnexal neoplasms. Originally described by Billroth in 1859, it was not until 1961 that Hirsch and Heldwig first used the term to describe this entity, which is characterized by the presence of an epithelial component within a fibrochondroid stroma.¹ This tumor accounts for less than 0.1% of all diagnosed skin tumors.² Given its low incidence, together with its silent and nonspecific clinical presentation, clinicians often require histological data in order to establish diagnosis. The differential diagnosis should include other adnexal tumors. However, to date there have been no published descriptions

of a clinical presentation mimicking basal cell carcinoma, as observed in the case reported here.

A 48-year-old man with no medical history of interest consulted for an asymptomatic, slow-growing nodular lesion (1 cm in diameter) with a smooth, pearly surface, located in the upper third of the right nasogenian sulcus (Fig. 1A). Dermoscopy (Fig. 1B) revealed irregular telangiectatic vessels associated with cotton-white structures on an erythematous-white bed. The initial clinical suspicion was nodular basal cell carcinoma. Histology, performed after surgical removal of the tumor, was compatible with chondroid syringoma (Fig. 2).

Chondroid syringoma is a benign tumor of adnexal origin that is more frequent in young men, and is typically located on the head and neck area, in particular on the nose, cheek, and upper lip, although involvement of other regions including the trunk, genital area, and extremities has also been described.³ This tumor is usually solitary and rarely exceeds 2 cm in diameter. Malignant transformation is very rare but should be suspected in cases of chondroid syringoma

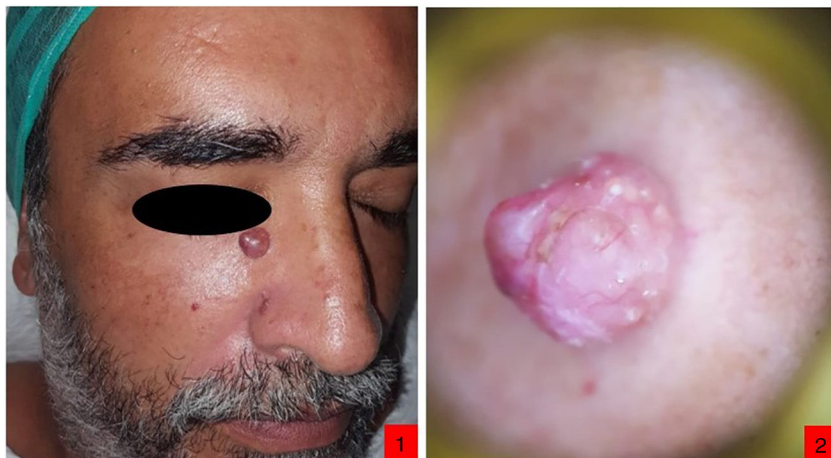

Figure 1 A, Red nodule with a smooth surface located in the upper third of the right nasogenian sulcus. B, Dermoscopy. Reddish-white bed with irregular telangiectatic vessels and cotton-white areas.

[☆] Please cite this article as: Linares González L, Aguayo Carreras P, Rueda Villafranca B, Navarro-Triviño FJ. Siringoma condroide simulando un carcinoma basocelular. *Actas Dermosifiliogr*. 2020;111:337–338.

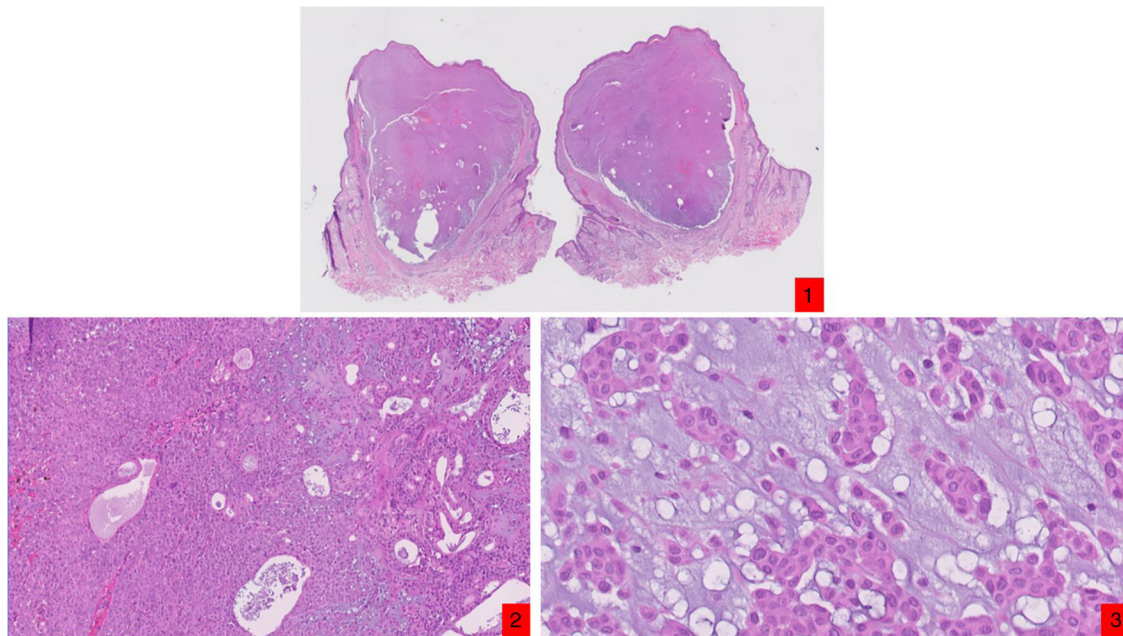


Figure 2 A, Panoramic image showing a dermal tumor with well-defined borders and mild peripheral retraction (hematoxylin-eosin [HE], original magnification $\times 10$). B, Higher magnification image showing cuboidal cells with eosinophilic cytoplasm and without cytological atypia, arranged in strands forming tubular structures (HE, original magnification $\times 20$). C, occasionally, the stroma has a chondroid and myxoid appearance (HE, original magnification $\times 40$).

exceeding 3 cm and located on the trunk and extremities in young women.^{4,5} Up to 50% of malignant chondroid syringomas metastasize to the lymph nodes, lungs, or bone.^{2,6}

Chondroid syringoma presents as a well-defined, slow-growing, firm, mobile painless nodule.⁷ There is no specific, defined dermoscopic pattern that can provide diagnostically useful information.⁸

The nonspecific clinical and dermoscopic presentation of this neoplasm poses a real diagnostic challenge for dermatologists. The differential diagnosis should include cylindroma, hidradenoma, eccrine poroma, spiradenoma, intradermal nevus, papular mucinosis, and epidermal cyst.⁷ In our case, the initial clinical suspicion was basal cell carcinoma owing to the atypical presentation of the tumor.

Histology shows a well-defined tumor located in the dermis and/or subcutaneous tissue with epithelial and stromal components. The epithelial component includes glandular-like structures, nests, or cell strands that form ducts and tubules. The stromal component is characterized by a prominent mucinous stroma that eventually becomes chondroid and may contain hyalinized areas and myoepithelial cells.⁹ Histological characteristics that are considered signs of malignant transformation include asymmetry, cytological atypia, infiltrative margins, satellite tumor nodules, necrosis, and compromise of deep structures.^{2,10}

Complete surgical removal is the treatment of choice, although other therapeutic alternatives such as electrocoagulation, dermabrasion, and vaporization with argon laser or CO₂ laser have also been described.² In cases involving malignant transformation, removal with surgical margins of

at least 1 cm is recommended, and adjuvant radiotherapy may also be considered.⁵

References

- Hirsch P, Helwig EB. Chondroid syringoma: mixed tumor of skin, salivary gland type. *Arch Dermatol.* 1961;84:835–47.
- Yavuzer R, Basterzi Y, Sari A, Bir F, Sezer C. Chondroid syringoma: a diagnosis more frequent than expected. *Dermatol Surg.* 2003;29:179–81.
- Barman DC, Bhowmik A. An unusual presentation of chondroid syringoma. *Indian J Pathol Microbiol.* 2016;59:362–4.
- Watarai A, Amoh Y, Aki R, Takasu H, Katsuoka K. Malignant chondroid syringoma: report of a case with lymph node metastasis 12 years after local excision. *Dermatol Online J.* 2011;17:5.
- Lu H, Chen LF, Chen Q, Shen H, Liu Z. A rare large cutaneous chondroid syringoma involving a toe. *Medicine (Baltimore).* 2018;97:e9825.
- Famulski W, Kánczuga-Koda L, Niewaroska K, Niksa M, Maruszak K, Koda M, et al. Malignant mixed tumor of the skin: a case report and review of the literature. *Progr Health Sci.* 2013;3:154–8.
- Min KH, Byun JH, Lim JS, Lee HK, Lee WM, Joo JE. Chondroid syringoma on face. *Arch Craniofac Surg.* 2016;17:173–5.
- Villalón G, Monteagudo C, Martínez JM, Ramón D, Alonso V, Jordá E. Siringoma condroide: revisión clínica e histológica de ocho casos. *Actas Dermosifiliogr.* 2006;97:573–7.
- Vrotsos E, Alexis J. Dermatopathology diagnosis. *Cutis.* 2014;93:77–8.
- Bates AW, Baithun SI. Atypical mixed tumor of the skin: histologic, immunohistochemical, and ultrastructural features in

three cases and a review of the criteria for malignancy. *Am J Dermatopathol.* 1998;20:35–40.

L. Linares González,^{a,*} P. Aguayo Carreras,^a
B. Rueda Villafranca,^b F.J. Navarro-Triviño^a

^a *Unidad de Dermatología Médico-Quirúrgica y Venereología, Hospital Universitario San Cecilio, Granada, Spain*

^b *Unidad de Gestión Clínica de Anatomía Patológica, Hospital Universitario San Cecilio, Granada, Spain*

* Corresponding author.

E-mail address: laura.linares.gz@gmail.com
(L. Linares González).

<https://doi.org/10.1016/j.adengl.2020.04.004>
1578-2190/ © 2019 AEDV. Published by Elsevier España, S.L.U. This is an open access article under the CC BY-NC-ND license (<http://creativecommons.org/licenses/by-nc-nd/4.0/>).

Interstitial Granulomatous Dermatitis and Tocilizumab: Is This Treatment Useful for This Skin Condition?☆



Dermatitis granulomatosa intersticial y tocilizumab: ¿es este un tratamiento de utilidad para esta dermatosis?

To the Editor:

Onset of interstitial granulomatous dermatitis (IGD), a rare skin disease with a variable clinical presentation and a characteristic pathological pattern, has been associated with various systemic diseases and different drugs.¹ Tocilizumab is a humanized monoclonal antibody directed against the interleukin-6 (IL-6) receptor, and has been used to treat IGD with good results.² We present a case of IGD that began while the affected patient was being treated with tocilizumab, and question whether this drug is truly useful for the treatment of this disease.

The patient was a 62-year-old woman who had a history of antisynthetase syndrome with muscle, lung, and joint involvement and had started treatment with tocilizumab at a dose of 8 mg/kg/month. She was referred to the dermatology service for slightly itchy, mildly painful skin lesions that had appeared 9 months after beginning tocilizumab treatment. The patient had no medical history of interest and had not been treated with any other drugs. The lesions consisted of well defined, infiltrated, edematous, erythematous plaques with no epidermal component that were prone to central clearing, resulting in an arciform morphology (Fig. 1). The lesions were located on the armpits, the shoulder girdle, and the internal aspects of the arms (Fig. 2).

A skin biopsy revealed an unaltered epidermis, interstitial histiocytic infiltrate with perivascular accentuation along the entire thickness of the dermis, and an absence of mucin deposits. In certain fields, higher magnification revealed some interstitial and intravascular neutrophils (Fig. 3), based on which a histopathological diagnosis of IGD was established.

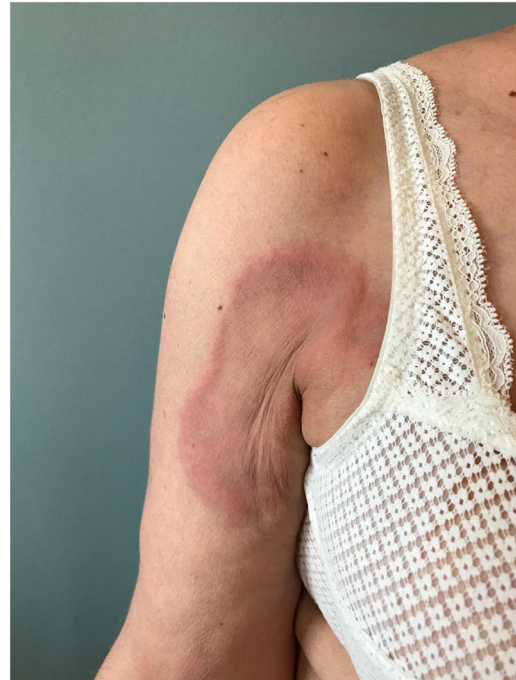

Figure 1 Erythematous, edematous, nonscaling plaque with neat borders and annular morphology on the anterior aspect of the right arm.

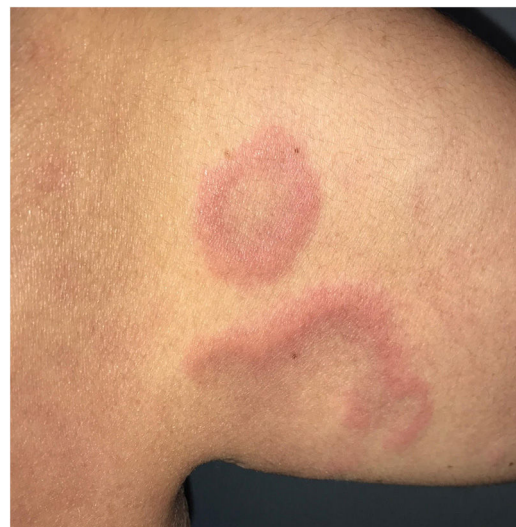

Figure 2 Two similar lesions with clear arciform morphology located on the posterior aspect of the right arm.

☆ Please cite this article as: de Perosanz Lobo D, Saceda Corralo D, Ortega Quijano D, Carrillo Gijón R. Dermatitis granulomatosa intersticial y tocilizumab: ¿es este un tratamiento de utilidad para esta dermatosis? *Actas Dermosifiliogr.* 2020;111:343–345.