

3. Brown TJ, Yen-Moore A, Tying SK. An overview of sexually transmitted diseases: Part I. *JAAD*. 1999;41:511–32.
4. Li JH, Guo H, Gao XH, Chen HD. Multiple skin ulcers from malignant syphilis. *Lancet*. 2015;356:1564.
5. Mohan G, Ali RA, Isache CL, Sharma RK, Perniciario C. Malignant syphilis: ostrateous, ulceronecrotic lesions in a patient with human immunodeficiency virus. *DOJ*. 2017;23:5.
6. Kumar B, Muralidhar S. Malignant syphilis: a review. *AIDS Patient Care STDS*. 1998;12:921–5.
7. Dos Santos TR, De Castro IJ, Dahia M, De Azevedo M, Da Silva G, Motta R, et al. Malignant syphilis in an AIDS patient. *Infection*. 2015;43:231–6.
8. Yanagisawa N, Ando M, Imamura A, Akagi K, Horiguchi S, Suganuma A, et al. Pathologically confirmed malignant syphilis in an HIV-infected patient. *Intern Med*. 2011;50:2423–6.
9. Resneck JS, van Beek M, Furmanski L, Oyugi J, Leboit PE, Katabira E, et al. Etiology of pruritic papular eruption with HIV infection in Uganda. *JAMA*. 2004;292:2614–21.
10. Farsani TT, Kore S, Nadol P, Ramam M, Thierman SJ, Leslie K, et al. Etiology and risk factors associated with a pruritic papular eruption in people living with HIV in India. *J Int AIDS Soc*. 2013;16:17325.
11. Fernandes MS, Bhat RM. Spectrum of mucocutaneous manifestations in human immunodeficiency virus-infected patients and its correlation with CD4 lymphocyte count. *J STD AIDS*. 2015;26:414–9.

J. Granizo-Rubio,^{a,*} C. Caviedes-Vallejo,^a
N. Chávez-Dávila,^b V. Pinos-León^c

^a *Servicio de Dermatología, Hospital de Especialidades Eugenio Espejo, Quito, Ecuador*

^b *Universidad Central del Ecuador, Quito, Ecuador*

^c *DermaAID, Quito, Ecuador*

*Corresponding author.

E-mail address: rubiDaniela94@gmail.com

(J. Granizo-Rubio).

25 July 2018 19 September 2018

1578-2190/ © 2019 AEDV. Published by Elsevier España, S.L.U. This is an open access article under the CC BY-NC-ND license (<http://creativecommons.org/licenses/by-nc-nd/4.0/>).

Coincident Primary Cutaneous CD4+ Small/Medium-Sized Pleomorphic T-Cell Lymphoproliferative Disorder in Two Sisters[☆]



Trastorno linfoproliferativo primario de células T pleomórficas pequeñas/medianas CD4+ coincidente en dos hermanas

To the Editor:

Primary cutaneous CD4⁺ small/medium-sized pleomorphic T-cell lymphoproliferative disorder (CD4⁺ PCSM-TLPD) is an uncommon entity that was first included as an independent entity (named CD4⁺ primary cutaneous small/medium-sized pleomorphic T-cell lymphoma) in the 2005 classification of lymphoid neoplasms of the WHO-EORTC (World Health Organization–European Organization for Research and Treatment of Cancer). Given its apparent indolent character, the nomenclature was changed in 2016 to CD4⁺ PCSM-TLPD, although this remained a provisional entity. We present the first case of simultaneous appearance of CD4⁺ PCSM-TLPD in 2 sisters.

Two sisters, aged 54 and 58 years, were seen for similar lesions located on the left cheek and cervical area, respectively, that had appeared 2 and 3 years earlier, respectively. Neither of the sisters reported any potential triggers. The patients did not live together, but both lived in rural areas. The physical examination revealed firm, infiltrated, erythematous cupuliform papules with neat borders

(Fig. 1). Histology showed a dense lymphohistiocytic infiltrate in the dermis and hypodermis with tropism for adnexal structures. Epidermotropism was absent. The infiltrate consisted of small-to-medium-sized pleomorphic lymphocytes, with mild-to-moderate atypia (Fig. 2). Immunohistochemistry was positive for CD3, CD4, and PD-1, and negative for CD10 and Bcl-6, and revealed large isolated CD30⁺ cells and preserved CD7/CD5/CD2 immunostaining (Fig. 3). Accompanying CD8⁺ and CD20⁺ cell populations were also observed. Monoclonal T-cell receptor (TCR)-beta rearrangement was observed for both samples, with no clonal overlap between samples. The results of the staging workup (cervical thoracic abdominal pelvic computed tomography scan and lactate dehydrogenase analysis) were negative. It was decided to adopt a wait-and-see approach, and spontaneous remission was observed after 6 months in both patients.

CD4⁺ PCSM-TLPD is classified as a provisional entity within the category of cutaneous lymphomas, of which it accounts for approximately 2% of cases. Although it can occur at any age, it typically affects adults that have reached the fifth decade of life, and no clear sex predisposition is

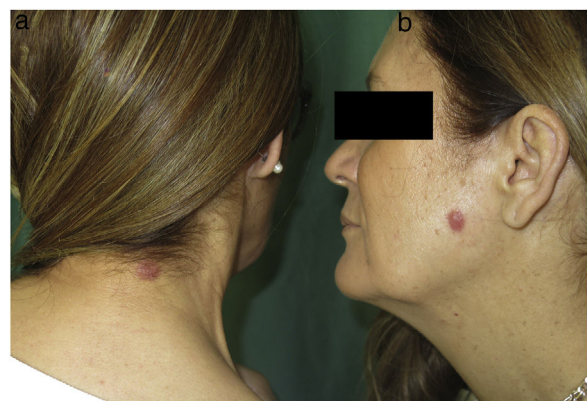


Figure 1 Firm, infiltrated, erythematous cupuliform papules in the posterior cervical region (A) and on the left cheek (B).

[☆] Please cite this article as: Ponce S, Peñate Y, Montenegro T. Trastorno linfoproliferativo primario de células T pleomórficas pequeñas/medianas CD4+ coincidente en dos hermanas. *Actas Dermosifiliogr*. 2020;111:271–273.

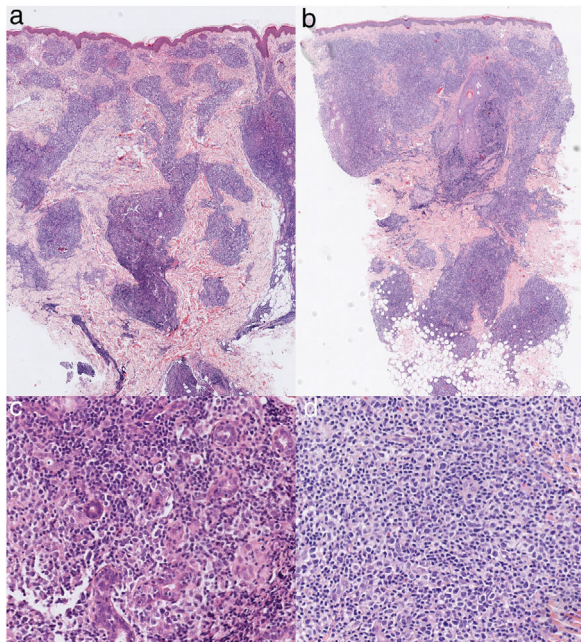


Figure 2 Histological images of the lesions in the cervical region (A) and on the left cheek (B) showing lymphohistiocytic infiltrate in the dermis and hypodermis with tropism for adnexal structures and the absence of epidermotropism (hematoxylin-eosin, original magnification $\times 2$). Histological images of the lesions in the cervical region (C) and on the left cheek (D) showing infiltrate consisting of pleomorphic cells with mild-to-moderate atypia (hematoxylin-eosin, original magnification $\times 20$).

described.¹⁻⁸ The pathogenesis of this entity is unknown and controversial; a recent series of 62 patients, of whom 11 underwent genomic analyses, reported no associated genomic alteration.²

CD4⁺ PCSM-TLPD typically presents as solitary lesions in the upper body (mainly the head or neck), usually in the form of asymptomatic nodules, plaques, or erythematous tumors.² Histology reveals infiltrate composed of small-to-medium-sized pleomorphic lymphocytes with mild-to-moderate cellular atypia, the absence of obvious epidermotropism, and, in some cases, tropism for adnexal structures.² The immunohistochemical profile of these cells is CD3⁺, CD4⁺, CD30⁻, CD8⁻, with variable loss of T-cell markers (CD7, CD5, and CD2) and variable positivity for follicular T-helper cell markers (PD-1, Bcl-6, and CXCL-13).²⁻⁴ The true nature of these cells is not entirely clear. Accompanying the neoplastic T cells are populations of CD20⁺ B cells and CD8⁺ T cells, as well as some large, isolated, pleomorphic CD30⁺ cells (<30%). The proliferative (Ki-67) index is usually less than 50%.² A monoclonal TCR gene rearrangement has been described in more than 80% of cases in the majority of published series.¹⁻⁸

CD4⁺ PCSM-TLPD has a very favorable prognosis, with a 5-year survival rate of 80–90%.^{2,4} In the most extensive (n = 136) case series published,³ Beltraminelli and coworkers reported no extracutaneous involvement in 45 patients followed for a mean period of 64 months. Systemic involvement has only been described in a series of 24 patients published by García-Herrera et al.⁶ The authors reported

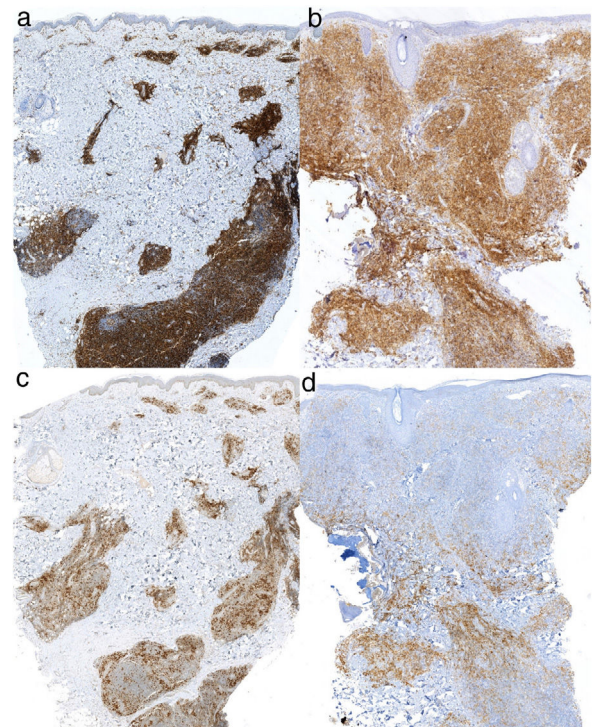


Figure 3 Immunohistochemistry showing positive staining for CD4 (original magnification $\times 2$) in the lesions in the cervical region (A) and on the left cheek (B). Immunohistochemistry showing positive staining for PD-1 (original magnification $\times 2$) in the lesions in the cervical region (C) and on the left cheek (D).

5 cases of extracutaneous involvement and proposed that rapid growth, a high proliferative index, and scarce CD8⁺ infiltrate were poor prognostic factors, although the study population consisted of patients with very heterogeneous characteristics. We believe that based on their characteristics (large, fast-growing lesions with variable expression of CD4, loss of CD7, a high proliferative index, and extracutaneous involvement), these lesions would be better classified as primary cutaneous peripheral T-cell lymphoma not otherwise specified. No other cases of systemic involvement have been described in any of the other published series.¹⁻⁸ Treatment options include surgery (first-line treatment in patients with solitary lesions), topical corticosteroids, and phototherapy. Only 3 cases of complete spontaneous remission are described in the literature.^{5,9,10}

The differential diagnosis includes other cutaneous B-cell and T-cell lymphomas, as well as reactive lymphoproliferative processes and pseudolymphomas, the latter of which are difficult to differentiate.⁵ The presence of pleomorphism and cellular atypia, the loss of T-cell markers, positivity for follicular T-helper cells, and monoclonal TCR rearrangement are findings that can help guide the diagnosis of CD4⁺ PCSM-TLPD, although these findings may also be present to a lesser extent in reactive processes.²⁻⁵

In conclusion, we present 2 new cases of CD4⁺ PCSM-TLPD and describe for the first time 2 simultaneous cases of this entity in sisters. Both patients achieved spontaneous remission, of which there are few reports in the current literature. The true nature of this entity and its differential

diagnosis from reactive lymphoproliferative processes has been the subject of some controversy since its classification as a form of cutaneous lymphoma. The simultaneous appearance of this lesion in 2 sisters supports a reactive origin, given the possibility of exposure to similar environmental factors, as well as a possible influence of as-yet-unknown genetic factors.

References

1. Baum CL, Link BK, Neppalli VT, Swick BL, Liu V. Reappraisal of the provisional entity primary cutaneous CD4+ small/medium pleomorphic T-cell lymphoma: a series of 10 adult and pediatric patients and review of the literature. *J Am Acad Dermatol*. 2011;65:739–48.
2. Alberti-Violetti S, Torres-Cabala CA, Talpur R, Corti L, Fanoni D, Venegoni L, et al. Clinicopathological and molecular study of primary cutaneous CD4+ small/medium-sized pleomorphic T-cell lymphoma. *J Cutan Pathol*. 2016;43:1121–30.
3. Beltraminelli H, Leinweber B, Keri H, Cerroni L. Primary cutaneous CD4+ small/medium-sized pleomorphic T-cell lymphoma: a cutaneous nodular proliferation of pleomorphic T lymphocytes of undetermined significance? A study of 136 cases. *Am J Dermatopathol*. 2009;31:317–22.
4. Ally MS, Prasad-Hunasehally RY, Rodriguez-Justo M, Martin B, Verdolini R, Attard N, et al. Evaluation of follicular T-helper cells in primary cutaneous CD4+ small/medium pleomorphic T-cell lymphoma and dermatitis. *J Cutan Pathol*. 2013;40:1006–13.
5. Grogg KL, Jung S, Erickson LA, McClure RF, Dogan A. Primary cutaneous CD4-positive small/medium-sized pleomorphic T-cell lymphoma: a clonal T-cell lymphoproliferative disorder with indolent behaviour. *Mod Pathol*. 2008;21:708–15.
6. García-Herrera A, Colomo L, Camós M, Carreras J, Balague O, Martínez A, et al. Primary cutaneous small/medium CD4+ T-cell lymphoma: a heterogeneous group of tumors with different clinicopathologic features and outcome. *J Clin Oncol*. 2008;26:3364–71.
7. Rodríguez-Pinilla SM, Roncador G, Rodríguez-Peralto JL, Mollejo M, García JF, Montes-Moreno S, et al. Primary cutaneous CD4+ small/medium-sized pleomorphic T-cell lymphoma expresses follicular T-cell markers. *Am J Surg Pathol*. 2009;33:81–90.
8. Williams VL, Torres-Cabala CA, Duvic M. Primary cutaneous small-to medium-sized CD4+ pleomorphic T-cell lymphoma: a retrospective case series and review of the provisional cutaneous lymphoma category. *Am J Clin Dermatol*. 2011;12:389–401.
9. Messegue F, Gimeno E, Agusti-Mejias A, San Juan J. Primary cutaneous CD4+ small-to-medium-sized pleomorphic T-cell lymphoma: report of a case with spontaneous resolution. *Actas Dermosifiliogr*. 2011;102:636–8.
10. Ayala D, Ramón MD, Cabezas M, Jordá E. Primary cutaneous CD4+ small/medium-sized pleomorphic T-cell lymphoma with expression of follicular T-helper cell markers and spontaneous remission. *Actas Dermosifiliogr*. 2016;107:357–9.

S. Ponce,^{a,*} Y. Peñate,^a T. Montenegro^b

^a *Servicio de Dermatología, Complejo Hospitalario Universitario Insular – Materno Infantil, Las Palmas de Gran Canaria, Spain*

^b *Servicio de Anatomía Patológica, Complejo Hospitalario Universitario Insular – Materno Infantil, Las Palmas de Gran Canaria, Spain*

* Corresponding author.

E-mail address: sauloponce90@gmail.com (S. Ponce).

1578-2190/ © 2019 AEDV. Published by Elsevier España, S.L.U. This is an open access article under the CC BY-NC-ND license (<http://creativecommons.org/licenses/by-nc-nd/4.0/>).

Adalimumab-Induced Neutropenia in a Man With Hidradenitis Suppurativa[☆]



Neutropenia inducida por adalimumab en un paciente con hidradenitis supurativa

To the Editor:

Anti-tumor necrosis factor (TNF) agents are among the drugs used to treat hidradenitis suppurativa. These treatments are generally well tolerated, but patients must be monitored closely when taking them. Hematologic complications are an uncommon adverse effect of anti-TNF therapy and have only rarely been described in the literature. We report a case of severe neutropenia (< 500/mm³) in a man with hidradenitis suppurativa. The complication developed within 3 months of his starting anti-TNF therapy.

Case Description

The patient was a 21-year-old man who had been diagnosed with hidradenitis suppurativa (Hurley stage 3) in adolescence. He had been treated with acitretin (50 mg/d), rifampicin (600 mg/d) combined with clindamycin (300 mg/d) and adjuvant intralesional corticosteroids (triamcinolone) in succession, without experiencing improvement. There were no other relevant aspects of his medical history; nor was he on other medications. Treatment with adalimumab began at an initial dose of 160 mg the first week, followed by 80 mg the second week and 40 mg every 2 weeks after that. The previous treatments with rifampicin and clindamycin were suspended 3 weeks before adalimumab was started, and the patient was taking no analgesics or other medications. Before treatment his white blood cell count was 5450/mm³ (neutrophils, 1980/mm³). Later blood tests showed gradually decreasing neutrophil counts, to 1540/mm³ at 1 month and 480/mm³ at 2 months after the first injection of adalimumab. Hemoglobin, red blood cell, lymphocyte, and platelet counts were normal, and no infections could be demonstrated during this period. The patient had no signs or symptoms of infection at any time, and serology for syphilis and human immunodeficiency

[☆] Please cite this article as: Rueda Carnero JM, Nieto Rodríguez D, de Lucas Laguna R, Feito Rodríguez M. Neutropenia inducida por adalimumab en un paciente con hidradenitis supurativa. *Actas Dermosifiliogr*. 2020;111:273–274.