

from injection sites and without thrombocytopenia. *J Intern Med.* 1998;243:313–5.

4. Gan WK. Diagnostic challenge of heparin-induced skin necrosis. *Ann Clin Lab Res.* 2017;5:213.
5. Domínguez Espinosa E, Díaz Madrid M. Necrosis cutánea por heparina. *Piel.* 2009;24:362–3.
6. Sánchez PS, Angelillo SA, Masouyé I, Borradori L. Widespread skin necrosis associated with unfractionated heparin therapy in a patient under chronic coumarin anticoagulation. *J Eur Acad Dermatol Venereol.* 2006;20:327–30.
7. Llamas-Velasco M, Alegria V, Santos-Briz A, Cerroni L, Kutzner H, Requena L. Occlusive nonvasculitic vasculopathy: A review. *Am J Dermatopathol.* 2016;1:1–25.

A. Estébanez,\* E. Silva, P. Cordero, J.M. Martín

*Servicio de Dermatología, Hospital Clínico Universitario, Valencia, Spain*

\*Corresponding author.

E-mail address: [andreaestebanez\\_7@hotmail.com](mailto:andreaestebanez_7@hotmail.com) (A. Estébanez).

2 February 2018 27 March 2018

<https://doi.org/10.1016/j.adengl.2018.03.026>  
1578-2190/

© 2019 AEDV. Published by Elsevier España, S.L.U. All rights reserved.

## Papular Sarcoidosis of the Knees Following Treatment with Interferon Alpha and Ribavirin in a Woman with Hepatitis C

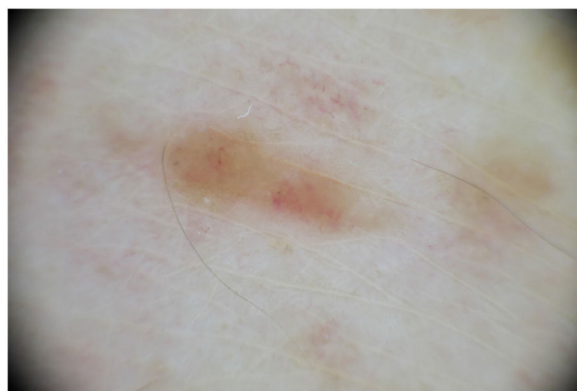

### Sarcoidosis papulosa de las rodillas tras tratamiento con interferón alfa y ribavirina en paciente con hepatitis c

To the Editor:

Chronic hepatitis caused by the hepatitis C virus (HCV) is associated with skin diseases including lichen planus, mixed cryoglobulinemia, porphyria cutanea tarda, pruritus, and necrolytic acral erythema. Cutaneous adverse effects are also common in patients treated with interferon (IFN), particularly when combined with ribavirin. These include injection-site reactions, alopecia, xerosis, pruritus, nummular eczema, lichen planus, and psoriasis flares.<sup>1</sup>

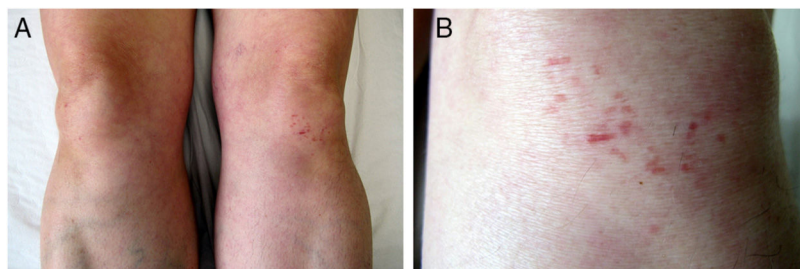
Sarcoidosis is a chronic systemic granulomatous disease of possible autoimmune etiology that primarily affects the lungs and lymph nodes. Induction of sarcoidosis, especially pulmonary and cutaneous forms, has been described in HCV patients treated with IFN alfa and ribavirin. It is thought that IFN alfa favors the differentiation of CD4 T cells, promoting a Th1-type immune response with subsequent granuloma formation. This mechanism may be intensified by ribavirin.<sup>2</sup>



**Figure 2** Dermoscopic image showing an area of homogeneous yellow-orange coloration within which linear vessels are evident. (A full-color version of this image can be found in the web version of this article.)

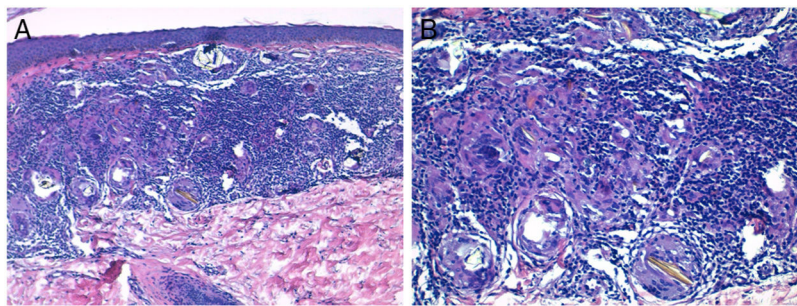
We present the case of an adult woman with chronic hepatitis due to HCV who was treated with telaprevir, IFN alfa, and ribavirin and who developed papular sarcoidosis of the knees.

The patient was a 51-year-old woman with Child class A liver cirrhosis due to HCV genotype 1A, for which she had begun antiviral therapy 6 months earlier with telaprevir, IFN alfa, and ribavirin. She was seen for asymptomatic lesions on the knees that had appeared several months earlier.



**Figure 1** A, Brownish erythematous papules on both knees. B, Detailed image showing lichenoid lesions, some arranged linearly, on the left knee.

☆ Please cite this article as: Monteagudo B, Grueiro MC, Vilas-Sueiro A, Campo-Cerecedo F. Sarcoidosis papulosa de las rodillas tras tratamiento con interferón alfa y ribavirina en paciente con hepatitis C. *Actas Dermosifiliogr.* 2019;110:871–873.



**Figure 3** Histological images. A, Non-necrotizing granulomatous infiltrate in the superficial dermis (hematoxylin-eosin, original magnification  $\times 10$ ). B, Epithelioid histiocytes and birefringent crystalline material phagocytosed by multinucleated giant cells (hematoxylin-eosin, original magnification  $\times 20$ ).

Physical examination revealed multiple brownish erythematous papules (2–5 mm in diameter), some of which were oriented linearly, on both knees (Fig. 1). Dermoscopy revealed an area of homogeneous yellow-orange coloration in which linear vessels were evident (Fig. 2).

Histology of one of the lesions on the left knee revealed a non-necrotizing granulomatous infiltrate in the superficial dermis consisting of epithelioid histiocytes and multinucleated giant cells that phagocytosed birefringent crystalline material under polarized light microscopy (Fig. 3). A diagnosis of papular sarcoidosis of the knees induced by antiviral therapy was established.

Additional tests (laboratory tests with complete blood count, biochemistry, serum levels of angiotensin-converting enzyme, calcium levels in urine collected over 24h, tuberculin test, and chest x-ray) revealed no findings of note. Thoracic computed tomography (CT) revealed minimal involvement of the parenchyma of the peribronchovascular interstitium in the patient's sarcoidosis. The skin lesions on the knees improved a few months after discontinuing antiviral therapy, without the need for treatment.

The prevalence of sarcoidosis is higher in HCV patients (0.12%) than in the general population (1–40 per 100000). Moreover, skin lesions are more common in sarcoidosis patients with HCV (56%) than in those without (22%).<sup>3</sup> In many patients with chronic HCV hepatitis sarcoidosis is triggered by antiviral treatment (IFN alfa administered alone or in combination with ribavirin). The resulting sarcoidosis is usually pulmonary or cutaneous, and has a favorable prognosis. In fact, with adequate follow-up most patients can complete antiviral treatment. Once treatment is discontinued or completed the sarcoidosis lesions tend to resolve spontaneously,<sup>4,5</sup> as observed for the cutaneous and pulmonary lesions in our patient.

Papular sarcoidosis of the knees is considered an intermediate clinical form of sarcoidosis, sharing features of scar and papular sarcoidosis.<sup>6</sup> It is usually the initial manifestation of systemic sarcoidosis and has a good prognosis. It is characterized by the presence of reddish-brown papular lesions on both knees, in some cases with a lichenoid appearance and linear orientation.<sup>7,8</sup> In approximately half of all cases papular sarcoidosis is associated with erythema nodosum (Löfgren syndrome). For many authors, the presence of these lesions on the knees is key for confirmation of sarcoidosis as the underlying cause of erythema nodosum.<sup>9,10</sup>

Papular sarcoidosis lesions on the knees usually resolve spontaneously. Even in the context of systemic sarcoidosis oral corticosteroid treatment is rarely necessary.<sup>10</sup>

Foreign-body particles are present in the lesions in 60% of cases of papular sarcoidosis. The linear distribution of some lesions is suggestive of an exogenous cause. However, patients tend not to report the presence of previous scars in the same location and histology reveals no scar tissue.<sup>10</sup> It is possible that microtrauma results in the inclusion of foreign bodies, and that lesions develop years later in predisposed individuals or in response to treatments such as IFN alfa.<sup>5</sup>

The main differential diagnosis is scar sarcoidosis, a rare clinical form characterized by swelling and reddening of pre-existing scars of many types, including those caused by trauma, tattoos, venipuncture, surgery, hyaluronic acid injection, and burns.<sup>5</sup>

In conclusion, we describe a case of papular sarcoidosis of the knees in a HCV patient treated with telaprevir, IFN alfa, and ribavirin. Sarcoidosis should be suspected in patients with erythematous, occasionally linear papules located on both knees, especially in patients with erythema nodosum or HCV treated with IFN.

## References

1. Floristán U, Feltes R, Ramírez-Marín P, Herranz-Pinto P. Interferón alfa y virus hepatitis C: la piel importa. *Rev Clin Esp.* 2011;211:92–7.
2. Flores-Robles BJ, Sangüeza-Gómez CP, Barbadillo Mateos C, Roustán-Gullón LG, Kovtun I. Sarcoidosis posterior a tratamiento con interferón alfa en paciente con hepatitis C: una asociación que todo médico debería conocer. *Rev Gastroenterol Mex.* 2017;82:185–6.
3. Ramos-Casals M, Mañá J, Nardi N, Brito-Zerón P, Xaubet A, Sánchez Tapias JM, et al. Sarcoidosis in patients with chronic hepatitis C virus infection: Analysis of 68 cases. *Medicine.* 2005;84:69–80.
4. Faurie P, Broussolle C, Zoulim F, Trepo C, Sève P. Sarcoidosis and hepatitis C: Clinical description of 11 cases. *Eur J Gastroenterol Hepatol.* 2010;22:967–72.
5. Novoa R, Barnadas MA, Torras X, Curell R, Alomar A. Reacción granulomatosa a cuerpo extraño a sílice, silicona y ácido hialurónico, en paciente con sarcoidosis inducida por interferón. *Actas Dermosifiliogr.* 2013;104:920–3.

6. Marcoval J, Moreno A, Mañá J. Papular sarcoidosis of the knees: A clue for the diagnosis of erythema nodosum-associated sarcoidosis. *J Am Acad Dermatol.* 2003;49:75–8.
7. Vázquez MD, López T, Mateo S, Mosquera T, Monteagudo B. Sarcoidosis papulosa de las rodillas. *Semergen.* 2016;42:e125–7.
8. García-Arpa M, Franco-Muñoz M, Ramos-Rodríguez C, Flores-Terry MA, Lozano-Masdemont B, Ramírez-Huaranga MA. Sarcoidosis papulosa de las rodillas recurrente tras embarazo. *Piel.* 2017;32:464–7.
9. Lozano-Masdemont B, Gómez-Recuero-Muñoz L, Baniandrés-Rodríguez O. Nódulos y pápulas eritematosas en piernas y rodillas. *Actas Dermosifiliogr.* 2016;107:423–4.
10. Marcoval J, Mañá J. Papular sarcoidosis of the knees. A frequent form of presentation of systemic sarcoidosis. *Sarcoidosis Vasc Diffuse Lung Dis.* 2016;33:59–65.

B. Monteagudo,<sup>a,\*</sup> M.C. Grueiro,<sup>b</sup> A. Vilas-Sueiro,<sup>a</sup>  
F. Campo-Cerecedo<sup>c</sup>

<sup>a</sup> Servicio de Dermatología, Complejo Hospitalario Universitario de Ferrol, Xerencia de Xestión Integrada de Ferrol, SERGAS, Ferrol, A Coruña, Spain

<sup>b</sup> Medicina Familiar y Comunitaria, Centro de Salud de Narón, SERGAS, Narón, A Coruña, Spain

<sup>c</sup> Servicio de Anatomía Patológica, Complejo Hospitalario Universitario de Ferrol, Xerencia de Xestión Integrada de Ferrol, SERGAS, Ferrol, A Coruña, Spain

\* Corresponding author.

E-mail address: [benigno.monteagudo.sanchez@sergas.es](mailto:benigno.monteagudo.sanchez@sergas.es) (B. Monteagudo).

3 February 2018 8 April 2018

<https://doi.org/10.1016/j.adengl.2018.04.024>

1578-2190/

© 2019 AEDV. Published by Elsevier España, S.L.U. All rights reserved.

## Ichthyosiform Reaction Related to Ponatinib Therapy<sup>☆</sup>



### Reacción ictiosiforme en relación con ponatinib

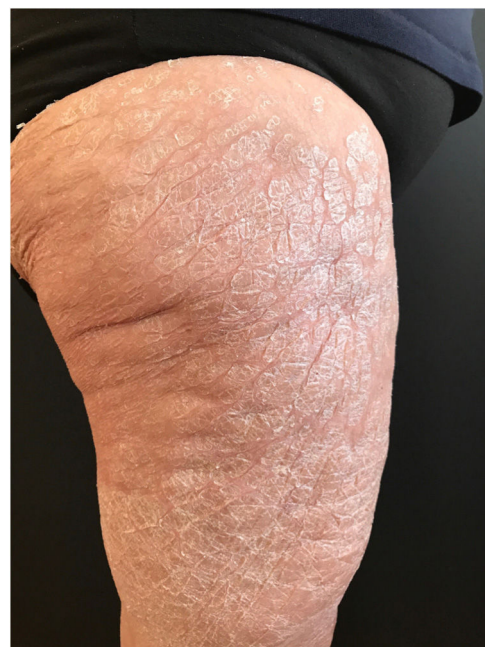To the Editor:

Ponatinib is a potent third-generation tyrosine kinase inhibitor.<sup>1</sup> Its use is indicated in chronic myeloid leukemia (CML), Philadelphia positive acute lymphoblastic leukemia (LLAPh+), and in some types of solid tumors, such as gastrointestinal stromal tumor (GIST).<sup>1</sup> The most common cutaneous adverse effects associated with the use of this drug are xeroderma and different cutaneous exanthema not fully classified in clinical trials.<sup>1,2</sup> We report the case of a patient who developed an ichthyosiform skin reaction secondary to treatment with oral ponatinib.

A 68-year-old woman diagnosed with CML and with no past history of skin disease presented scaly lesions that appeared suddenly 15 days after beginning treatment with ponatinib at a dosage of 45 mg/day. The patient had previously used imatinib and dasatinib, which were suspended owing to lack of efficacy. The lesions had advanced rapidly, were asymptomatic, and were located predominantly on the upper and lower limbs. Physical examination revealed scaly plaques with well-defined edges, a tendency to coalesce, and with no erythema or infiltration detectable to the touch (Fig. 1). The lesions were also present, to a lesser extent, on the back and scalp. It was decided to perform a biopsy of the lesions for the histopathology study (Fig. 2). The epidermis showed compact orthokeratotic hyperkeratosis

with practically no granulomatous layer. The papillary dermis revealed a very mild lymphocytic infiltrate with no other significant signs. PAS and Grocott staining identified no micro-organisms. The diagnosis of ichthyosiform reaction secondary to ponatinib use was confirmed and it was therefore decided to reduce the dose of the drug to 30 mg, and topical treatment with 10% urea, mometasone furoate, and emollients was instated. A marked improvement in the lesions was observed 1 week later and the lesions disappeared after 3 weeks.

Ponatinib is a third-generation tyrosine kinase inhibitor. It is part of the family of tyrosine kinase inhibitors such as imatinib, dasatinib, and nilotinib.<sup>1</sup> It is used as a



**Figure 1** Scaly plaques especially notable on the anterior and lateral regions of both thighs.

<sup>☆</sup> Please cite this article as: Fernández-González P, Buendía-Castaño D, Saceda-Corralo D, Jaen-Olasolo P. Reacción ictiosiforme en relación con ponatinib. *Actas Dermo-Sifiliográficas.* 2019;110:873–875.