

Pyoderma Gangrenosum With Ulcerative Colitis Successfully Treated With Ustekinumab[☆]



Pyoderma gangrenoso asociado a colitis ulcerosa con buena respuesta a ustekinumab

To the Editor:

Pyoderma gangrenosum is a rare neutrophilic skin disease that may be idiopathic or associated with systemic disease such as inflammatory bowel disease, arthritis, paraproteinemia, or blood cancers. While it is true that topical or intralesional therapies can be used in patients with isolated lesions that have little impact on quality of life, in most cases, systemic immunosuppressant treatment is required. Corticosteroids and cyclosporin are used as the first line in systemic treatments. Other reported alternatives, although not approved for this indication, include mycophenolate mofetil, anti-TNF, intravenous immunoglobulins, interleukin (IL) 1 antagonists, and ustekinumab (anti-IL-12/23).¹

A 33-year-old woman diagnosed with ulcerative colitis since the age of 17 years had presented multiple pyoderma gangrenosum lesions on the lower limbs throughout the course of the disease. The patient had been treated with multiple therapies that, in chronological order, included 6-mercaptopurine, cyclosporin at 3-5 mg/kg/d for 5 months, intravenous infliximab at 5 mg/kg every 4 weeks, subcutaneous adalimumab at 40 mg/wk, plasmapheresis every 15 days, tacrolimus oral at 8 mg/d, intravenous vedolizumab at 300 mg every 4 weeks, and subtotal colectomy. Cyclosporin, infliximab, adalimumab, and tacrolimus oral had been administered with the above treatments for the indication of pyoderma gangrenosum and topical treatment was associated with intralesional triamcinolone acetonide, and topical tacrolimus and clobetasol propionate. All previous treatments were associated with prednisone at doses of up to 50 mg/d. At one point in the course of the disease, the patient presented left pretibial pyoderma gangrenosum measuring 11 × 7 cm. The lesion, which had appeared 5 months earlier, was difficult to manage, corticosteroid-dependent (it worsened when prednisone was reduced to below 20 mg/d), and had a considerable impact on quality of life (Fig. 1). At the time, the patient was undergoing treatment with intravenous vedolizumab at a dosage of 300 mg every 4 weeks, prednisone at 50 mg/d, and topical corticosteroids. In light of the refractory nature of the disease and as multiple lines of treatment had been exhausted, it was decided to instate treatment with subcutaneous ustekinumab 90 mg (week 0, 4, 10, and every 8

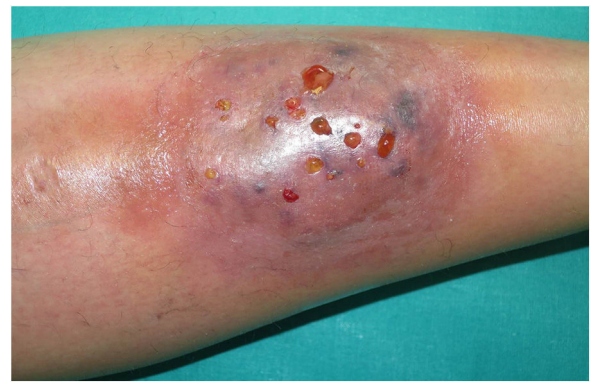

Figure 1 Skin lesion compatible with pyoderma gangrenosum on the lower part of the left leg. Image prior to combined treatment with ustekinumab and cyclosporin.

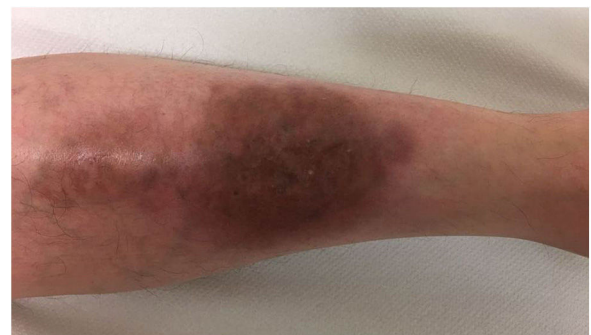

Figure 2 Residual lesion on the left leg after treatment with ustekinumab and cyclosporin for 12 weeks.

weeks thereafter) associated with cyclosporin at a dose of 3 mg/kg/d, with an excellent response of the pyoderma gangrenosum, which resolved completely in 12 weeks, making it possible to reduce the dosage of prednisone to 5 mg/d (Fig. 2). After 10 months of follow-up, the patient has maintained treatment with ustekinumab every 8 weeks with very good results; this has made it possible to withdraw the cyclosporin and reduce the prednisone to 2.5 mg every 2 days.

In 2011, Guenova et al reported the first case of pyoderma gangrenosum successfully treated with ustekinumab.² Those authors suggested that IL-23 is implicated in the pathogenesis of immunologic diseases such as psoriasis and inflammatory bowel disease; they therefore studied the expression of this interleukin in the patient's lesion biopsy and observed overexpression of IL-23 compared to biopsies of healthy skin. Ustekinumab was therefore proposed as a targeted therapy for treatment of the pyoderma gangrenosum.² Since then, 5 more cases have been reported in the literature with good response to ustekinumab at doses ranging from 45-90 mg every 8 weeks to 135 mg every 6 weeks (Table 1).²⁻⁷

[☆] Please cite this article as: Piqueras-García J, Sahuquillo-Torralba AJ, Torres-Navarro I, Botella-Estrada R. Pyoderma gangrenoso asociado a colitis ulcerosa con buena respuesta a ustekinumab Eczema y urticaria en Portugal. 2019;110:776-778.

Table 1 Summary of Cases of Pyoderma Gangrenosum Treated With Ustekinumab Reported in the Literature.

Author	Sex/Age, y	Associated Disease	Previous Treatment	Ustekinumab Dosage	Response
Guenova et al. ² (2011)	Female/37	None	Prednisolone and tacrolimus topical	45 mg/8 weeks Associated with tacrolimus topical	Complete response reached after 14 weeks
Fahmy et al. ³ (2012)	Female/34	Ulcerative colitis	Corticosteroids, azathioprine, infliximab, colectomy, adalimumab, and tacrolimus oral	90 mg/8 weeks	Complete response reached after 10 weeks
Goldminz et al. ⁴ (2012)	Male/37	None	Topical, intralesional, and systemic corticosteroids, cyclosporin, azathioprine, methotrexate, adalimumab, infliximab, and golimumab	90 mg/8 weeks Associated with dapsone 100 mg/d and prednisone	Complete response reached after 22 weeks
Cosgarea et al. ⁵ (2016)	Female/71	Renal cell carcinoma	Prednisone and cyclosporin	Not reported	Complete response reached 12 weeks after reinstatement of ustekinumab following surgery for renal cell carcinoma (no response prior to surgery)
Greb et al. ⁶ (2016)	Male/50	None	Prednisone, cyclosporin, adalimumab, infliximab, and golimumab	90 mg/8 weeks to 135 mg/6 weeks Associated with dapsone 100 mg/d and prednisone	Response reached after 16 weeks following higher dosage of ustekinumab
Benzaquen et al. ⁷ (2017)	Female/56	Psoriasis treated with adalimumab (induced by anti-TNF)	None	45 mg. Interval not specified	Complete response after 3 doses

In conclusion, we present a new case of pyoderma gangrenosum associated with ulcerative colitis, with good response to ustekinumab together with cyclosporin and oral corticosteroids following a lack of response to the 2 previous treatments, tacrolimus oral and anti-TNF (infliximab and adalimumab), administered together. We propose this alternative in difficult-to-manage cases of pyoderma gangrenosum that are refractory to other treatments. Further studies are required to determine the involvement of IL-23 in the pathogenesis of this disease.

Conflicts of Interest

The authors declare that they have no conflicts of interest.

References

1. Quist SR, Kraas L. Treatment options for pyoderma gangrenosum. *J Dtsch Dermatol Ges.* 2017;15:34–40.
2. Guenova E, Teske A, Fehrenbacher B, Hoerber S, Adamczyk A, Schaller M, et al. Interleukin 23 expression in pyoderma gangrenosum and targeted therapy with ustekinumab. *Arch Dermatol.* 2011;147:1203–5.
3. Fahmy M, Ramamoorthy S, Hata T, Sandborn WJ. Ustekinumab for peristomal pyoderma gangrenosum. *Am J Gastroenterol.* 2012;107:794–5.
4. Goldminz AM, Botto NC, Gottlieb AB. Severely recalcitrant pyoderma gangrenosum successfully treated with ustekinumab. *J Am Acad Dermatol.* 2012;67:e237–8.
5. Cosgarea I, Lovric Z, Körber A, Dissemmond J. Successful treatment of refractory pyoderma gangrenosum with ustekinumab only after excision of renal cell carcinoma. *Int Wound J.* 2016;13:1041–2.
6. Greb JE, Gottlieb AB, Goldminz AM. High-dose ustekinumab for the treatment of severe, recalcitrant pyoderma gangrenosum. *Dermatol Ther.* 2016;29:482–3.
7. Benzaquen M, Monnier J, Beaussault Y, Rouby F, Berbis P. Pyoderma gangrenosum arising during treatment of psoriasis with adalimumab: Effectiveness of ustekinumab. *Australas J Dermatol.* 2017;58:e270–1.

J. Piqueras-García,* A.J. Sahuquillo-Torralba,
I. Torres-Navarro, R. Botella-Estrada

*Servicio de Dermatología, Hospital Universitario y
Politécnico La Fe, Valencia, Spain*

*Corresponding author.

E-mail address: jennipg_19@hotmail.com

(J. Piqueras-García).

<https://doi.org/10.1016/j.adengl.2018.03.025>
1578-2190/

© 2019 Elsevier España, S.L.U. and AEDV. Published by Elsevier
España, S.L.U. All rights reserved.

Congenital Absence of Nails and Digital-Type Thumb due to Prenatal Phenytoin Exposure[☆]



His thumbs were thinner than the normal. Rest of his
general and systemic examination was insignificant. Lab-

Ausencia congénita de uñas y pulgar digitalizado debida a la exposición prenatal a fenitoína

To The Editor,

Anonychia i.e. absence of nails constitutes one of the
component of limb anomalies in Fetal hydantoin syn-
drome (FHS), apart from the hypoplastic fingernails and
distal phalanges, a digital-type thumb i.e. long, slender
finger like-thumb, abnormal palmar creases, increased fre-
quency of low arch, digital dermal ridge patterns and
hip dislocation.¹Craniofacial anomalies, ocular defects, and
growth abnormalities are the other systemic manifesta-
tions of the FHS; however isolated simple anonychia i.e.
absence of fingernails and toenails, without other congeni-
tal anomaly and slender, finger-like thumb is an extremely
rare finding of FHS.²

Case Report

A 15-year-old boy, otherwise healthy presented with
absence of nails of both hands' ring fingers and little fin-
gers and both feet's 5th toenails and hypoplastic nails of
the 2nd, 3rd and 4th toes, since birth (Figure 1). He was
born of non-consanguineous marriage. His mother was suf-
fering from epilepsy and was prescribed oral phenytoin
100 mg three times daily since her 20 years of age. Pheny-
toin was continued throughout her pregnancy and drug
levels were not monitored. Along with phenytoin, folic acid
5 mg once daily was prescribed to the patient. Patient's
past and family history was insignificant and his sibling
didn't suffer from any anomalies. He was of normal intel-
ligence. On examination there was also flexion deformities
of the distal interphalangeal joints and slight extension
of his proximal interphalangeal joints of the left middle
and ring finger and right middle finger (Figures 2 and 3).

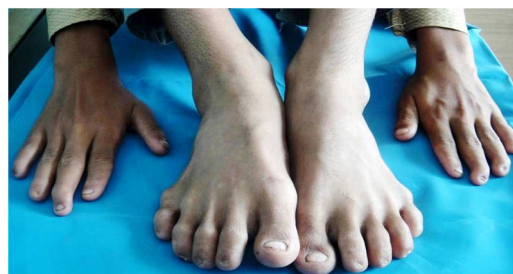

Figure 1 Total absence of nails of 5th toes.

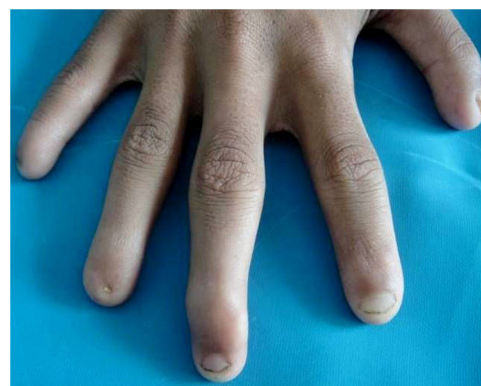


Figure 2 Complete absence of nails of little and ring finger
of the right hand with flexion deformity of the middle finger.

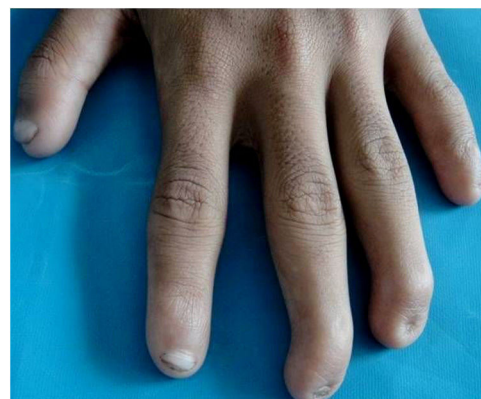

Figure 3 Anonychia of the ring and little finger of the left
hand with flexion deformity of the middle and ring finger.

[☆] Please cite this article as: Pawar MK, Zawar V. Ausencia con-
génita de uñas y pulgar digitalizado debida a la exposición prenatal
a fenitoína. *Eczema y urticaria en Portugal*. 2019;110:778-780.