

## Skin Metastasis of Glioblastoma Multiforme: A Case Report and Literature Review<sup>☆</sup>

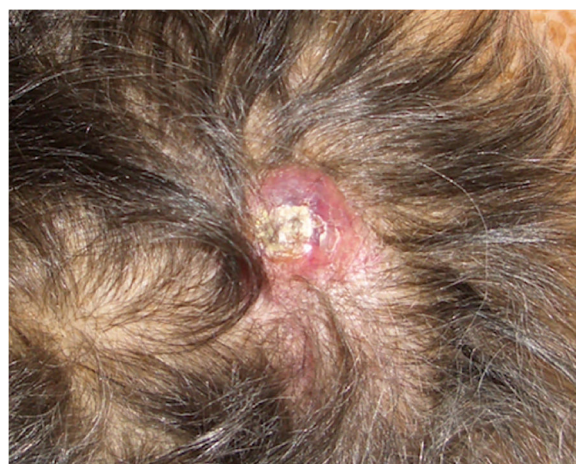

### Metástasis cutánea de glioblastoma multiforme: presentación de un caso y revisión de la literatura

To the Editor:

We present the case of a 75-year-old woman with a history of glioblastoma multiforme (GBM) who had undergone craniectomy and resection 7 months earlier and was participating in a clinical trial of nivolumab versus placebo. The patient had been referred from the oncology to the dermatology department for an erythematous mass (3 × 4 cm) with a crusted and ulcerated surface located in the right parietal region, close to the craniectomy scar (Fig. 1). The patient provided the results of a magnetic resonance imaging (MRI) study performed the previous day in which no continuity solution was evident in the bone. A biopsy was performed on suspicion of skin metastasis of GBM, and revealed marked diffuse dermal infiltrate consisting of mononuclear cells with hyperchromatic nuclei and marked pleomorphism. Immunohistochemistry revealed positive staining for CD10, protein gene product (PGP) 9.5, and glial fibrillary acid protein (GFAP), indicating a probable neural origin (Fig. 2). Staining for S100, HMB45, cytokeratin 20, and CD99 was negative. One month later the patient presented to the oncology department with absence seizures. Imaging tests revealed subacute hydrocephalus secondary to the initial surgical intervention. There was no possibility of placing a ventriculoperitoneal shunt. Interestingly, no changes in either the lesion or the perilesional edema were observed relative to the initial MRI findings. Given the patient's poor progression, it was decided to administer symptomatic palliative treatment.

Although GBM is the most common malignant brain tumor, extracranial metastasis is uncommon, and has been reported in only 2.7% of 148 patients with a histological diagnosis of glioma who were followed up for 5 years.<sup>1</sup> The most common sites of metastasis are the lung, pleura, and lymph nodes; skin metastasis is more rare.<sup>2</sup> In the current literature there are 7 reports of skin metastasis of cerebral glioma grades III to IV (Table 1). Ours is the first reported case of skin metastasis of GBM without recurrence of intracranial disease,<sup>3</sup> which is usually observed in patients with a history of invasive surgical procedures, suggesting a fundamental role of iatrogenic seeding. However, in 10% of patients extracranial metastasis occurs in the absence of previous surgical interventions<sup>4</sup> or at a site



**Figure 1** Erythematous nodule with a superficial crust on the scalp.

distant from the intervention,<sup>5</sup> suggesting the existence of other routes of dissemination (e.g. vascular, lymphatic, perineural, direct extension). Some studies suggest that mutation of the epidermal growth factor receptor (EGFR) gene is a predisposing factor for extracranial GBM growth,<sup>6</sup> although our patient tested negative for *EGFR* mutations. Other theories propose that GBM promotes defective angiogenesis, giving rise to hypoxic areas in the blood-brain barrier, which is consequently disrupted.<sup>7</sup> Another possibility is that this entity is underdiagnosed; the short survival time of these patients may be insufficient to allow the development of disseminated disease.<sup>8</sup> Prophylactic irradiation immediately after surgery has also been proposed as a means of preventing metastasis secondary to iatrogenic tumor seeding.<sup>9</sup>

Because this entity is particularly rare there are insufficient data to establish a definitive immunohistochemical staining profile. The pattern of GFAP staining, which is generally very intense in primary tumors, can vary in skin metastases, ranging from intense diffuse or focal staining to very fine staining of the cytoplasmic processes of neoplastic cells, as observed in our patient. There are also GBM subtypes (e.g. small-cell GBM) that may be negative for GFAP staining.<sup>10</sup> Thus, while immunohistochemistry can help identify the cell type from which the tumor is derived, it is not diagnostically definitive. A clinical-pathological correlation must be established, taking into account the patient's medical history and ruling out other much more common entities.

### Conflicts of Interest

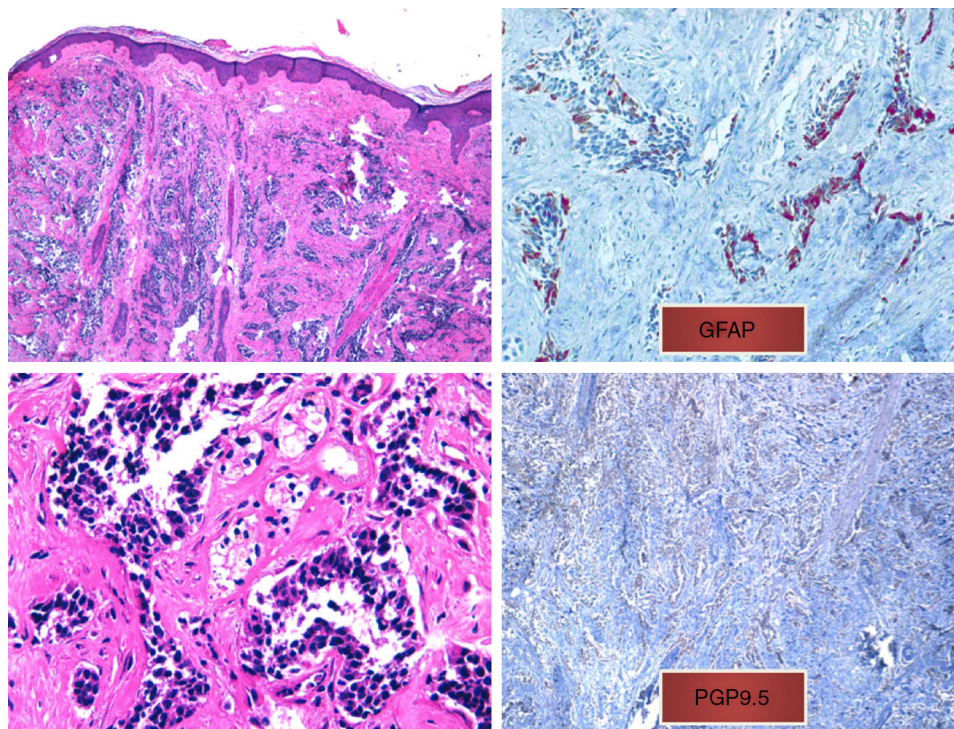
The authors declare that they have no conflicts of interest.

<sup>☆</sup> Please cite this article as: Magdaleno-Tapia J, Valenzuela-Oñate C, Pérez-Pastor G, Alegre de Miquel V. Metástasis cutánea de glioblastoma multiforme: presentación de un caso y revisión de la literatura *Eczema y urticaria en Portugal*. 2019;110:780–783.

**Table 1** Skin Metastasis of High-Grade Glial Tumors Reported in the Literature.

Study	Sex	Age	Primary Tumor	Treatment	Site of Skin Metastasis	Metastasis Time	Concomitant Intracranial Recurrence	Immunohistochemistry	Prognosis
Jain et al., <sup>3</sup> 2005	Male	49	GBM	S + RT	Craniotomy scar	8 mo (4 mo after second surgery)	Yes	GFAP <sup>+</sup> , vimentin <sup>+</sup> (more intense than intracranial recurrence)	4 mo after recurrence
Mentrikoski et al., <sup>9</sup> 2008	Female	58	GBM	S + RT + TZM	Craniotomy scar	16 mo (10 mo after second surgery)		S100 <sup>+</sup> , GFAP <sup>+</sup> (focal), vimentin <sup>+</sup> , NF <sup>-</sup>	
	Male	41	AOD	S + RT (intratumoral implants)	Craniotomy scar	2 mo	No	GFAP <sup>+</sup> , S100 <sup>+</sup> , EMA <sup>-</sup>	
Amitendu et al., <sup>1</sup> 2012	Male	27	Grade II astrocytoma (PXA)	S + RT	Craniotomy scar	12 mo	No	Compatible with PXA	Intracranial recurrence at 3 mo with diagnosis of AOD
Forsyth et al., <sup>4</sup> 2015	Female	59	GBM (EGFR <sup>+</sup> )	S + RT + BVZ	Forehead	6 mo	Yes	MGMT <sup>+</sup> , IDH1 <sup>-</sup>	3.5 mo after recurrence
Ginat et al., <sup>8</sup> 2013	Male	62	GBM (EGFR <sup>+</sup> )	Partial S + RT + TZM	Craniotomy scar	10 mo	Yes	GFAP <sup>+</sup>	14.5 mo after recurrence
Miliaras et al., <sup>5</sup> 2009	Male	63	GBM	S + RT + TZM	Ipsilateral scapular region	7 mo	Yes		3 mo after recurrence

Abbreviations: AOD, anaplastic oligodendroglioma; BVZ, bevacizumab; EGFR, epidermal growth factor receptor; EMA, epithelial membrane antigen; GBM, glioblastoma multiforme; GFAP, glial fibrillary acid protein; IDH1, isocitrate dehydrogenase 1; IHC, immunohistochemistry; MGMT, O6-methylguanine-DNA methyltransferase; PXA, pleomorphic xanthoastrocytoma; RT, radiation therapy; S, surgery; TZM, temozolamide.



**Figure 2** A, Diffuse infiltrate in the papillary and reticular dermis of tumor cells, sparing the epidermis (hematoxylin-eosin, original magnification  $\times 10$ ). B, Tumor cells with hyperchromatic nuclei and marked pleomorphism (hematoxylin-eosin, original magnification  $\times 40$ ). C, Positive immunohistochemistry (glial fibrillary acid protein, original magnification  $\times 40$ ). D, Positive immunohistochemistry (protein gene product 9.5, original magnification  $\times 20$ ).

## Acknowledgments

The authors thank the pathological anatomy department of the Hospital General de Valencia, especially Dr. Ana Pérez for her excellent assistance with immunohistochemistry techniques that could not be performed in the dermatology department. Thanks also to our laboratory technician Sandra Mínguez for her help and dedication with each and every case.

## References

1. Amitendu S, Mak SKD, Ling JM, Ng WH. A single institution experience of the incidence of extracranial metastasis in glioma. *J Clin Neurosci*. 2012;19:1511–5.
2. Lewis GD, Rivera AL, Tremont-Lukats IW, Ballester-Fuentes LY, Zhang YJ, Teh BS. GBM skin metastasis: a case report and review of the literature. *CNS Oncol*. 2017;6:203–9.
3. Jain N, Mirakhur M, Flynn P, Choudhari KA. Cutaneous metastasis from glioblastoma. *Br J Neurosurg*. 2005;19:65–8.
4. Forsyth TM, Bi WL, Abedalthagafi M, Dunn IF, Chiocca EA. Extracranial growth of glioblastoma multiforme. *J Clin Neurosci*. 2015;22:1521–3.
5. Miliaras G, Tsitsopoulos PP, Markoula S, Kyritsis A, Polyzoidis KS, Malamou-Mitsi V. Multifocal glioblastoma with remote cutaneous metastasis: a case report and review of the literature. *Cent Eur Neurosurg*. 2009;70:39–42.
6. Müller C, Holtschmidt J, Auer M, Heitzer E, Lamszus K, Schulte A, et al. Hematogenous dissemination of glioblastoma multiforme. *Sci Transl Med*. 2014;6, 247ra101.
7. Rong Y, Durden DL, van Meir EG, Brat DJ. ‘Pseudopalisading’ necrosis in glioblastoma: a familiar morphologic feature that links vascular pathology, hypoxia, and angiogenesis. *J Neuro-pathol Exp Neurol*. 2006;65:529–39.
8. Ginat DT, Kelly HR, Schaefer PW, Davidson CJ, Curry W. Recurrent scalp metastasis from glioblastoma following resection. *Clin Neurol Neurosurg*. 2013;115:461–3.
9. Mentrikoski M, Johnson MD, Korones DN, Scott GA. Glioblastoma multiforme in skin: a report of 2 cases and review of the literature. *Am J Dermatopathol*. 2008;30:381–4.
10. Deng S, Liu L, Wang D, Tong D, Zhao G. Small cell glioblastoma of the sella turcica region: a case report and review of the literature. *World Neurosurg*. 2018;110:174–9.

J. Magdaleno-Tapial,\* C. Valenzuela-Oñate,  
G. Pérez-Pastor, V. Alegre de Miquel

*Consorcio Hospital General Universitario de Valencia,  
Valencia, España*

\*Corresponding author.

E-mail address: [jormagta@gmail.com](mailto:jormagta@gmail.com)  
(J. Magdaleno-Tapial).

<https://doi.org/10.1016/j.adengl.2018.05.037>  
1578-2190/

© 2019 Elsevier España, S.L.U. and AEDV. Published by Elsevier  
España, S.L.U. All rights reserved.