

J. Piqueras-García,* A.J. Sahuquillo-Torrallba,
I. Torres-Navarro, R. Botella-Estrada

*Servicio de Dermatología, Hospital Universitario y
Politécnico La Fe, Valencia, Spain*

*Corresponding author.

E-mail address: jennipg_19@hotmail.com

(J. Piqueras-García).

<https://doi.org/10.1016/j.adengl.2018.03.025>
1578-2190/

© 2019 Elsevier España, S.L.U. and AEDV. Published by Elsevier
España, S.L.U. All rights reserved.

Congenital Absence of Nails and Digital-Type Thumb due to Prenatal Phenytoin Exposure[☆]



His thumbs were thinner than the normal. Rest of his
general and systemic examination was insignificant. Lab-

Ausencia congénita de uñas y pulgar digitalizado debida a la exposición prenatal a fenitoína

To The Editor,

Anonychia i.e. absence of nails constitutes one of the
component of limb anomalies in Fetal hydantoin syn-
drome (FHS), apart from the hypoplastic fingernails and
distal phalanges, a digital-type thumb i.e. long, slender
finger like-thumb, abnormal palmar creases, increased fre-
quency of low arch, digital dermal ridge patterns and
hip dislocation.¹Craniofacial anomalies, ocular defects, and
growth abnormalities are the other systemic manifesta-
tions of the FHS; however isolated simple anonychia i.e.
absence of fingernails and toenails, without other congeni-
tal anomaly and slender, finger-like thumb is an extremely
rare finding of FHS.²

Case Report

A 15-year-old boy, otherwise healthy presented with
absence of nails of both hands' ring fingers and little fin-
gers and both feet's 5th toenails and hypoplastic nails of
the 2nd, 3rd and 4th toes, since birth (Figure 1). He was
born of non-consanguineous marriage. His mother was suf-
fering from epilepsy and was prescribed oral phenytoin
100 mg three times daily since her 20 years of age. Pheny-
toin was continued throughout her pregnancy and drug
levels were not monitored. Along with phenytoin, folic acid
5 mg once daily was prescribed to the patient. Patient's
past and family history was insignificant and his sibling
didn't suffer from any anomalies. He was of normal intel-
ligence. On examination there was also flexion deformities
of the distal interphalangeal joints and slight extension
of his proximal interphalangeal joints of the left middle
and ring finger and right middle finger (Figures 2 and 3).

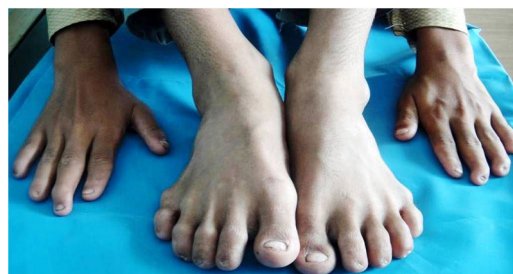

Figure 1 Total absence of nails of 5th toes.

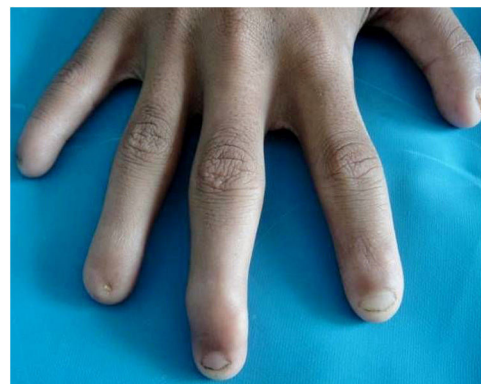


Figure 2 Complete absence of nails of little and ring finger
of the right hand with flexion deformity of the middle finger.

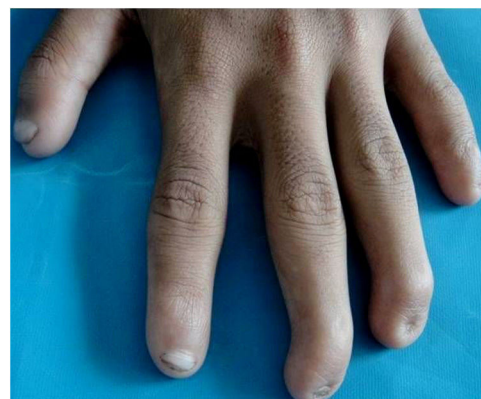

Figure 3 Anonychia of the ring and little finger of the left
hand with flexion deformity of the middle and ring finger.

[☆] Please cite this article as: Pawar MK, Zawar V. Ausencia con-
génita de uñas y pulgar digitalizado debida a la exposición prenatal
a fenitoína. *Eczema y urticaria en Portugal*. 2019;110:778-780.

oratory investigations including metabolic profile, Vitamin D and parathyroid hormone levels were within normal limits. Radiographic survey of the hands and feet were normal. Patient was counseled regarding benign nature of anonychia.

Discussion

Meadow initially described a possible link between congenital abnormalities and maternal use of anticonvulsive drug in 1968 and it was expanded by Hanson and Smith in 1975 in the offspring of women taking phenytoin and they proposed these specific phenytoin related anomalies as FHS. FHS equally affects males and females. The incidence of complete classic FHS is around 5–10%, whereas one third (33%) of patients manifest an incomplete clinical syndrome. Women with mutations in the methylenetetrahydrofolate reductase (MTHFR) gene are at major risk of having an infant with FHS.^{1,2}

Congenital isolated, non-syndromic anonychia results from mutation in the gene coding for R-spondin 4, which play a role in the Wnt signalling pathway. Syndromic form of anonychia presents with ectodermal dysplasia, skeletal or neurological malformations such as microcephaly, brachydactyly (Cooks syndrome), abnormal dentition, lymphedema, gingival fibromatosis (Zimmermann–Laband syndrome), deafness, Iso–Kikuchi syndrome, Nail-patella syndrome and mental retardation (DOOR syndrome - deafness, onycho-osteodystrophy, mental retardation).³ Coffin-Siris syndrome constitutes many features similar to FHS, such as hypoplastic fingernails and toenails (especially of the fifth finger); but severe mental retardation, joint laxity and dislocation of the radial head is present in Coffin-Siris syndrome.¹ Acquired causes of anonychia include trauma, pemphigus, lichen planus, Stevens–Johnson syndrome, epidermolysis bullosa, teratogens (drugs and alcohol), amniotic bands and viral infection during pregnancy.⁴ Anonychia secondary to teratogenic drugs commonly occurs with phenytoin and warfarin and has also been reported with valproate, carbamazepine, morphine and trimethadone.⁴ Nail development begins as flat rectangular surface of the future nail bed on the dorsal tips demarcated by folds, visible at 8–10 weeks of gestational age and is completed by the fifth month of gestational age; hence intake of teratogens by mother during the first and second trimester of pregnancy adversely affect nail development.² The exact mechanism of nail malformation is unknown but it is speculated that intermediate metabolites of phenytoin i.e. epoxides are responsible for its teratogenicity. Epoxides bind to embryonic or fetal nucleic acids, proteins and lipids and disrupt the normal development of the fetus at critical periods of embryogenesis. Also, co-oxidation of the

phenytoin to free radical intermediates by prostaglandin synthetase may result in oxidant stress, which further initiate lipid peroxidation reactions and/or bind covalently to essential nucleic acids causing fetal dysmorphogenesis. Genetic make-up of the individual information of these intermediate metabolites and free radicals and its clearance and repair mechanisms may explain different susceptibility across individuals.^{5,6}

Treatment of the hypoplastic nails is rarely indicated as their appearance may improve with time. Nail anomalies in a newborn may be a marker of increased maternal serum phenytoin concentration and it may herald more severe congenital abnormalities, especially mental retardation. As the teratogenic effect of the phenytoin is dose dependent, it is prudent to monitor drug levels regularly during the pregnancy.

Conflicts of Interest

The authors declare that they have no conflicts of interest.

References

1. Silver L. Hand abnormalities in the fetal hydantoin syndrome. *J Hand Surg Am.* 1981;6:262–5.
2. Babu S, Agarwal N. Anonychia due to prenatal phenytoin exposure. *J Assoc Physicians India.* 2012;60:64.
3. Ramassamy S, Gibikote S, George RE. Anonychia with absent phalanges and brachydactyly: A report of two unrelated cases. *Indian J Dermatol Venereol Leprol.* 2016;82:693–5.
4. Eadie MJ. Antiepileptic drugs as human teratogens. *Expert Opin Drug Saf.* 2008;7:195–9.
5. Buehler BA, Delimont D, van Waes M, Finnell RH. Prenatal prediction of risk of the fetal hydantoin syndrome. *N Engl J Med.* 1990;322:1567–72.
6. [consultado 15 Ene 2018] Disponible en: <https://rare-diseases.org/rare-diseases/fetal-hydantoin-syndrome/>.
7. Hill DS, Włodarczyk BJ, Palacios AM, Finnell RH. Teratogenic effects of antiepileptic drugs. *Expert Rev Neurother.* 2010;10:943–59.

M. Karbhari Pawar,* V. Zavar

Departamento de Dermatología, The Skin Clinic and Cosmetic Centre, Nashik, India

* Corresponding author.

E-mail address: manojpawar624@yahoo.com (M.K. Pawar).

<https://doi.org/10.1016/j.adengl.2019.05.010>
1578-2190/

© 2019 Published by Elsevier España, S.L.U. on behalf of Elsevier España, S.L.U. and AEDV.