

5. Cho KE, Son EJ, Kim JA, Youk JH, Kim EK, Kwak JY, et al. Clear cell hidradenoma of the axilla: A case report with literature review. *Korean J Radiol.* 2010;11:490–2.
6. Horie K, Ito K. Ultrasonographic diagnosis of nodular hidradenoma. *J Dermatol.* 2016;43:449–50.
7. Takasaka M, Saeki H, Ito K, Matsuo K, Ishiji T, Nakagawa H. Skin ultrasound examination proves useful in diagnosing two cases of solid cystic hidradenoma. *Int J Dermatol.* 2014;53:e146–7.
8. Pérez-López I, Garrido-Colmenero C, Blanco-Morente G, Aneiros-Fernandez J, Arias-Santiago S. Utilidad de la ecografía cutánea en el diagnóstico diferencial de las lesiones azules, hidrocistoma. *Dermatol Online J.* 2015;16:21.
9. Balaban M, Idilman IS, Unal O, Dumlu EG, Yazgan A, Ipek A. Sonographic and sonoelastographic findings of a rarely seen soft tissue tumor: Eccrine spiradenoma. *J Med Ultrasonics.* 2015;42:587–90.
10. Martínez-Morán C, Khedaoui R, Echeverría-García B, Borbujo J. Imagen ecográfica del hidradenoma poroide. *Actas Dermosifiliogr.* 2016;107:349–51.
11. Ruiz-Villaverde R, Arias-Santiago S, Repiso-Jimenez JB. Ecografía aplicada al manejo de tumores cutáneos benignos. *Actas Dermosifiliogr.* 2015;106 Supl 1:29–40.

I. Vázquez-Osorio,^{a,*} P. Gonzalvo-Rodríguez,^b
E. Rodríguez-Díaz^a

^a *Servicio de Dermatología, Hospital Universitario de Cabueñes, Gijón, Asturias, Spain*

^b *Servicio de Anatomía Patológica, Hospital Universitario de Cabueñes, Gijón, Asturias, Spain*

* Corresponding author.

E-mail address: rogivaos@gmail.com (I. Vázquez-Osorio).
1578-2190/

© 2017 Elsevier España, S.L.U. and AEDV. All rights reserved.

Atrophyng Pityriasis Versicolor[☆]



Pitiriasis versicolor atrófica

To the Editor:

Pityriasis versicolor (PV) is a common superficial fungal infection caused by yeasts of the genus *Malassezia*. In clinical terms, it generally presents on the trunk as round or oval macules that vary in color from hypopigmentation to blackish.¹ Its symptoms are easily recognizable, with several atypical forms reported, including the variant with atrophic lesions.²

A 28-year-old man with plaque psoriasis treated with topical corticosteroids consulted for the appearance of cutaneous abnormalities that he perceived as being different from his psoriasis lesions. The physical examination revealed several circular areas on the back and the extensor surface of the upper right limb. The areas measured 0.5 cm to 4 cm and were depressed and atrophic in appearance (Fig. 1). Some were hypopigmented, whereas others were slightly pink; some had mild desquamation, whereas others were similar to typical psoriasis lesions (Fig. 2). The Wood lamp examination did not reveal fluorescence. The skin biopsy revealed laminated hyperkeratosis in the epidermis, with flattening of the rete ridges and an edematous appearance with vascular dilations in the dermis that was more evident in the papillary dermis. The vessels were surrounded by a discreet lymphocytic infiltrate. Periodic acid–Schiff staining revealed abundant short, septate hyphae and spores between the layers of keratin. Orcein staining revealed diminished elastic fibers in the papillary dermis and fragmentation thereof in the superficial reticular dermis (Fig. 3).

Direct examination of the lesions revealed the presence of yeasts and pseudomycelium.

The patient was prescribed itraconazole 200 mg/d for 7 days combined with topical flutrimazole at night for 1 month. The topical corticosteroid was replaced by

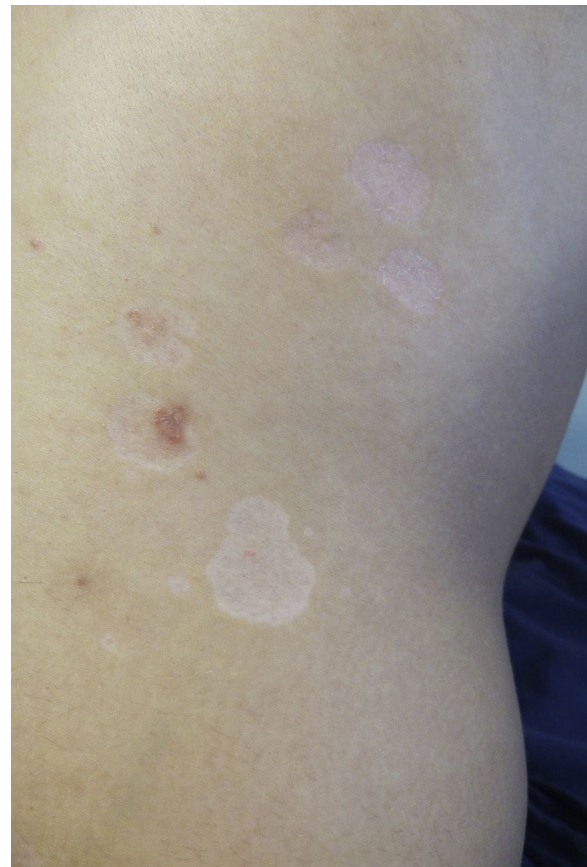

Figure 1 Slightly depressed hypopigmented and pink plaques of various sizes on the patient's back. Mild desquamation can be observed on some.

[☆] Please cite this article as: Allegue F, Fachal C, González-Vilas D, Zulaica A. Pitiriasis versicolor atrófica. *Actas Dermosifiliogr.* 2018;109:455–457.

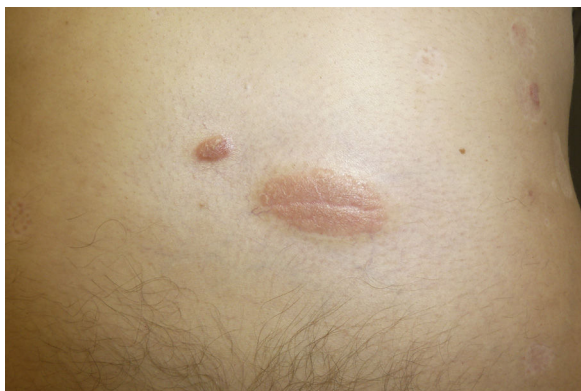

Figure 2 Psoriatic plaques in the center of depressed areas.

calcitriol ointment for treatment of his psoriasis. Although improvement was slow, the patient had fully recovered at 6 months, with no new lesions after 1 year of follow-up.

Atrophying or atrophic PV is an uncommon presentation of this condition.²⁻¹⁰ It manifests clinically as depressed erythematous or hypopigmented areas with discreet desquamation located mainly on the trunk, generally the back and shoulders. The lesions are usually numerous, tend to group together, and measure a few millimeters to several centimeters, although they are generally uniform on the same patient. The diagnostic suspicion can be confirmed by direct examination, which reveals accumulations of yeasts and short hyphae; if these occur together, they have the typical “spaghetti and meatballs” appearance. Skin biopsy may help in atypical cases such as the present one. The most characteristic and differentiating histopathological findings of the atrophic variant include

an epidermis with flattened rete ridges and, especially, reduction and fragmentation of the dermal elastic fibers.^{5,9} The differential diagnosis includes processes that induce skin atrophy, that is, anetoderma, morphea/atrophoderma, mycosis fungoides, sarcoidosis, and corticosteroid-induced atrophy.^{6,9,10}

The mechanism by which species of *Malassezia* can induce atrophy in the skin remains unclear. Since many of the patients reported were being treated with topical corticosteroids²⁻⁷ or systemic corticosteroids,⁸ atrophy was associated with the atrophogenic effect of the drugs.³⁻⁷ The fungal infection is thought to alter the epidermal barrier, thus increasing absorption of corticosteroids in the PV lesions and inducing local cutaneous atrophy. However, in corticosteroid-induced atrophy, in addition to epidermal atrophy and vasodilation, we can see atrophy of skin adnexa and reduction and fragmentation of dermal collagen, whereas in atrophic PV, we do not see alteration of collagen but alteration of the elastic fibers.^{5,6,9,10} We did not find collagen abnormalities in the case we report, suggesting the possibility of another pathogenic mechanism, given that cases not associated with corticosteroids have been reported.^{9,10} Crowson and Magro⁹ proposed that this form of PV appeared through a type 1 helper T-cell immune response to *Malassezia* antigens, in which histiocytes recruited and activated by interferon- γ would generate the elastases responsible for the dermal elastolysis observed. Flattening of the rete ridges, on the other hand, is mediated by cytokines, such as tumor necrosis factor α and interleukin 1 β , which can inhibit the nuclear factor κ B pathway of keratinocytes to induce apoptosis and hinder proliferation thereof.⁹ In parallel, the reduced thickness and loss of hair in areas of PV has also been related to this mechanism.¹¹ Furthermore, a type 2 helper T cell response, which could

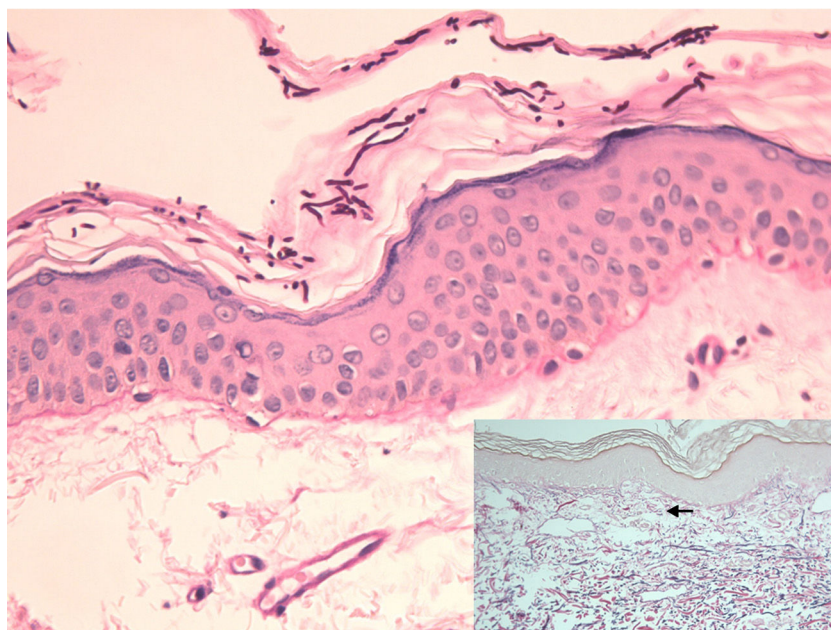


Figure 3 Epidermis with abundant hyphae and spores in the stratum corneum and flattening of the rete ridges (periodic acid-Schiff, original magnification $\times 200$). The inset shows diminished fine elastic fibers in the papillary dermis (arrow) and fragmented elastic fibers in the superficial reticular dermis, as well as vascular ectasia (orcein stain, original magnification $\times 100$).

favor fungal overgrowth, has been implicated, together with the type 1 response, in the pathogenesis of atrophic PV.¹⁰

Treatment of this variant of PV is standard,¹⁰ although it has been suggested that longer regimens may be necessary and even that oral and topical approaches should be combined.⁵ Obviously, corticosteroids should be withdrawn.⁵ As a rule, the atrophy disappears; therefore, compared with other atrophying diseases, atrophying PV has a good prognosis.

Conflicts of Interest

The authors declare that they have no conflicts of interest.

References

- Crespo-Erchiga V, Gómez-Moyano E, Crespo M. La pitiriasis versicolor y las levaduras del género *Malassezia*. *Actas Dermosifiliogr*. 2008;99:764–71.
- Patalano A, Fiammenghi E, Chianese C, Calabrò G. Pitfalls of easy diagnosis. *Journal of Plastic Dermatology*. 2013;9:149–52.
- De Graciansky P, Mery F. Atrophie sur pitiriasis versicolor apres corticothérapie locale prolongée. *Bull Soc Fr Dermatol Syphiligr*. 1971;78:295.
- Vera Casaño A, Trasobares Marugan L, del Valle Martín M, Hernánz Hermosa JM, del Palacio Hernánz A. Pitiriasis versicolor atrófica inducida por corticoides tópicos fluorados. *Actas Dermosifiliogr*. 1989;80:101–3.
- Yang YS, Shin MK, Haw CR. Atrophying pitiriasis versicolor: is this a new variant of pityriasis versicolor? *Ann Dermatol*. 2010;22:456–9.
- Moon SY, Lee WJ, Lee SJ, Kim DW, Jang JH. Pityriasis versicolor atrophicans: Is it true atrophy or pseudoatrophy? *J Cutan Pathol*. 2016;43:187–9.
- Tatnall FM, Rycroft RJ. Pityriasis versicolor with cutaneous atrophy induced by topical steroid application. *Clin Exp Dermatol*. 1985;10:258–61.
- Marinello E, Piaserico S, Alaibac M. Atrophic pityriasis versicolor occurring in a patient with Sjögren's syndrome. *BMJ Case Rep*. 2017, <http://dx.doi.org/10.1136/bcr-2016-218108>, pii: bcr2016218108.
- Crowson AN, Magro CM. Atrophying tinea versicolor: A clinical and histological study of 12 patients. *Int J Dermatol*. 2003;42:928–32.
- Levy JM, Magro C. Atrophying pityriasis versicolor as an idiosyncratic T cell-mediated response to *Malassezia*: A case series. *J Am Acad Dermatol*. 2017;76:730–5.
- Mostafa WZ, Assaf MI, Ameen IA, El Safoury OS, Al Suhl AS. Hair loss in pityriasis versicolor lesions: A descriptive clinicopathological study. *J Am Acad Dermatol*. 2013;69:e19–23.

F. Allegue,^{a,*} C. Fachal,^b D. González-Vilas,^a A. Zulaica^a

^a Servicio de Dermatología, Hospital do Meixoeiro, Vigo, Pontevedra, Spain

^b Servicio de Anatomía Patológica. Hospital Álvaro Cunqueiro, EOXI, Vigo, Pontevedra, Spain

*Corresponding author.

E-mail address: fallegue@mundo-r.com (F. Allegue).

1578-2190/

© 2017 Elsevier España, S.L.U. and AEDV. All rights reserved.

Human Papilloma Virus and the Risk of Squamous Cell Carcinoma Arising in Hidradenitis Suppurativa[☆]



Virus del papiloma humano y riesgo de desarrollo de carcinoma escamocelular en la hidradenitis supurativa

To the Editor:

We report the case of a 51-year-old man who was referred to the dermatology department with a painful, suppurative nodule in his left groin that had appeared 1 year previously and was refractory to various antibiotic regimens prescribed by his primary care physician. The patient had a personal history of type 2 diabetes mellitus and was a smoker. Physical examination revealed an erythematous subcutaneous

lesion with areas of suppuration in the lower left groin. On palpation, the lesion extended to the perineal region (Fig. 1). The examination also revealed 3 lesions that were clinically compatible with condylomata acuminata in the perianal area. He was diagnosed clinically for hidradenitis suppurativa (HS). Ultrasonography with an 18-MHz linear probe revealed the presence of a fistulous tract, with areas of fluid collection, together with intense vascularization on Doppler mode (Fig. 2). Given the location and depth of the lesion, the patient was sent to the clinic of the surgery department for complete removal of the lesion. Histopathology showed changes that were compatible with HS and well-differentiated squamous cell carcinoma (SCC) over the fistulous tract, which was located close to the deep resection margin. No vascular invasion or perineural infiltration was observed (Fig. 3 A and B). Extension of the surgical margins revealed no evidence of residual tumor, although foci suggestive of viral infection were observed (Fig. 3C). Immunohistochemical staining with p16 was intensely positive (Fig. 3D). Polymerase chain reaction and genotyping based on in situ hybridization with a microarray of paraffin-embedded tissue were performed to investigate the presence of human papillomavirus (HPV). The result was positive for genotype 6 (considered low risk); the same finding was recorded for the perianal condylomata acuminata. Laboratory analysis yielded negative results

[☆] Please cite this article as: Segura Palacios JM, García Montero P, Fúnez Liébana R, Repiso Jiménez JB. Human Papilloma Virus and the Risk of Squamous Cell Carcinoma Arising in Hidradenitis Suppurativa. *Actas Dermosifiliogr*. 2018;109:457–459.